

Angiokeratomas in the Intensive Care Unit

Ruth L. Wintz, Joseph Varon, Raul G. Mendez Flores, Stephanie C. Fuentes Rojas

Case presentation

A 35-year-old Latin-American gentleman male with a history of Fabry's disease presented for continuation of recombinant ceramide trihexosidase infusion therapy. Because of a prior allergic reaction, the patient was admitted to the intensive care unit during his infusion. He was first diagnosed in 2000, by genetic testing due to a strong family history of the disease and had been receiving infusions every two weeks since 2007. Alpha-galactosidase A level was 0.001%. He reported a history of anhidrosis, blurry vision, fatigue, headache, acroparesthesia, vertigo and diffuse angiokeratomas. These angiokeratomas (**Figures 1 and 2**), had a "bathing-trunk" distribution, but were also present in the inner labial mucosa as well as palms of the hands. Urinalysis showed microscopic

hematuria without proteinuria. Renal function tests included a creatinine level of 0.7 mg/dL and a creatinine clearance of 124 mL/min/1.73 m². Cardiac evaluation, including electrocardiography and echocardiogram were within normal limits.

Fabry's disease has X-linked inheritance on chromosome q22.1 with 504 different known mutations. (1) It has a worldwide prevalence of approximately 1 in 40,000 to 1 in 117,000 live births for the classic form of the disease. (2) Women can also be affected with variable presentation due to lyonization. Manifestations include cardiac, renal, neurologic, ophthalmic, gastrointestinal and dermatologic involvement. With continued enzyme therapy this patient will hopefully continue without major end organ damage, although he requires carbamazepine to treat his neuropathic pain.

Key words: Fabry's disease, angiokeratomas, intensive care, mucosas.

From Baylor College of Medicine, Houston, Texas, USA (Ruth L. Wintz), University General Hospital, The University of Texas Health Science Center at Houston, Houston, Texas, USA (Joseph Varon), Universidad Autonoma de Chihuahua, Mexico (Raul G. Mendez Flores), and *University of Texas Medical Branch* at Galveston, Texas, USA (Stephanie C. Fuentes Rojas).

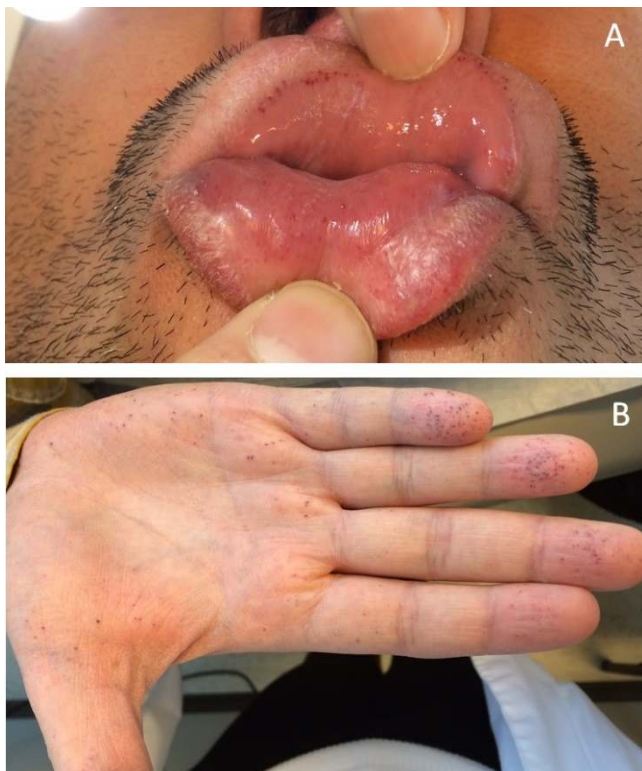
Address for correspondence:

Joseph Varon, MD, FACP, FCCP, FCCM, FRSM
2219 Dorrington Street
Houston, Texas 77030, USA
Tel: +1-713-669-1670
Fax: +1713-669-1671
Email: Joseph.Varon@uth.tmc.edu

Figure 1. Fabry's disease characteristic angiokeratomas with a "bathing-trunk" distribution on (A) lower abdomen and (B) anterior thigh

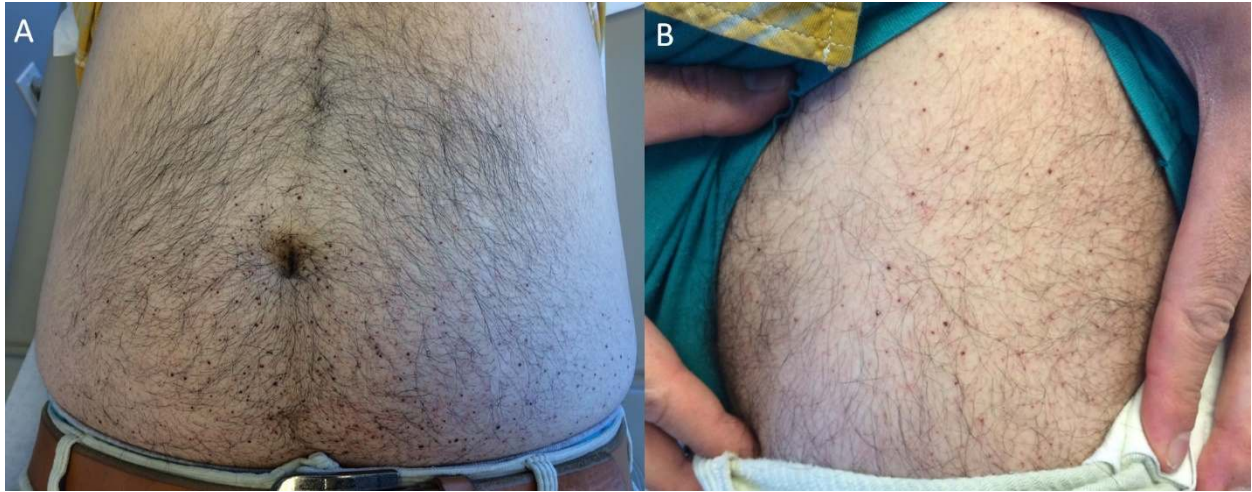

Figure 2. Angiokeratomas in the (A) inner labial mucosa and (B) palms of the hands



References

1. Saito S, Ohno K, Sakuraba H. Fabry-database.org: database of the clinical phenotypes, genotypes and mutant alpha-galactosidase A structures in Fabry disease. *J Hum Genet* 2011;56:467-8.
2. Mehta A, Beck M, Eyskens F, Feliciani C, Kantola I, Ramaswami U, et al. Fabry disease: A review of current management strategies. *QJM* 2010;103:641-59.