

Venomous Snakebites in Two Children

Heda Melinda D. Nataprawira, Enny Harliany Alwi, Lesmana Syahrir, Tubagus Ferdi Fadilah, Tri Wahyu Murni

Abstract

Venomous snakebites, although uncommon, are potentially fatal. Venomous snakes can be grouped as having hemotoxic and neurotoxic venom. Children with venomous snakebites present with signs and symptoms ranging from fang bite marks, with or without swelling and local pain, to severe condition such as coagulopathy, renal failure and shock. We reported two pediatric cases of snakebites admitted at the same day to Pediatric Emergency Department Dr. Hasan Sadikin Hospital from two different areas in Bandung. Both patients had similar clinical signs and symptoms consisted of fang bite marks, local pain, tingling, swelling beyond the area

adjacent to proximal lesion. Both patients were bitten by venomous snakes and thus were treated with antivenin sera immediately. Identification of the snake from the first case could be done straight away because the victim could recognize the snake from the pictures that were shown to him that we assumed came from subfamily of *Elapidae*. Patient from the second case could not identify the type of snake. Hospitalization for at least 24-48 hours is required to monitor victims of venomous snakebites for signs and symptoms of neurologic or hematologic disorder. Both patients were discharged from the hospital in good condition after 48 hours of monitoring.

Key words: Venomous snakebites, antivenin sera.

Introduction

Venomous snakebites, although uncommon emergency, are potentially fatal. Venomous snakebites can be manifested as having hemotoxic or neurotoxic venom depend on snake group. (1-3) Children with venomous snakebites present

with signs and symptoms ranging from fang bite marks, with or without swelling and local pain, to severe condition such as coagulopathy, renal failure and shock. The venomous snakebites' patients should undergo a comprehensive work-up to look for possible hematologic, neurologic, renal, and cardiovascular abnormalities. Although there is no universal grading system for snakebites, a 0 through IV scale is clinically useful as a guide for antivenin sera administration. (1,4) Antivenin sera administration should be given immediately within first four hour until as late as 24 hours. (1) We reported two pediatric cases of snakebites admitted at the same day to Pediatric Emergency Department Dr. Hasan Sadikin Hospital from two different areas in Bandung.

From Department of Child Health, Faculty of Medicine, Padjadjaran University-Dr. Hasan Sadikin Hospital, Bandung, Indonesia (Heda Melinda D. Nataprawira, Enny Harliany Alwi, Lesmana Syahrir, and Tubagus Ferdi Fadilah) and Emergency Department, Dr. Hasan Sadikin Hospital, Bandung, Indonesia (Tri Wahyu Murni).

Address for correspondence:

Dr. Heda Melinda D. Nataprawira
Department of Child Health, Faculty of Medicine
Padjadjaran University-Dr. Hasan Sadikin Hospital
Jl. Pasteur No. 38, Bandung, Indonesia
Tel: +62-22-2035957
Fax: +62-22-2034426
Email: heda_1155@yahoo.com

Case 1

D, a 9-year-old boy, admitted to the Pediatric Emergency Department Dr. Hasan Sadikin Hospital Bandung on

February 12th, 2009 (at 04.00 pm) with snakebite as a chief complaint. One and a half hour before admission, his left fifth finger was bitten by a snake that he played with at a cemetery near his school. Fifteen minutes later, his finger became swelling, bruising, pain and bleeding at the fang bites. The boy then felt tingling at his left hand and complaining of shortness of breath, nausea and headache so he was brought to the headmaster's office. There were no palpitation, weakness, diaphoresis, numbness around the lips, double vision, vomit, other bleeding manifestation, and seizure or altered consciousness. The snake was identified as black-colored with a triangular head, broad neck and yellowish color behind its head. Because of his complaint, the boy was sought for emergency care at the nearest hospital where his wound was cleansed, and his fifth finger was splinted with bandage proximal to the lesion. He was given a tetanus toxoid injection. Because there were no antivenin sera available, the patient was referred to Dr. Hasan Sadikin Hospital.

The boy used to play with reptiles such as snakes and lizards. He had already completed standard immunization.

At physical examination, the boy was conscious, oriented. He could still have usual activities like before, with irregular heart rate. At his distal little finger there was fang bite marks, hematoma, edema and bleeding (**Figure 1**). There was tourniquet bandage at the proximal lesion. Neurological examination was within normal limit. Laboratory finding such as complete blood count, prothrombin time (PT), activated partial thromboplastin time (aPTT), fibrinogen, electrolyte, glucose, ureum, creatinine, liver function test, urinalysis were within normal limit. The electrocardiography record showed a supraventricular extrasystole (**Figure 2**).

Case 2

J, a 12-year-old boy presented to the Pediatric Emergency Department Dr. Hasan Sadikin Hospital Bandung at 02.30 am on February 13th, 2009 with chief complaint of snakebite on his left hand of 7-hour duration. The patient was praying at the terrace of a mushola when a snake bit him. He had initially bleeding and swelling at his hand, accompanied with pain, numbness and tingling. He had no numbness around the lips, double vision, sweating, fever, dark urine,

shortness of breath nor weakness. The patient said that the snake had brown-black colored with triangular head 40 centimeters length.

Because of his complaint, he was sought to the nearest hospital (approximately seven hours later). On his way to the hospital, the boy vomitted three times, and felt headache. At the hospital his wound was cleansed. He was given a tetanus toxoid injection, and had a splinted bandage of his left hand. Because there was no antivenin sera available at the hospital, the boy was planned to be referred to Dr. Hasan Sadikin Hospital, nevertheless his parents took him home. After 3 hours at home, he was then brought to Dr. Hasan Sadikin Hospital.

The boy had already completed standard immunization and tetanus immunization booster when he was at the first grade.

At physical examination the boy was conscious, still oriented, and there was no shortness of breath. At his dorsum manus sinistra there was a fang bite marks with swelling around the marks, and local pain. The neurological examination finding was within normal limit. Laboratory findings include complete blood count, PT, aPTT, fibrinogen, electrolyte, glucose, ureum, creatinine, liver function test, urinalysis were within normal limit. The electrocardiogram showed normal sinus rhythm.

According to signs and symptoms at emergency ward, these boys were classified as having a II grading scale (moderate). The boys were given 5 vials antivenin sera administration diluted with 500 ml NaCl 0,9% solution.

Discussion

It's been estimated globally at least 421,000 envenomings and 20,000 deaths occur each year due to snakebite and around 12,000 cases of snakebites occur in Indonesia. (2) In Australia, it was estimated that there were 500 to 3000 snake bites annually. In about 200 to 500 cases antivenom are required. (3) Recorded data in Dr. Hasan Sadikin Hospital Bandung showed that there were 10 cases of snakebites between 2007 and 2008 and mostly were adult patients.

In Utah, United States, 20 poisonous snakebites were estimated to occur annually. (5) Even though snakebites occur throughout the world, envenoming snakebites are thought to present a mostly important yet largely neglected threat to public health. This is especially true in rural areas of tropical and sub tropical countries like Indonesia where snakebites are likely not uncommon. (2) However, there is limited access to health care and to antivenins availability. Despite there is limited opportunity for clinical experience, practitioners have to be prepared for first-aid measure and treatment for snakebites victims.

Ankyrodon rhodostoma, *Bungarus fasciatus*, and *Naja sputatrix* are three of the most common venomous snakes found in Indonesia. Antivenin sera which available in Indonesia could neutralize these three species. (6) Patient in the first case could accurately identify the responsible snake that bit his finger which we assume came from subfamily of *Elapidae*. (7) However, the patient in the second case could not recognize the snake.

Snake venom can be classified as hemotoxic and neurotoxic. Hemotoxic symptoms includes intense pain, edema, weakness, swelling, numbness or tingling, rapid pulse, ecchymoses, muscle fasciculation, oral paresthesia, unusual metallic taste, vomiting, confusion, and bleeding disorder. Neurotoxic symptoms include minimal pain, ptosis, weakness, paresthesia (often at bite site), diplopia, dysphagia, sweating, salivation, diaphoresis, hyporeflexia, respiratory depression, and paralysis. (1,4) Clinical manifestations of snakebites range from mild local reactions to life-threatening systemic conditions, depending on the species and size of the snake, location of the bite, amount of venom injected, and age, size, and health of the victim. (1) Ninety-seven percent of bites were inflicted on the extremities: 34% on the upper extremities, and 63% on the lower extremities. (4) Children and young adult from 19 years of age have higher rate of envenoming snakebites in United States than any other age group. (4) Fifteen percent of the bites happened while children were playing -9% in their own yards and 6% elsewhere- as we seen in the second case. However, in our first case due to the patient's hobby playing with the reptiles, he accidentally got bitten on his finger by the snake which he played with. Children tend to suffer more morbidity and mortality due to their smaller body size. (4) In many snakebites only local effect occur

because insufficient venom injected or non-venomous snake. (3) Systemic reactions of venomous snakebites include a syndrome similar to disseminated intravascular coagulation, acute renal failure, hypovolemic shock, and death. (8)

A careful history including what first aid has been applied is required. Attempt to identify the species of the snake is also essential in diagnosis and management of snakebites. Knowledge of species exclusive in certain geographical area could assist in the diagnosis of the snakebite. Wound inspection could be informative. Absent of the unique fang bite marks and painless or no local reaction at the wound is inconsistent with venomous snakebite. (4,8,9) If the type of snake responsible cannot be identified, the victims should be managed as if he was bitten by a venomous snake and receive antivenin administration immediately, particularly when there are signs of envenomation such as swelling, pain, and numbness. There are several reports regarding tetanus attributable to snakebite. (8) We found fang bite marks in both of the above patients. Both of the patients also showed signs and symptoms consistent of envenomation. Therefore, antivenin sera administration should be given immediately to them. At the field, wound of snakebites should not be washed so that the area can be swabbed for venom detection. Immobilization of the patient is recommended. Constricting bands are recommended, but only if they can be precisely pressure regulated so as to obstruct lymphatic and superficial drainage without obstructing venous or arterial flow. (10) At hospital the wound should be cleansed and immobilization continued. (3,10) Unfortunately, not every critical care services have snake venom detection kit. Both of our patients were referred in the condition of the wound had been cleansed in the referral hospital.

Snake venoms contain many enzymes and other toxin (low-molecular weight polypeptides) that disrupt cellular processes, resulting in vascular damage and tissue destruction. This results in tissue loss and release of potassium into the circulation. If potassium levels raise high enough, this may cause heart irregularities (dysrhythmias). (9) From patient of the first case, physical examination and ECG record showed heart arrhythmia with normal value of potassium level (**Figure 4A**). Six hours following antivenin sera administration, physical examination and ECG record showed altering in heart rhythm into regular (**Figure 4B**).

A popular scale for grading the severity of snakebites and estimating the antivenin dose is presented in **Table 1**. Both of the above patients' presentations are consistent with moderate severity and thus each was administered five vials of antivenin sera.

Antivenin sera should be administered in four hours after snake bite, and it still effective until twenty-four hours later. (1,4) In the first case, the snake bite happened one and a half hour before the boy admitted to Dr. Hasan Sadikin Hospital, meanwhile in the second case, the snake bite happened seven hours before admission. Both patients were given antivenin sera administration immediately. Before administrate the antivenin sera, the skin test were performed eventhough it still a controversion because it could delayed the treatment; it could also caused an anaphylaxis reaction and serum sickness. From several studies, it has been demonstrated a 10-36% false-negative rate and a 33% false-positive rate. The medicolegal issues mandate that the skin test be performed before antivenin administration except in emergency condition. (1) In these cases, as the package insert recommends both patients were given a skin test with negative result, then they were given antivenin sera five vials diluted in 500 ml NaCl 0,9% solution in 4-6 hours, (6) there were no anaphylaxis reaction or serum sickness found. Other literature said that antivenin polyvalent (equine) administered by infusing the initial 5-10 ml dilution over 3-5 minutes while carefully observing the patient for signs and symptoms of sensitivity reaction. If no reaction occurs, continue infusion at a safe I.V. fluid delivery rate. (11) Other while, antivenin polyvalent (ovine) could be administered in 1 hour, with initial dose two to four vials diluted in 250 ml NaCl 0,9% solution. If the initial control of local and systemic symptoms achieved, we could give additional infuse of three maintenance doses to prevent recurrence consisting of two-vial doses at 6, 12, and 18 hours diluted in 250 ml NaCl 0,9% solution after the first administration. If the initial control did not achieve, we could give additional

4-6 vials until three times. (11-14) Previous study reported that the mean doses of antivenin administered for the various grade of envenomation did not vary much among the various age groups. Even though small children received approximately the same total dose of antivenin as did adults, it is obvious that they received a higher dose in cc/kg of body weight. Therefore, the exact dose for children in cc/kg cannot be ascertained as an ideal dose for administration of antivenin. (4)

There are several antivenin sera preparation derived from equine-antivenin sera (antivenin crotalidae polyvalent [ACP]) and ovine-antivenin sera (CroFab) which has been proved by FDA. (15-17). The antivenin sera available at Dr. Hasan Sadikin Hospital is derived from polyvalent antivenin sera (equine) that could neutralized the venom of *Ankyrodon rhodostoma*, *Bungarus fasciatus*, and *Naja sputatrix*. These three types of snakes were common in Indonesia. The choice of antivenin sera administration was adjusted the type of the snake. Hospitalization for at least 24-48 hours was needed afterward for observation of the venom effect such as swelling, neurological or hematological abnormalities. (16,17)

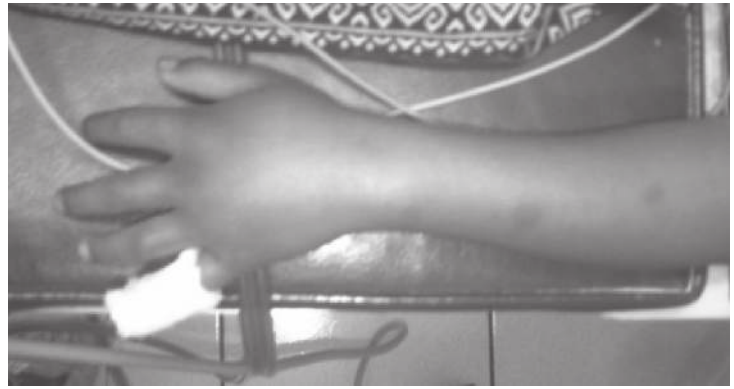Conclusion

Snakebites are uncommon, but potentially life-threatening. It is characterized by local and systemic effects including coagulopathy, neurotoxicity, miotoxicity and renal impairment. The effective first aid is immobilization. Antivenin should be administered by slow intravenous infusion in Emergency Department. In tropical countries such in Indonesia where snakebites are likely not uncommon, we have to prepare the availability of antivenin sera at the hospitals and Primary Health Services.

Figure 1. The Fang Bites at Digiti V Manus Sinistra (A) and Swelling Beyond the Area Adjacent to Dorsum Manus and Antebrachii (B) of Case 1.



A



B

Figure 2. ECG Record Showed a Supraventricular Extrasystole.

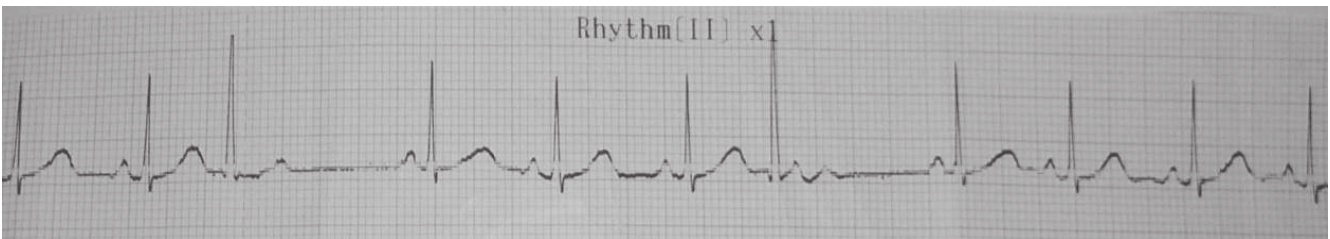
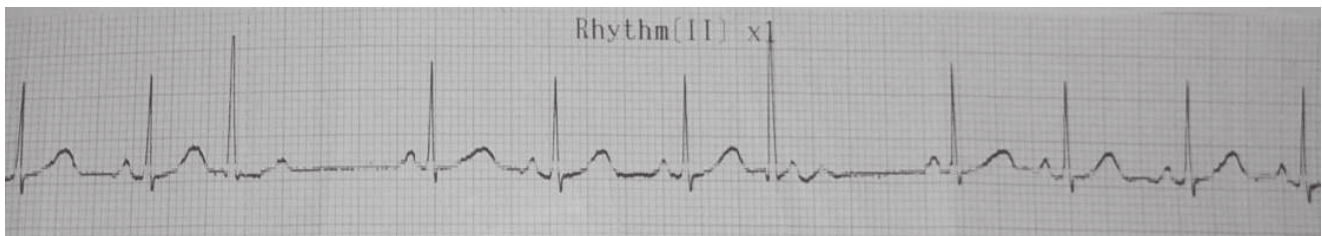


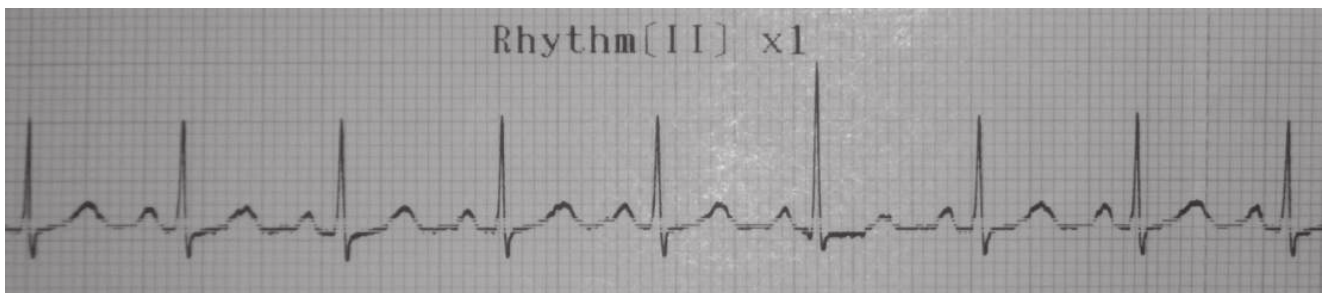
Figure 3. Fang Bite Marks (Circle), and Swelling (Arrows).

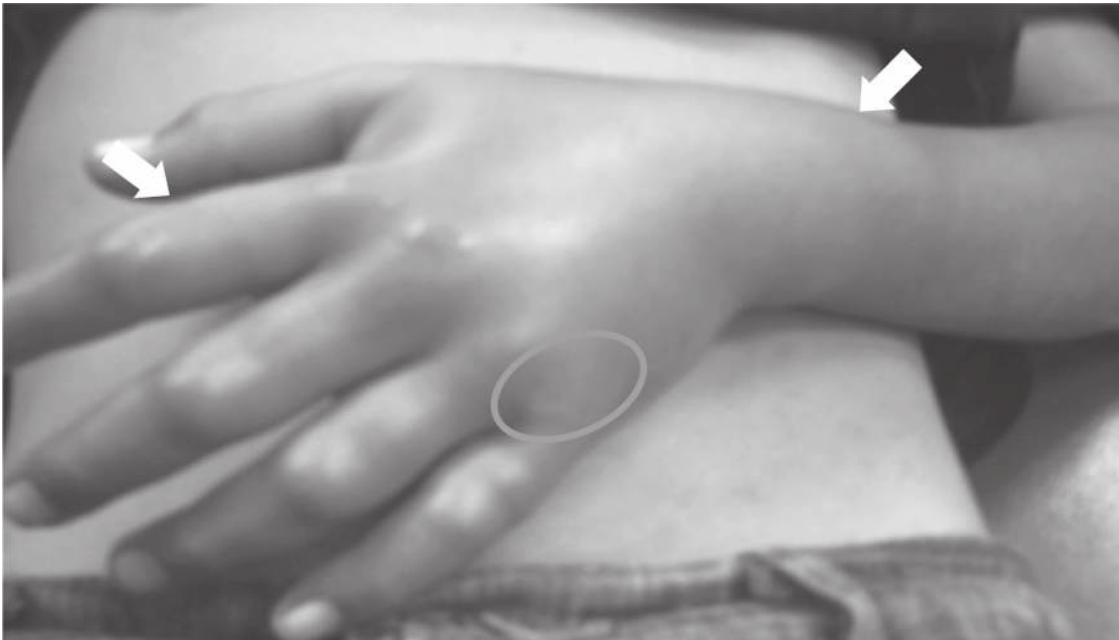

Figure 4. ECG Record Prior to (A) and Six Hours (B) Following Antivenin Sera Administration



A



B

Table 1. Grading Scale for Severity of Snakebites.

Degree of envenomation	Presentation	Treatment
0. None	Punctures of abrasions; some pain or tenderness at the bite	Local wound care, no antivenins
I. Mild	Pain, tenderness, edema at the bite; perioral paresthesia may be present	If antivenin is necessary, administer about 5 vials
II. Moderate	Pain, tenderness, erythema, edema beyond the area adjacent to the bite; often systemic manifestations and mild coagulopathy	Administration of 5 to 15 vials of antivenin may be necessary
III. Severe	Intense pain and swelling of entire extremity, often with severe systemic signs and symptoms; coagulopathy	Administer at least 15 to 20 vials of antivenin
IV. Life-threatening	Mark abnormal signs and symptoms; severe coagulopathy	Administer at least 25 vials of antivenin

Sources: Juckett, et al, 2002; Farrish, et al, 1965

References

1. Juckett G, Hancox JG. Venomous snakebites in the United States: management review and update. *Am Fam Physician* 2002;65:1367-74,1377.
2. Kasturiratne A, Wickremasinghe AR, de Silva N, Gunawardena NK, Pathmeswaran A, Premaratna R, et al. The global burden of snakebites: a literature analysis and modelling based on regional estimates of envenoming and deaths. *PLoS Med* 2008;5:e218.
3. Isbister GK. Snake bite: a current approach to management. *Aust Prescr* 2006;29:125-9.
4. Parrish HM, Goldner JC, Silberg SL. Comparison between snakebites in children and adults. *Pediatrics* 1965;36:251.
5. Plowman DM, Reynolds TL, Joyce SM. Poisonous snakebite in Utah. *West J Med* 1995;163:547-51.
6. Serum Anti Bisa Ular [package insert]. Bandung (Indonesia): Biofarma Perum (Pasteur Institute); 1995.
7. Weber A. *Naja sputatrix*. [Online]. [2009] [cited 2009 Feb 13]. Available from: URL:www.exoterra.ch.
8. Kao TL, Juan CW. Tongue viability after snakebite--an unusual occupational hazard. *Am J Emerg Med* 2007;25:1083.e5-7.
9. Boyd JJ, Agazzi G, Svajda D, Morgan AJ, Ferrandis S, Norris RL. Venomous snakebites in mountainous terrain: prevention and management. *Wilderness Environ Med* 2007;18:190-202.
10. Mattingly J, Bosse G. Snake bite module: snake bite in the state of kentucky. [Online]. [2005]. [cited 2009 Feb 18]. Available from: URL:<http://www.krpc.com/proffed/snake/snakebite.cfm>.
11. University of Maryland Medical Center. Antivenin (crotalidae) polyvalent. [Online]. [2008]. [cited 2009 Feb 18]. Available from: URL:<http://www.umm.edu/altmed/drugs/antivenin-crotalidae-008200.htm>.
12. McKinney PE. Out-of-hospital and interhospital management of crotaline snakebite. *Ann Emerg Med* 2001;37:168-74.
13. Gold BS, Dart RC, Barish RA. Bites of venomous snakes. *N Engl J Med* 2002;347:347-56.
14. Cox MR, Reeves JK, Smith KM. Concepts in crotaline snake envenomation management. *Orthopedics* 2006;29:1083-7.
15. Holstege CP, Miller MB, Wermuth M, Furbee B, Curry SC. Crotalid snake envenomation. *Crit Care Clin* 1997;13:889-921.
16. Clark RF, Selden BS, Furbee B. The incidence of wound infection following crotalid envenomation. *J Emerg Med* 1993;11:583-6.
17. Smith TA 2nd, Figge HL. Treatment of snakebite poisoning. *Am J Hosp Pharm* 1991;48:2190-6.