Purpura Fulminans Due to Staphylococcus Aureus: An Emerging Disease

Fernando Pavel González Ibarra, Carlos Hernández Iturbe, Arnoldo Millán Montoya, Luis Armando Ochoa Herrera, José de Jesús Ibarra Meza, Alberto Nieto Villaseñor

Abstract

***Background*: Purpura fulminans is an acute illness commonly associated with meningococcemia or invasive streptococcal disease. It is characterized by disseminated intravascular coagulation and purpuric skin lesions. In this article we reported a case of purpura fulminans associated with Staphylococcus aureus.**

***Methods*: The case was identified in the General Hospital of Mazatlán, Sinaloa, México during 2007. Staphylococcus aureus infection was diagnosed on the basis of culture result. Susceptibility to methicillin was determined. The ability of the isolated organism to produce super antigens was not possible to determine.**

***Results*: The isolated strain of Staphylococcus aureus in the present case was isolated from secretion of an intact phlyctena; the organism was not obtained from blood cultures. The isolated strain was methicillin resistant. We used immunomodulator drugs as alfa-2a interferon and thalidomide, antibiotics and support measures. The patient survived with intact extremities.**

***Conclusions*: Purpura fulminans due to Staphylococcus aureus is a newly and emerging disease commonly associated with superantigen production. It is a very aggressive and even fatal illness that deserves special attention.**

Key words: Purpura fulminans, Staphylococcus aureus.

Introduction

There have been few reported cases of purpura fulminans (PF) associated with Staphylococcus aureus. The largest series have been published in 5 cases. (1) Until recently, PF was a disease with a strong association with meningococcemia. This is because of a high percentage of patients with acute meningococcemia develop purpura fulminans. It has been reported to around 20%. (2) However, meningococcal infections are relatively rare. According to one report in the United States in 1998, only 2501 cases of meningococcal bacteremia were reported, and only a few cases of purpura fulminans were due to meningococcemia. (3) Nowadays, Staphylococcus aureus is not well recognized as an important cause of purpura fulminans.

Staphylococcus aureus bacteremia is more frequent than meningococcal bacteremia. It is estimated that the incidence of Staphylococcus aureus bacteremia may be, in the United States, approximately 100,000 cases annually. Therefore, the frequency of bacteremia due to Staphylococcus aureus could be up to 200 times greater than meningococcemia, which would put Staphylococcus aureus bacteremia as a real problem. (4)

From General Hospital of Culiacán "Bernardo J. Gastélum". SSA. The University Autonomous of Sinaloa (Fernando Pavel González Ibarra), General Hospital of Mazatlán "Martiniano Carvajal" SSA. The University Autonomous of Sinaloa (Carlos Hernández Iturbe, Arnoldo Millán Montoya, Luis Armando Ochoa Herrera, José de Jesús Ibarra Meza, and Alberto Nieto Villaseñor)

Address for correspondence:

Dr. Fernando Pavel González Ibarra

Department of Internal Medicine

General Hospital of Culiacán "Bernardo J. Gastélum". SSA

Aldama y Nayarit sin número, Col. Rosales. Culiacán, Sinaloa, México

Tel: (52-667) 7169810 (Ext. 136)

Email: drpavelglez@yahoo.com.mx

Given the fact that this disease is not classified by the Centers for Disease Control and Prevention as a notifiable disease, detailed epidemiological data on incidence is not available. Most of the cases of PF due to Staphylococcus aureus have a fatal or disabling outcome with severe sequelae. (1)

On the other hand, from a treatment standpoint, there are reports on the use of immunomodulators such as thalidomide that have been used in several illnesses, as vasculitis of various etiologies, such as Behçet's syndrome, (5) Kaposi sarcoma, (6,7) and other diseases such as multiple myeloma (8) and myelodysplastic syndromes. (9) Interferons are immunomodulators with many properties and therapeutic uses. Interferons have been used in some vasculitis too, even in combination with thalidomide. (10) We describe a case of PF due to Staphylococcus aureus in where immunomodulators were used with good results.

Methods

The patient described was at the General Hospital of Mazatlán, Sinaloa, México and occurred in 2007. Bacteriological cultures and susceptibility to methicillin were carried out at hospital admission.

Blood cultures and cultures of secretion of intact phlyctena were performed. Determination of exotoxin production was not carried out by not having the material availability.

Results and Description of Patient

A 51-year-old gentleman presented to the hospital with fever and myalgias. He had a history of 30 years of smoking and alcoholism. Eight days before hospital admission, he fell from his own height and injured to both knees after falling. After that he developed pain while trying to do any movement in his left leg and right thigh. Four days later he began with swelling in his right leg, changes in the color of the leg (became purple-blue), and began to appear phlyctenae in the entire leg. The day of the hospital admission, the patient developed paresis and paresthesia of the leg and became tachypneic. On arrival at emergency department physical examination revealed blood pressure of 60/40 mmHg, a heart rate of 140 beats per minute, respiratory rate of 28 per minute and a temperature of 36.4º C (97.5º F). His right leg showed important swelling with purple-blue macules and confluent phlyctenae around the foot. Palpation of the tight was painful.

Laboratory data revealed white blood cell count of 10,000/mm^3 with neutrophil 83%, presence of immature forms (bands), 0.4% eosinophils, hemoglobin of 16 g/dl, platelet count of 61,000/mm^3, glucose of 165 mg/dl, creatinine of 3.6 mg/dl, PT 13 sec and PTT 45 sec. Liver function tests revealed an AST 291 mg/dl, ALT 273 mg/dl, alkaline phosphatase 291 mg/dl, total bilirubin 3.4 mg/dl and direct bilirubin 2.2 mg/dl. Arterial blood gases showed metabolic acidosis. CXR was normal.

Three days after hospitalization, the patient begins to form necrotic lesions on both feet that were spreading quickly toward his legs, thighs and even lower back and sacral region (**Figures 1** and **2**).The patient began with short periods of fever and altered mental status, began as a hyperactive delirium through a state of lethargy and stupor. Staphylococcus aureus was isolated from culture of sterile secretion phlyctena, which was methicillin resistant.

Skin biopsies were taken from the edge and center of the lesions on the thigh. Fibrinoid necrosis of blood vessel walls in the dermis were found compatible with PF (**Figures 3** and **4**).The patient was treated with ceftriaxone, clindamycin, vancomycin, thalidomide and interferon alfa-2 as immunomodulators, as well as supportive measures.

Over a period of 4-5 days the patient improved dramatically. The skin lesions began to implement a remission process (**Figure 5**) and his laboratory tests returned to normal values.

Discussion

An extensive literature on PF has been published since the term was first introduced by Henoch in 1887. It is now clear that PF is not a single disease but a common clinicohistological manifestation of a wide range of distinct

disease processes. (11) The term "purpura fulminans" was initially used to describe the rapid onset of purpura and necrosis of the skin associated with bacterial infections in children only. To date, the infection most commonly associated with PF is meningococcemia, and in second place streptococcal infection. (1)

PF has been strongly associated with meningococcemia, and has been used as a synonym for the Waterhouse-Friederichsen syndrome. (12) It has also been associated with deficiencies of protein S (13) or C (14) and is described in cases of purpura which developed in patients with sepsis. (15) PF has also been associated with artificial abortions, (16) infection with plasmodium falciparum, (17,18) dengue hemorrhagic fever (19) and in patients with varicella. (20) An attempt has been made to classify PF into eight groups, based on clinical and epidemiological criteria: acute infectious PF, postinfectious PF, congenital protein C or S deficiency, acquired protein C or S deficiency associated with drugs or disease, antiphospholipid syndrome, vasculitic disorder, platelet mediated PF, and PF following bites and envenomation. (21) There are other authors who try to classify this entity into three categories, according to the triggering mechanisms. First, neonatal PF (associated with a hereditary deficiency of the natural anticoagulants protein C and protein S as well as antithrombin III), idiopathic PFs (usually follows an initiating febrile illness that manifests with rapidly progressive purpura, deficiency of protein S is considered to be central to the pathogenesis of this form of the disease) and the third and most common type of purpura fulminans is acute infectious purpura fulminans. (22)

There some reports in which severe myalgia is the first clinical manifestation of PF. (23) However, myalgia has typically been overlooked and undervalued as an important early clinical feature (especially of meningococcal sepsis). Our patient presented in a similar way.

The hallmark of the disease is thrombotic occlusion of dermal vessels with hemorrhagic infarction of the surrounding tissue. Inflammatory infiltrate may not always be present but is usually marked, in a primary vasculitic process with evidence of fibrinoid necrosis of blood vessel walls. Other laboratory investigations may reveal evidence of disseminated intravascular coagulopathy. Protein C or S levels can be low. Leucocytosis with left shift is a common finding. Alterations in coagulation may be so intense that there are cases reported of PF associated with chronic subdural hematoma, but this is an uncommon association. (24)

After the acute illness has resolved, purpuric lesions may lead to extensive tissue loss and prolonged morbidity. Although vascular beds throughout the body are affected, and lesions can be seen in all areas of the skin, the distribution of permanent lesions is often confined to the peripheries, resulting in amputation of digits, hands and feet, or even limbs. Many pharmacological strategies have been used in attempts to reduce the tissue loss, but as yet none have proved to be consistently safe and effective. (25)

As noted before, Staphylococcus aureus infections were rarely complicated with PF (26-28). Even recently, in a series of 113 community-acquired bacteremia due to Staphylococcus aureus, PF did not complicated any case. (29) The pathophysiology of this entity is explained mainly because Staphylococcus aureus causes invasion and elaboration of exotoxins. These exotoxins are in a family of exotoxins that are known as *super antigens*. The name is because of its non-specific antigen activation of T cells. (30) These super antigens bind major histocompatibility complex class II molecules and trigger a massive release of cytokines by T cells and macrophages. The main and most important super antigens elaborated by Staphylococcus aureus are toxic shock syndrome toxic-1 and other enterotoxins serotypes, mainly serotypes B and C. (31)

Due to the experience and the evidence that is emerging from cases like this and previously published series, (1) we can recommend that in cases of PF, antibiotic therapy must cover not only Neisseria meningitides and Streptococci, but also Staphylococcus aureus, especially methicillin-resistant Staphylococcus aureus.

Our patient had a favorable outcome. Immunomodulatory therapy was used to stop the systemic inflammatory process. It is possible to attribute any beneficial role in the evolution of the patient to immunomodulatory therapy. This may even lead to take into account the use of this therapy in new reports, and probably with further evidence, recommend its use.

Figure 1. Purpura Fulminans on Foot.

Figure 2. Necrotic Lesions on Both Feet that Were Spreading Quickly Toward the Legs.

Figure 3. Skin Biopsy Shows Bulla Filled with Erythrocytes. Necrosis Is Observed in the Epidermis, and the Presence of Edema in the Dermis.

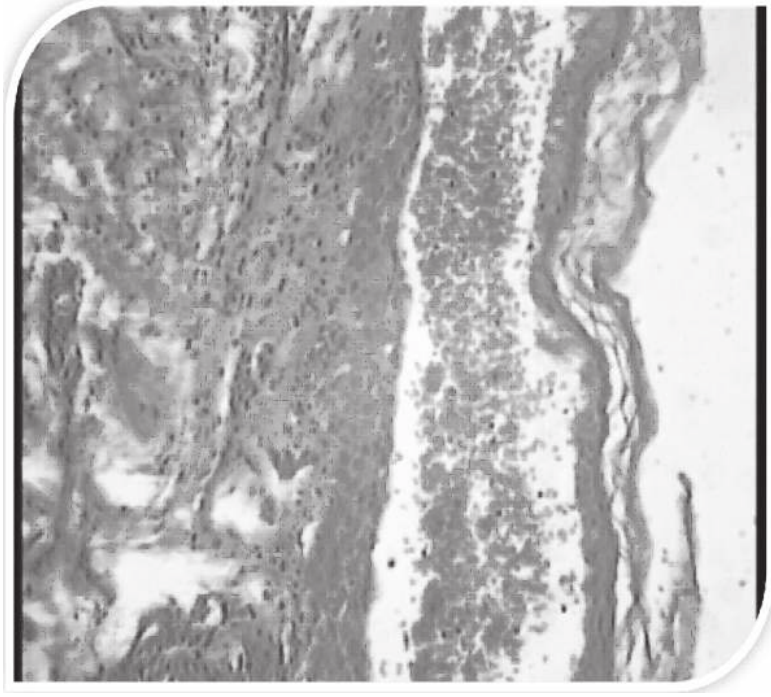

Figure 4. Skin Biopsy Small with Caliber Blood Vessels and Fibrinoid Necrosis of Blood Vessel Walls.

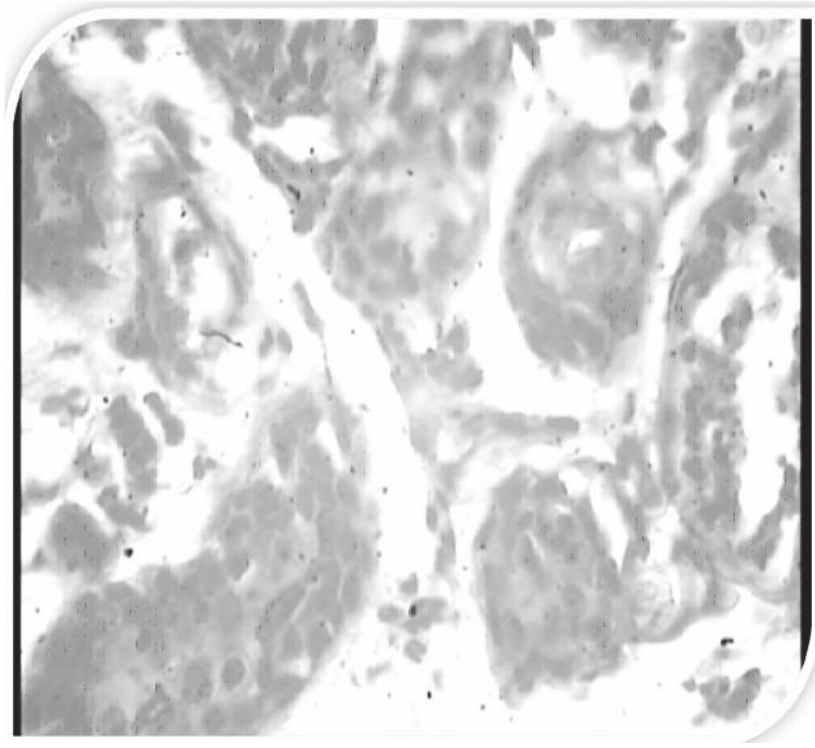

Figure 5. Purpura Fulminans in Remission.

References

1. Kravitz GR, Dries DJ, Peterson ML, Schlievert PM. Purpura Fulminans Due to Staphylococcus aureus. Clin Infect Dis 2005;40: 941-7.
2. Harrison OB, Robertson BD, Faust SN, Jepson MA, Goldin RD, Levin M, et al. Analysis of pathogen-host cell interactions in purpura fulminans: expression of capsule, type IV pili, and PorA by Neisseria meningitidis in vivo. Infect Immun 2002;70:5193-201.
3. Centers for Disease Control and Prevention (CDC). Summary of notifiable diseases, United States, 1998. MMWR Morb Mortal Wkly Rep 1999;47:ii-92.
4. Wenzel RP, Edmond MB. The impact of hospital-acquired bloodstream infections. Emerg Infect Dis 2001;7:174-7.
5. Hamza MH. Treatment of Behçet's disease with thalidomide. Clin Rheumatol 1986;5:365-71.
6. Cattelan AM, Trevenzoli M, Aversa SM. Recent advances in the tratment of AIDS-related Kaposi's sarcoma. Am J Clin Dermatol 2002;3:451-62.
7. Sternbach G, Varon J. Moritz Kaposi: idiopathic pigmented sarcoma of the skin. J Emerg Med 1995;13:671-4.
8. Pandit S, Vesole DH. Relapsed multiple myeloma. Curr Treat Options Oncol 2001;2:261-9.
9. Zorat F, Pozzato G. Thalidomide in Myelodisplastic syndromes. Biomed Pharmacother 2002;56:20-30.
10. Krown SE. Management of Kaposi sarcoma: the role of interferon and thalidomide. Curr Opin Oncol 2001;13:374-81.
11. Stein RH, Sapadin AN. Purpura fulminans. Int J Dermatol 2003;42:130-1.
12. Varon J, Chen K, Sternbach GL. Rupert Waterhouse and Carl Friderichsen: adrenal apoplexy. J Emerg Med 1998;16:643-7.
13. Levin M, Eley BS, Louis J, Cohen H, Young L, Heyderman RS. Postinfectious purpura fulminans caused by an autoantiboby directed against protein S. J Pediatr 1995;127:355-63.
14. Minhas KM, Bashir S, Sarwari AR, Parker J. Pneumococcal purpura fulminans successfully treated with activated protein C. South Med J 2008;101:1046-8.
15. Gamper G, Oschatz E, Herkner H, Paul G, Burgmann H, Janata K, et al. Sepsis-associated purpura fulminans in adults. Wien Klin Wochenschr 2001;113:107-12.
16. Ichimiya M, Takita Y, Yamaguchi M, Muto M. Case of purpura fulminans due to septicemia after artificial abortion. J Dermatol 2007;34:786-9.
17. Corne P, Bruneel F, Biron-Andreani C, Jonquet O. Purpura fulminans due to imported falciparum malaria. Intensive Care Med 2008;34:2123-4.
18. Khaira A, Gupta V, Gupta A, Mahajan S, Bhowmik D, Tiwari SC. Purpura fulminans in a complicated Falciparum malaria. J Assoc Physicians India 2008;56:467-9.
19. Karunatilaka DH, De Silva JR, Ranatunga PK, Gunasekara TM, Faizal MA, Malavige GN. Idiopathic purpura fulminans in dengue hemorrhagic fever. Indian J Med Sci 2007;61:471-3.
20. Hernández Blanco A, González Montero R, Urán Moreno MM, Caturla Martínez-Moratalla J, Moya Benavent M. Post-varicella purpura fulminans: Potentially fatal. An Pediatr (Barc) 2009;70:379-82.
21. Nolan J, Sinclair R. Review of management of purpura fulminans and two case reports. Br J Anaesth 2001;86:581-6.
22. Edlich RF, Cross CL, Dahlstrom JJ, Long WB 3rd. Modern concepts of the diagnosis and treatment of purpura fulminans. J Environ Pathol Toxicol Oncol 2008;27:191-6.
23. de Souza AL, Sztajnbok J, Salgado MM, Romano CC, Alkmin MG, Duarte AJ, et al. Severe myalgia of the lower extremities as the first clinical feature of meningococcal purpura fulminans. Am J Trop Med Hyg 2007;77:723-6.
24. Salas de Zayas R, Dólera Moreno C, Peiró Ferrando LZ, Mollá Jiménez C. Spontaneous subdural hematoma associated to purpura fulminans in a splenectomized patient. Med Intensiva 2008;32:453.
25. Oram J, Bodenham A. Hypothesis: is the skin and tissue loss associated with septic purpura fulminans temperature related? Parallels with the anatomical distribution of frostbite. Med Hypotheses 2008;70:1155-9.
26. Robboy SJ, Mihm MC, Colman RW, Minna JD. The skin in disseminated intravascular coagulation: prospective analysis of thirty-six cases. Br J Dermatol 1973;88:221-9.
27. Rintala E, Kauppila M, Seppälä OP, Voipio-Pulkki LM, Pettilä V, Rasi V, et al. Protein C substitution in sepsis-associated purpura fulminans. Crit Care Med 2000;28:2373-8.
28. Murray HW, Tuazon CU, Sheagren JN. Staphylococcal septicemia and disseminated intravascular coagulation: Staphylococcus aureus endocarditis mimicking meningococcemia. Arch Intern Med 1977;137:844-7.
29. Willcox PA, Rayner BL, Whitelaw DA. Community-acquired Staphylococcus aureus bacteraemia in patients who do not abuse intravenous drugs. QJM 1998;91:41-7.
30. McCormick JK, Yarwood JM, Schlievert PM. Toxic shock syndrome and bacterial superantigens: an update. Annu Rev Microbiol 2001;55:77-104.
31. Schlievert PM, Tripp TJ, Peterson ML. Reemergence of staphylococcal toxic shock syndrome in Minneapolis–St. Paul, Minnesota, during the 2000–2003 surveillance period. J Clin Microbiol 2004;42:2875-6.