

Red blood cell fragmentation in acute respiratory distress syndrome following *Candida dubliniensis* pneumonia

Jun-ichi Hirata, Munehiko Ohya, Seishiro Marukawa, Keiji Kumon

Abstract

Background: The mechanisms underlying red blood cell fragmentation in intensive care patients remain controversial. *Candida dubliniensis* infection is very rarely reported in the world, and which has primarily been restricted to patients with a weakened immune system, and there is limited clinical information about the virulence of *C. dubliniensis* for hemolytic activity.

Case: A 79-year-old man, who had recovered from acute respiratory distress syndrome (ARDS), presented with severe sepsis and was transferred to the emergency room. The ratio of arterial oxygen partial pressure to the fraction of inspired oxygenation (FiO₂) (P/F ratio) in the arterial blood gas analysis

was low (77%). Immediate treatment included intubation and antibiotic infusion. However, after 17 days, his general condition deteriorated suddenly, and red blood cell fragmentation was observed upon hematological examination. We treated him with an infusion of 4 units of packed red blood cells and 4000 units of haptoglobin. However, 3 days later, the patient died of multiple-organ failure and disseminated intravascular coagulation. Throughout the treatment period, *C. dubliniensis* pneumonia was detected twice in the examination of his sputum.

Conclusion: To our knowledge, this is the first case report of red blood cell fragmentation in ARDS following *C. dubliniensis* pneumonia in Japan.

Key words: *Candida dubliniensis*, red blood cell fragmentation, sepsis, acute respiratory distress syndrome.

Introduction

Red blood cell fragmentation is associated with high rates of mortality and occurs in the intensive care unit following severe sepsis-induced disseminated intravascular coagulation (DIC) and multiple-organ failure (MOF), both of which are likely to occur in the presence of immunosuppression. (1) Red blood cell fragmentation is considered one of the components of thrombotic microangiopathy (TMA), which also includes thrombocytopenia, erythrocyte fragmentation, and extremely elevated serum lactate dehydrogenase

levels. (2,3) However, details regarding the mechanisms and development of red blood cell fragmentation are unknown, and thus, multidisciplinary therapy is modified pathophysiologically according to the clinical stage of the symptoms. (3)

Candida dubliniensis infection was first described in 1995, when clinical isolates of the species were recovered from the oral cavity or bloodstream of adults with the human immunodeficiency virus (HIV) or acquired immune deficiency syndrome (AIDS). (4) The clinical incidence of severe infections caused by *C. dubliniensis* is increasing, with infections reported in intensive care patients, lung transplant recipients, patients receiving chemotherapy following bone marrow transplantation, and leukemia or cancer patients. (5-9) In addition, this species has been characterized by hemolytic activity, but little is known about its virulence factors. (10,11)

We present a case report of a very rare, fatal case

From Department of Emergency and Critical Care Medicine, Kinki University Faculty of Medicine, Nara Hospital, Nara, Japan (Jun-ichi Hirata, Munehiko Ohya, and Keiji Kumon).

Address for correspondence:

Jun-ichi Hirata

Department of Emergency and Critical Care Medicine, Kinki University Faculty of Medicine, Nara Hospital

1-1248, Otsuda, Ikoma, Nara 630-0293, Japan

Tel: +81-743-77-0880

Fax: +81-743-77-0890

E-mail: qq-hira@i.softbank.jp or qq-hira@hyo-med.ac.jp

of red blood cell fragmentation in a patient who developed acute respiratory distress syndrome (ARDS) following *C. dubliniensis* pneumonia.

Case report

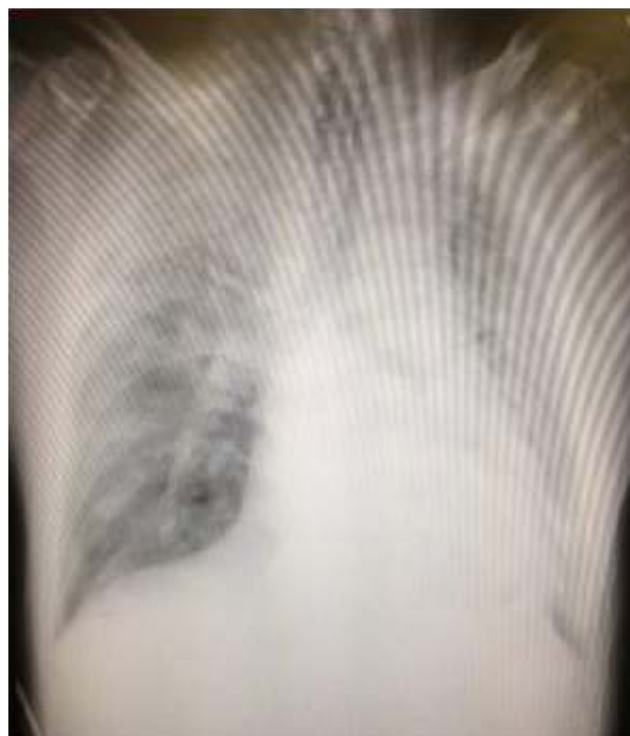A 79-year-old man in respiratory distress was transferred to our emergency room with a history of persistent cough, no sputum for the previous 7 days, and dyspnea at rest. Additionally, he reported weakness with chills, shortness of breath, and fever. He presented with labored breathing in the emergency department at his local hospital, and his peripheral oxygen saturation was 50% in room air. Because of these symptoms, he was transferred to our hospital and admitted to the intensive care unit.

His past medical history was unremarkable. He was not using any medications and did not have any drug allergies. He had been a smoker for 40 years and consumed alcohol occasionally. Additionally, he was negative for HIV and hepatitis C virus (HCV).

Upon hospitalization in the intensive care unit, hypotension (blood pressure 84/41 mmHg), tachycardia (110 beats/min), and fever (temperature 39.0°C) were confirmed. Chest examination revealed bibasilar rhonchi in all lung fields. His extremities were cold and, later, perfused because of cyanosis. His heart and bowel activities were normal. An arterial blood gas test performed with the patient breathing 70% of the fraction of inspired oxygen (FiO₂) revealed a normal pH of 7.43, PCO₂ of 33.6 mmHg, low partial pressure of oxygen (PO₂) of 53.9 mmHg, a low P/F ratio (53.9/0.7=77), and low base excess of -2.3. Laboratory findings revealed neutrophilia (20,900/mm³; 92.0% neutrophils) and an elevated serum C-reactive protein level (26.37 mg/dL). No pathogenic bacteria or viruses were detected in peripheral blood or urine. A simple thoracic radiography revealed bilateral diffuse consolidation consistent with ARDS. Thoracic computed tomography (CT) confirmed diffuse consolidation, multifocal patchy involvement, and lobar disease (**Figure 1**). Neither echocardiograph (EKG) nor Doppler ultrasound revealed pulmonary hypertension or ischemic change in wall motion. At this point, the suspected diagnosis was severe sepsis with ARDS caused by pneumonia. The patient had been given intravenous meropenem in his local hospital as an empiric treatment of community-acquired pneumonia. In the intensive care unit, he was treated with dopamine,

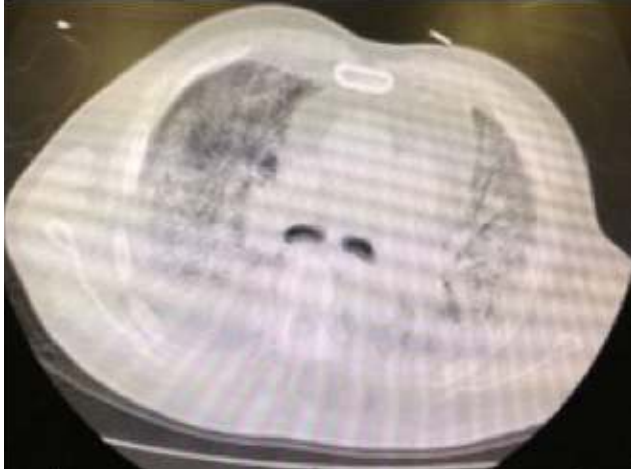
steroids, elastase inhibitor, vancomycin, intubation, and adaptive support controlled ventilation (ASV). However, his hemoglobin levels suddenly decreased from 11.5 to 7.7 mg/dL; upon examination, we noted severe red blood cell fragmentation in a blood smear (**Figure 2**). His haptoglobin levels had decreased to 6 mg/dL, and his reticulocyte count was 12.6%. The results of direct and indirect Coombs' tests were negative. Additionally, aspartate aminotransferase and alanine aminotransferase levels drastically increased to 2827 IU/L and 1529 IU/L, respectively. The platelet count did not change from the levels detected 3 days earlier, i.e., 80,000/mm³. Similarly, the serum levels of lactate dehydrogenase were not elevated (17 mg/dL). The prothrombin time (PT) and activated partial thromboplastin time (APTT) were 26.8 s and 139.1 s, respectively. By this time, *C. dubliniensis* was detected twice in the examination of his sputum. The patient was diagnosed with MOF followed by DIC. Hemolysis improved only briefly with the administration of 4 units of packed red blood cells, but a prompt improvement was observed when the patient was infused with 4000 units of haptoglobin 18 h later. However, the patient's general condition deteriorated further, and 3 days later, he died of multiple-organ failure and disseminated intravascular coagulation.

Figure 1a. A simple thoracic radiography



Legend: Chest radiograph showing bilateral infiltrate.

Figure 1b. Thoracic computed tomography



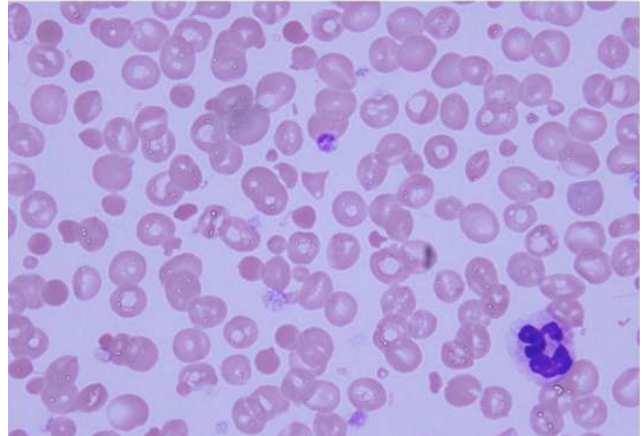
Legend: Chest computed tomography (CT) scan showing a mix of diffuse consolidation and ground-glass opacification with pleural effusion and air bronchograms.

Discussion

To our knowledge, this is the first case report of red blood cell fragmentation in a patient who developed ARDS following *C. dubliniensis* pneumonia in Japan. Although the case presentation could have indicated a TMA-induced triad, the serum lactate dehydrogenase levels were not extremely elevated, leading to some discussion on the appropriateness of such a diagnosis. (3) Other diagnostic possibilities were conditions that play a role in the possible mechanisms and development of red blood cells, such as hemolytic uremic syndrome caused by Shiga-like toxin-producing *Escherichia coli*; however, these organisms were not detected in this case. (1)

Notably, *C. dubliniensis* was detected twice in this patient's sputum. *C. dubliniensis* was first described in 1995 following detection in the oral cavity of HIV-infected individuals. (4) Despite its close relationship with *C. albicans*, which is the predominant pathogenic species, the etiopathologic role of *C. dubliniensis* has mostly been restricted to oral candidiasis. Recently, *C. dubliniensis* has increasingly been reported in patients with candidemia, following conditions resulting in a weakened immune system, such as leukocytosis with a predominance of neutrophils in the presence of nephrotic syndrome, pneumonia with myelodys-

Figure 2. Severe red blood cell fragmentation in a blood smear



Legend: Patient's blood smear showing severe red cell fragmentation.

plastic syndrome, and acute myeloid leukemia. (5-8) Similarly, a study investigating the incidence of *C. dubliniensis* in HIV-infected or AIDS patients in Ireland reported the presence of the species in 15-30% of patients with clinical symptoms of oral candidiasis as well as in 3.5% of HIV-negative healthy individuals. (12) Therefore, *C. dubliniensis* pneumonia may be a consequence of immunosuppression.

The direct effect of this species' virulence for hemolytic activity should be mentioned. The first report of complement-mediated hemolysis induced by *C. albicans* was presented by Manns et al. (11) Furthermore, Luo et al. (10) demonstrated that *C. albicans* and *C. dubliniensis*, in addition to other species, showed alpha and beta hemolysis in 80 isolated *Candida* samples representing 14 species that demonstrated the hemolytic variable expression profiles of the *Candida* species. Moreover, using calcium as a culture mediator, Linares et al. (13) reported that the hemolytic activity of *C. dubliniensis* strains in the oral cavities of AIDS patients was reduced, until a level of 2.5 g% CaCl₂. (10,11) Hemolytic activity, with the subsequent release of hemoglobin, may play a role as an iron source for pathogenic microorganisms that permit the increase of iron-binding proteins.

In conclusion, red blood cell fragmentation may be induced by the direct effect of *C. dubliniensis* species' virulence for hemolytic activity, although this is a very rare case.

References

1. Pene F, Vigneau C, Auburtin M, Moreau D, Zahar JR, Coste J, et al. Outcome of severe adult thrombotic microangiopathies in the intensive care unit. *Intensive Care Med* 2005;31:71-8.
2. Levine H. Microangiopathic hemolytic anemia: the pathogenesis of red blood cell fragmentation, a review of the literature. *Aerosp Med* 1970;41:331-6.
3. Franchini M. Thrombotic microangiopathies: an update. *Hematology* 2006;11:139-46.
4. Sullivan DJ, Westerneng TJ, Haynes KA, Bennett DE, Coleman DC. *Candida dubliniensis* sp. nov.: phenotypic and molecular characterization of a novel species associated with oral candidosis in HIV-infected individuals. *Microbiology* 1995;141:1507-21.
5. Fanci R. Breakthrough *Candida dubliniensis* fungemia in an acute myeloid leukemia patient during voriconazole therapy successfully treated with caspofungin. *J Chemother* 2009;21:105-7.
6. Meis JF, Ruhnke M, De Pauw BE, Odds FC, Siegert W, Verweij PE. *Candida dubliniensis* candidemia in patients with chemotherapy-induced neutropenia and bone marrow transplantation. *Emerg Infect Dis* 1999;5:150-3.
7. Mubareka S, Vinh DC, Sanche SE. *Candida dubliniensis* bloodstream infection: a fatal case in a lung transplant recipient. *Transpl Infect Dis* 2005;7:146-9.
8. Slavin MA, Sorrell TC, Marriott D, Thursky KA, Nguyen Q, Ellis DH, et al. *Candidaemia* in adult cancer patients: risks for fluconazole-resistant isolates and death. *J Antimicrob Chemother* 2010;65:1042-51.
9. Le Guennec R, Reynes J, Mallié M, Pujol C, Janbon F, Bastide JM. Fluconazole- and itraconazole-resistant *Candida albicans* strains from AIDS patients: multilocus enzyme electrophoresis analysis and antifungal susceptibilities. *J Clin Microbiol* 1995;33:2732-7.
10. Luo G, Samaranayake LP, Yau JY. *Candida* species exhibit differential in vitro hemolytic activities. *J Clin Microbiol* 2001;39:2971-4.
11. Manns JM, Mosser DM, Buckley HR. Production of a hemolytic factor by *Candida albicans*. *Infect Immun* 1994;62:5154-6.
12. Coleman DC, Sullivan DJ, Bennett DE, Moran GP, Barry HJ, Shanley DB. *Candidiasis*: the emergence of a novel species, *Candida dubliniensis*. *AIDS* 1997;11:557-67.
13. Linares CE, de Loreto ES, Silveira CP, Pozzatti P, Scheid LA, Santurio JM, et al. Enzymatic and hemolytic activities of *Candida dubliniensis* strains. *Rev Inst Med Trop Sao Paulo* 2007;49:203-6.