

Unusual presentation of clozapine-induced abdominal compartment syndrome

Ying Tung Sia

Abstract

Clozapine-induced gastrointestinal hypomotility is common side effect of this drug. It can lead to various degrees of colon obstruction. In rare cases, it can be life-threatening since severe colon obstruction can lead to colon perforation, colon necrosis and ischemia and septic shock. In

all these cases, there had been some complaints of constipation or abdominal symptoms prior fatal event. Here, we are reporting a case that had rapidly progressed to cardiac arrest in which the initial symptom was dyspnea instead of abdominal complaint.

Key words: Clozapine, intestinal obstruction, abdominal compartment syndrome, cardiac arrest.

Introduction

Clozapine is an atypical antipsychotic drug that commonly prescribed as second line treatment for refractory schizophrenia. (1) It is also considered most dangerous antipsychotic because of its risks of agranulocytosis and myocarditis. Another side effect such as gastrointestinal hypomotility has long been underestimated and underrecognized over decades. Since 1995, several reports have been accumulating and showing varying degree of constipation and intestinal obstruction related to clozapine. (2) In rare cases, the conditions have been fatal since severe colonic obstruction can lead to colon perforation, necrotizing colitis, bowel ischemia and abdominal compartment syndrome. (3) However, in all cases, there had been some complaints of constipation or abdominal symptoms prior fatal event. Here, we are reporting a case that had rapidly progressed to cardiac arrest in which the initial symptom was dyspnea instead of abdominal complaint.

Case

A 37-year-old male had a past medical history of schizophrenia. He has been stable with clozapine for more than 10 years. He presented to community hospital for 2 days history of shortness of breath and dry cough. He denied chest or abdominal pain. He had no history of nausea or vomiting. He had no complaint of constipation. His initial vitals signs included the following: blood pressure of 101/57, heart rate of 110 bpm regular, respiratory rate of 24/min, body temperature of 38.4 °C and O₂ saturation of 90% on room air. He was mildly toxic and short of breath upon speaking.

The first physical examination did reveal distended abdomen. But, there was no sign suggesting acute abdomen. Bowel sounds were decreased. Initial laboratory studies showed increased white blood cells (18×10^9), creatinine 184 $\mu\text{mol/L}$ and sodium 145 mmol/L . The potassium was 4.9 mmol/L . Initial chest radiograph was normal. The working diagnosis was possible bronchitis and broad-spectrum antibiotic (Pip/Taz) has been given considering his toxic condition.

Shortly following admission, his respiratory condition deteriorated following vomiting and aspiration. He rapidly deteriorated to respiratory failure and necessitated intubation and mechanical ventilation. Once intubated, he became hypotensive and finally evolved to pulseless electrical activity cardiac arrest. The patient was resuscitated for 25 minutes and required high dose of noradrenaline (0.8 $\mu\text{g/Kg/min}$) to maintain mean arterial pressure above 65 mmHg . Two liters of normal saline has been given. His respiratory condition kept deteriorating with inspired oxygen of 100% to maintain

From Service of Critical Care, Department of Medicine, Centre Hospitalier Régional de Trois Rivières, University of Montréal, Canada (Ying Tung Sia).

Address for correspondence:

Dr Ying Tung Sia

Service of Critical Care, Department of Medicine, Centre Hospitalier Régional de Trois Rivières
1991 boul. du Carmel, Trois-Rivières, Quebec, Canada, G8Z 3R9

Tel: 819-697-3333 x64040

Fax: 819-372-3530

Email: yts25@hotmail.com

an oxygen saturation of 88%. The patient remained anuric despite aggressive hydration. He was then transferred to our intensive care unit for high frequency oscillation and continuous renal replacement therapy.

Upon arrival severe shock state with sign of peripheral hypoperfusion were present. This was associated with high pressure ventilation and acute renal failure. The lactate was 8 mmol/L and the pH was 7.18. The abdomen of the patient was very distended and hard. The first intraabdominal pressure was 30 mmHg. An abdominal X-ray showed severe colon dilatation with important amount of fecal material. Computed tomography of the abdomen confirmed the important colon distension with fecal impaction (**Figure 1**). General surgery was consulted and the patient was sent to the operating room for urgent laparotomy. Upon opening of the abdomen, severe dilatation of entire colon from fecal impaction and bowel ischemia was confirmed. A complete colon resection and ileotomy was performed (**Figure 2**). The vasoactive support was completely weaned off post-operatively. Unfortunately, patient had severe anoxic brain injury secondary to his pulseless electrical activity cardiac arrest and died 3 days later.

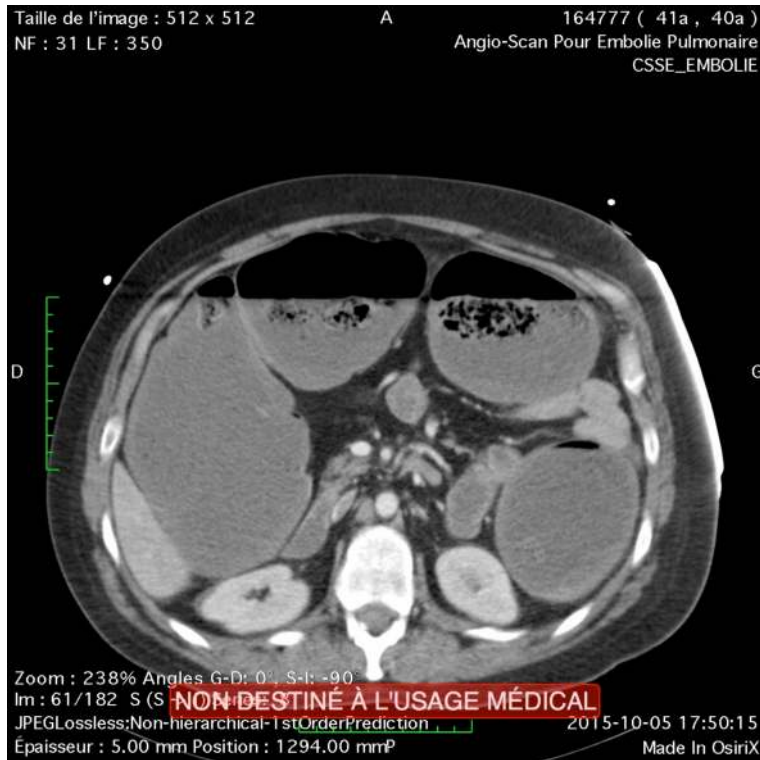
Discussion

Clozapine has been introduced in 1960 for the treatment of refractory schizophrenia. As potential catastrophic side effects, agranulocytosis and myocarditis have mostly been reported in the literature. Since 1995, clozapine-induced intestinal hypomotility has become more and more recognized. Constipation is a very common complication that occurs in 14%-60% of patients. (3) It is associated to the anticholinergic effect of clozapine. Chronic constipation can lead various degrees of intestinal

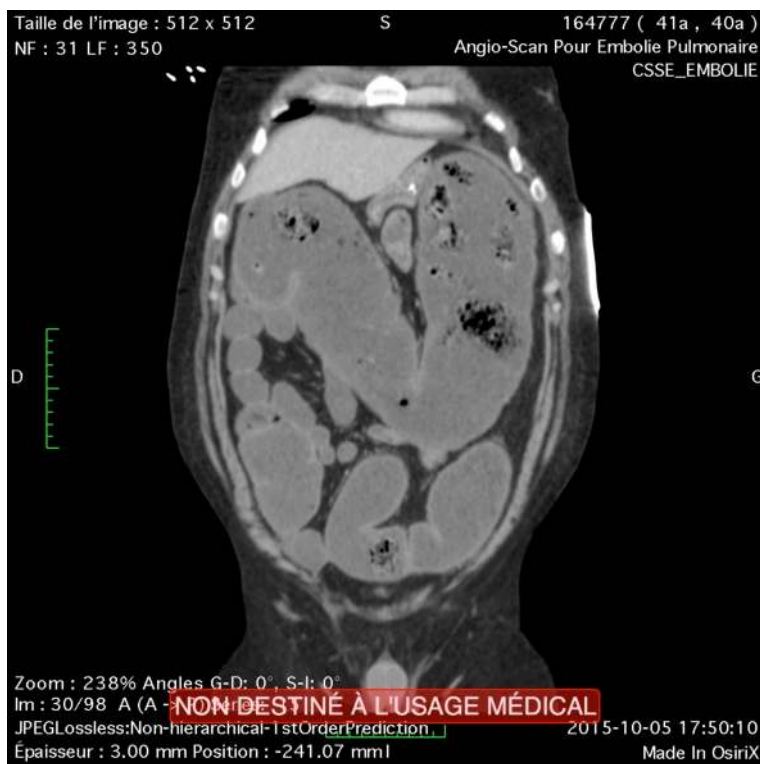
obstruction. In most cases, it can be easily treated with laxatives and enema. Bowel obstruction due to fecal impaction that required surgical treatment is extremely uncommon. However, in rare cases, it can be fatal. A review done by Palmer et al. showed 102 life-threatening cases of clozapine-induced gastrointestinal hypomotility. (4) The result is striking with 27.5% of mortality largely due to bowel ischemia and secondary septic shock with multiorgan failure. The most common complaints include abdominal pain, abdominal distension, nausea, vomiting, constipation and septic shock. Hibbard et al. reported 9 cases of fatalities associated with clozapine. (2) The main mechanism of death is being severe fecal impaction leading to pneumonia secondary to aspiration of feculent vomitus or bowel ischemia and necrosis. There is only one case report describing acute abdominal compartment syndrome related to clozapine-induced bowel obstruction. (5) In this case, patient presented with abdominal complaint with history of chronic constipation.

In contrast, our case had no history of abdominal symptoms and presented with respiratory discomfort, which in fact was related to lactic acidosis secondary to an early shock state from abdominal compartment syndrome. This unusual presentation made us believe that clozapine-induced bowel obstruction can sometime be missed if no attention is drawn to the potential abdominal complications related to this drug. In this patient it is possible that the psychiatric condition of the patients might have led the patient to unreport or unrecognized his abdominal symptoms. Therefore higher index of suspicion for such condition must be kept in mind when patients are taking these drugs and/or have limited mental ability to report key clinical symptoms given its high rate of mortality.

Figure 1. Transversal (A) and coronal view (B) of CT abdomen showing severe colon distension with fecal material impaction

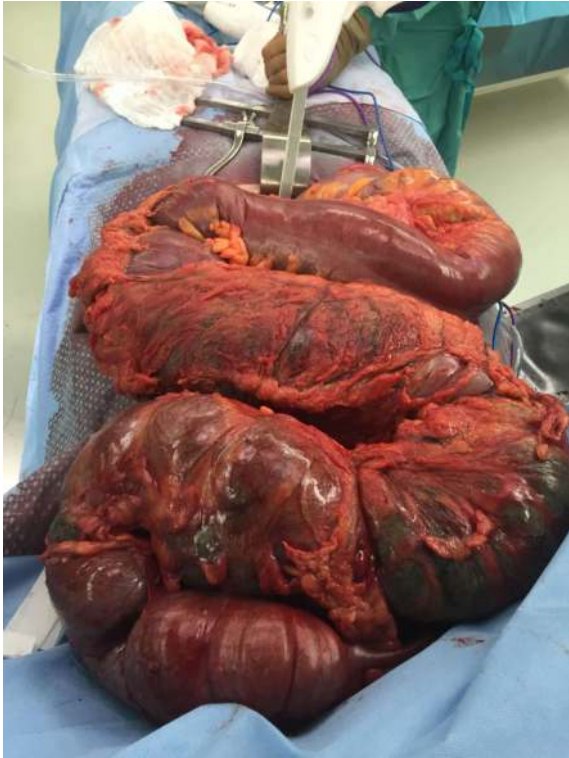

A



B

Figure 2. Complete colon resection showing diffuse and severe colon dilatation



Courtesy from Dr. C. Contant

References

1. Stahl SM. The Prescriber's Guide. Cambridge, UK: Cambridge University Press; 2005; p.95.
2. Hibbard KR, Propst A, Frank DE, Wyse J. Fatalities associated with clozapine-related constipation and bowel obstruction: a literature review and two case reports. *Psychosomatics* 2009;50:416
3. Levin TT, Barrett J, Mendelowitz A. Death from clozapine-induced constipation: case report and literature review. *Psychosomatics* 2002;43:71-3.
4. Palmer SE, McLean RM, Ellis PM, Harrison-Woolrych M. Life-Threatening Clozapine-Induced Gastrointestinal Hypomotility: An Analysis of 102 cases. *J Clin Psychiatry* 2008; 69:759-68.
5. Lavi E, Rivkin L, Carmon M, Reissman P. Clozapine-Induced Colonic Obstruction Requiring Surgical Treatment. *Isr Med Assoc J* 2009;11:385-6.