

Brain stem infarction as a complication of probable meningitis/encephalitis associated with COVID-19: A case report from Lombok, West Nusa Tenggara

Ilsa Hunai¹, Karina Anindita², Elya Endriani³, Sri Kartika Sari⁴, Ririn Setyawati⁵, Indah Widya Astuti⁶, Sandra Yuliana Andini Putri⁶, Zainul Muttaqin⁷

Abstract

Coronavirus disease 2019 (COVID-19), firstly discovered in Wuhan, China, has spread globally and was declared by the World Health Organization (WHO) as a pandemic since March 11, 2020. By June 13, 2020, the number of Covid cases in Indonesia was 37420 with 2091 mortality cases. Lombok is situated in the province of West Nusa Tenggara, currently the number of Covid-19 cases 937. We report a case of probable meningitis/encephalitis associated

with COVID-19 with symptoms of fever, headache, and cough. The patient was brought to the Emergency Room with decreased of consciousness, seizures, and neck rigidity. The thoracic examination and head computed tomography (CT) scan revealed pneumonia and brain stem infarction, respectively. Nasopharyngeal swab examination was performed and identified the presence of severe acute respiratory syndrome coronavirus 2 (SARS-CoV-2) ribonucleic acid (RNA) leading to meningitis due to COVID-19.

Key words: Meningitis/encephalitis, COVID-19, infarction, Lombok.

¹Department of Neurology Medical Faculty Mataram University, Mataram, West Nusa Tenggara.

²Department of Internal Medicine Siloam Hospital Mataram, Mataram, West Nusa Tenggara.

³Department of Intensive Care Siloam Hospital Mataram, Mataram, West Nusa Tenggara.

⁴Department of Clinical Pathology Siloam Hospital Mataram, Mataram, West Nusa Tenggara.

⁵Department of Radiology Siloam Hospital Mataram, Mataram, West Nusa Tenggara.

⁶Department of Emergency Siloam Hospital Mataram, Mataram, West Nusa Tenggara.

⁷Laboratory of West Nusa Tenggara General Hospital, Mataram, West Nusa Tenggara.

Address for correspondence:

Ilsa Hunai¹, MD
Medical Faculty Mataram University
Jalan Pendidikan 37 Mataram, West Nusa Tenggara, Indonesia
Tel: +62370 640874
Fax: +62370 641717
Email: ilsahunaifi@unram.ac.id

Introduction

Coronavirus disease 2019 (COVID-19) was first discovered in Wuhan, China in December 2019 and has spread globally. World Health Organization (WHO) declared it as a pandemic and the first case in Indonesia was discovered in early March 2020. (1) Data from The Ministry of Health of the Republic of Indonesia on June 13, 2020 shows that the virus has spread to all provinces in Indonesia with a total of 37,420 cases and 2,091 death. (2) In West Nusa Tenggara, the number of Covid-19 was 937 cases with 36 death. (3)

The central nervous system manifestations of coronavirus infection include dizziness, headache, acute cerebrovascular attack, loss of consciousness, changes in mental status, ataxia, convulsions, febrile seizures, meningitis, and encephalitis. (4-6) COVID-19 can spread to the central nervous system via the olfactory bulb, causing inflammation and demyelination. (5) The occurrence of meningitis/encephalitis due to COVID-19 has been

reported in Japan where severe acute respiratory syndrome coronavirus 2 (SARS-CoV-2) ribonucleic acid (RNA) was detected in cerebrospinal fluid. (7) However, there were several cases of suspected encephalitis due to Covid-19 presenting with seizures. (8) Until present no case of probable meningitis due to COVID-19 with brainstem infarction.

This case illustrates the manifestation of COVID-19 in the central nervous system and caused decreased of consciousness because of meningitis/encephalitis with brain stem infarction.

Case report

A 54-year-old male was brought to the Emergency Room with a decrease of consciousness three hours prior to hospitalization. He had slurred speech abruptly and acute mental changes. Two days before, he had a mild cough, fever, and headache.

According to physical examination, the Glasgow Coma Scale (GCS) 11, blood pressure 145/95 mmHg, pulse rate 105 beats per minute, respiratory rate 20 times per minute, temperature 37.1 °C, and oxygen saturation 94%. We found neck rigidity from neurological examination. The complete blood count showed leukocytosis with the neutrophil-lymphocyte ratio (NLR) 12.08. Chest X-ray showed cardiomegaly and pneumonia (**Figure 1**). Head computed tomography (CT) scans showed lacunar lesions with slight hypodensity in the brain stem (**Figure 2**).

The treatment in the Emergency Room was airway management with oxygenation therapy, nasogastric tube and Foley catheter placement. Empiric antibiotics were administered (ceftriaxone iv and levofloxacin iv). Furthermore steroids and hyponatremia correction therapy were given. The patient was later admitted to Intensive Care Unit with the initial diagnosis of meningitis/encephalitis, pneumonia, and hyponatremia.

Due to the present of pneumonia in this patient, therefore the patient was categorized as patient under monitoring of COVID-19 or as a suspect case of COVID-19. This was in accordance by the protocol from the Ministry of Health of the Republic of Indonesia. The examination to confirm the diagnosis was done through nasopharyngeal and oropharyngeal swabs.

The patient experienced a status generalized tonic-clonic seizure six hours after admission and was treated with status epilepticus protocol, which was diazepam (iv) and phenytoin (iv). After the seizure was resolved, the level of consciousness deteriorates into a coma with GCS 3 with impending respiratory failure. On the second day, the patient ex-

perienced a cardiac arrest and passed away. The specimen collection of cerebrospinal fluid could not be carried out due to the patient's medical condition in coma and had respiratory failure.

Specimen collection for COVID-19

Clinical specimens for COVID-19 diagnostic testing was carried out according to guidelines of National Institute of Health Research and Development, Ministry of Health of the Republic of Indonesia. Swab specimens from nasopharyngeal and oropharyngeal were collected with synthetic fiber swabs, where each swab was inserted into a separate sterile tube containing 1 ml of viral transport media (VTM). Specimens were immediately examined at the laboratory of West Nusa Tenggara General Hospital and Mataram General Hospital.

Diagnostic testing for COVID-19

Viral RNA was extracted from clinical specimen using Viral Nucleic Acid Extraction Kit II (Geneaid Co., Ltd.). Examination of nasopharyngeal and oropharyngeal swab specimens was carried out using two examination methods, respectively of the method from the hospitals where the samples were further analyzed.

The first method was carried out through the qualitative rapid method, real time reverse-transcriptase polymerase chain reaction (RT-PCR) using a disposable cartridge on the GeneExpert tool. This was a nucleic acid amplification test (NAAT) approach with the target N gene and E gene of the SARS-CoV-2 (this method was performed at Mataram City General Hospital Laboratory). The second method was performed by real time PCR using 2019-nCov Nucleic Acid Diagnostic Kit (Sansure Biotech) on 7500 FAST (Applied Biosystem) thermocycler. The diagnostic assay for SARS-CoV-2 targeted two gene which include ORF1ab and nucleicapsid N gene (this method was performed at Clinical Pathology Laboratory of West Nusa Tenggara General Hospital).

Result

The nasopharyngeal and oropharyngeal swab obtained from patient on day 1 after admission and day 2 before the patient passed away were positive for ORF1ab and N gene for SARS-CoV-2.

Discussion

This was a case of probable meningitis/encephalitis associated with COVID-19 accompanied by acute cerebrovascular complications characterized by an infarction on the brain stem. The diagnosis of meningoencephalitis in this case was made based on

the symptoms and the main clinical signs of decreased awareness and behavioral changes accompanied by two minor symptoms in the form of generalized seizures and the presence of neck rigidity. (9) Blood tests showed leukocytosis and RT-PCR from nasopharyngeal swabs detected positive for SARS-CoV-2 RNA. According to panel of provisional case definitions for the association of COVID-19 with neurological disease for meningitis/encephalitis due to SARS-CoV-2, this case was categorized as probable because SARS-CoV-2 was detected in the respiratory system or other, outside the central nervous system and no other pathogens was confirmed to be the source of infection. (10)

This case shows that COVID-19 can invade the central nervous system with marked signs of infection in brain tissue resulting in decreased of consciousness and seizures. Several theories of the COVID-19 mechanism may invade the central nervous system including the effects of direct infection, systemic circulation pathways, neuronal pathways, immune-mediated effects, and other mechanisms. (6)

COVID-19 can enter brain cells through retrograde and anterograde mechanisms mediated by the kinesins and dynein proteins through sensory nerve fibers and free nerve endings. COVID-19 may also invade the central nervous system through gastrointestinal system infections and spread to the central nervous system through the enteric nerves and afferent nerves. (6)

The entry of COVID-19 into the central nervous system will stimulate the innate immunity with polymorphonucleate (PMN), macrophage, and natural killer (NK) cell infiltration. A hyperactive immune response leading to great release of cytokines in the systemic circulation (cytokine storm syndrome), especially interleukin-6 produced by glial cells. In-vitro studies show activation of glia cells would result in chronic inflammation and brain cell damage due to the re-

lease of pro-inflammatory cytokines such as interleukin (IL) -6, IL-2, IL-5, IL-7, and tumor necrosis factor- α (TNF- α) resulting in organ failure. (6)

The presence of brain stem infarction on brain computed tomography (CT) scan shows complications from COVID-19 infection which results in acute cerebrovascular disorders (stroke). Mao and colleagues reported that 5.7% of patients with severe infections experienced cerebrovascular disorders. (4) The pathophysiology of stroke in COVID-19 patients may be caused by endothelial dysfunction due to viral binding to ACE 2 receptors resulting in damage and disorders of blood vessel autoregulation, coagulopathy, and inflammation and endogenous fibrinolysis. (4)

We consider this case is important because of COVID-19 infection that attacks the meninges and brain layers resulting in decreased of consciousness, even though a diagnosis of meningitis/encephalitis was obtained with clinical criteria. The presence of SARS-CoV-2 RNA was performed through nasopharyngeal swab and its present in the cerebrospinal fluid could not be examined due to the condition of the patient.

It is suspected that the COVID-19 infection in this case may be obtained from local transmission with minimal symptoms of the respiratory system. Global increase of COVID-19 infection makes coincidental occurrence of neurological disease is likely. However, cases of meningitis/encephalitis during the pandemic need to be suspected by COVID-19 as one of the causes and requires comprehensive and multidisciplinary treatment.

Conclusion

Meningitis/encephalitis associated with COVID-19 with complications of acute cerebrovascular attack with brain stem infarction is a rare case. Clinical findings, radiological tests, and detection of the presence of SARS-CoV-2 RNA in cerebrospinal fluid become essential in making the diagnosis.

Figure 1. Chest X-ray normal image (left) and reverse image (right) show reticular pattern and related with interstitial pneumonia and cardiomegaly

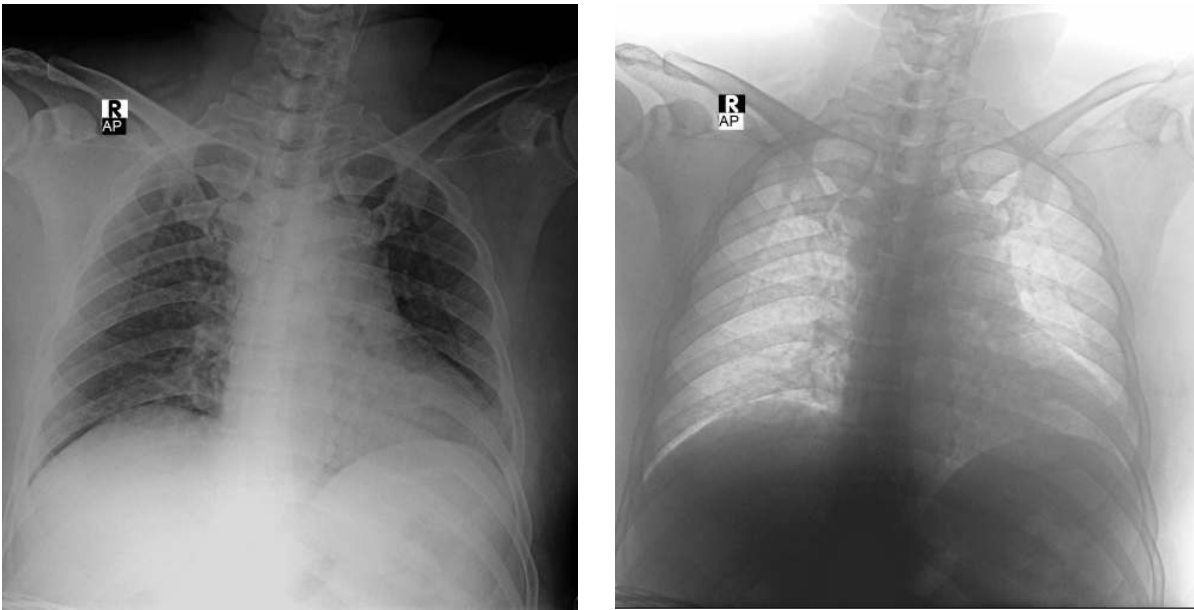
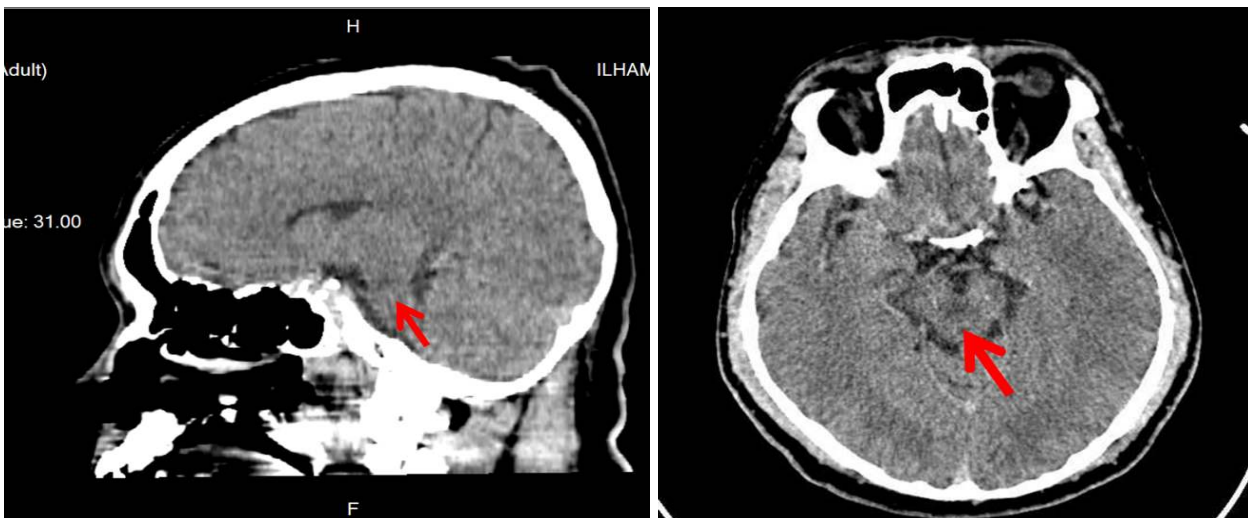


Figure 2. Brain computed tomography (CT) scan without contrast sagittal view (left) dan axial view (right) show hipodensity in brain stem (arrow) due to lacunar infarction in brain stem



References

1. World Health Organization. Coronavirus disease 2019 (COVID-19). Situation Report – 42 [Internet]. 2020 Mar 02 [cited 2020 Jun 24]. Available from: https://www.who.int/docs/default-source/coronaviruse/situation-reports/20200302-sitrep-42-covid-19.pdf?sfvrsn=224c1add_2
2. Kementerian Kesehatan RI. Situasi Terkini Perkembangan Novel Coronavirus (COVID-19). Jakarta: Kementerian Kesehatan RI; 2020.
3. Sekretaris Daerah Provinsi Nusa Tenggara Barat. Press Release. Mataram: Sekretariat Daerah Provinsi Nusa Tenggara Barat; 5 p.
4. Mao L, Jin H, Wang M, Hu Y, Chen S, He Q, et al. Neurologic Manifestations of Hospitalized Patients with Coronavirus Disease 2019 in Wuhan, China. *JAMA Neurol* 2020;77:683-90.
5. Asadi-Pooya AA, Simani L. Central nervous system manifestations of COVID-19: A systematic review. *J Neurol Sci* 2020;413:116832.
6. Ahmed MU, Hanif M, Ali MJ, Haider MA, Kherani D, Memon GM, et al. Neurological Manifestations of COVID-19 (SARS-CoV-2): A Review. *Front Neurol* 2020;11:1-9.
7. Moriguchi T, Harii N, Goto J, Harada D, Sugawara H, Takamino J, et al. A first case of meningitis/encephalitis associated with SARS-Coronavirus-2. *Int J Infect Dis* 2020;94:55-8.
8. Sohal S, Mansur M. COVID-19 Presenting with Seizures. *IDCases* 2020;20:e00782.
9. Halperin JJ. Diagnosis and management of acute encephalitis. *Handb Clin Neurol* 2017;140:337-47.
10. Ellul MA, Benjamin L, Singh B, Lant S, Michael BD, Easton A, et al. Neurological associations of COVID-19. *Lancet Neurol* 2020;19:767-83.