

Gastromegaly as the cause of unexplained chest pain

Laura Bernardo, Gary M. Idelchik, Joseph Varon

A 61-year-old gentleman with past medical history of hypertension, hyperlipidemia, gastroesophageal reflux status post hiatal hernia repair in 1973, and recurrent diverticulitis was admitted to the intensive care unit (ICU) after undergoing elective laparoscopic rectosigmoid hemicolectomy and colostomy formation. His immediate postoperative course was complicated by syncope while getting out of bed to ambulate. The patient regained consciousness within minutes and noted severe substernal chest pressure and dyspnea at rest. Physical examination revealed a blood pressure of 70/40 torr, heart rate 130/min and respiratory rate 28/min. Chest examination was unremarkable. Mild abdominal distension was noted without discomfort to palpation, and diffuse tympani on percussion. An emergent electrocardiogram was unremarkable. The patient received intravenous fluids and vasopressors. Laboratory testing revealed acute blood loss anemia

with drop in baseline hemoglobin of four grams per deciliter. Following stabilization while awaiting blood transfusion, a chest X-ray was performed demonstrating severe gastromegaly, which was then confirmed by abdominal X-ray (**Figures 1 and 2**). Subsequent abdominal and pelvic computed tomography (CT) with contrast to assess for obstruction, confirmed the presence of gastromegaly without obstruction, and left lower quadrant hematoma without active bleeding (**Figure 3**). A nasogastric tube on continuous suction was inserted with subsequent resolution of the patient's symptoms as well as the objective findings of hypotension, tachycardia, and tachypnea. A repeat radiograph revealed decompression of the patient's stomach (**Figure 4**). Pressor support was weaned, and after completion of the patient's blood transfusion, stopped. The patient had no further complications post-operatively and discharged home on post-operative day 2.

Key words: Gastromegaly, chest pain, chest radiograph, imaging studies, ileus.

From Department of Critical Care Services, University General Hospital, Houston, Texas, USA (Laura Bernardo, Gary M. Idelchik), Department of Critical Care Services, University General Hospital, and The University of Texas Medical Branch, Houston, Texas, USA (Joseph Varon).

Address for correspondence:

Joseph Varon, MD, FACP, FCCP, FCCM, FRSM
2219 Dorrington Street
Houston, Texas 77030, USA
Tel: +1-713-669-1670
Fax: +1-713-669-1671
Email: Joseph.Varon@uth.tmc.edu

Figure 1. Initial chest X-ray demonstrating gastromegaly

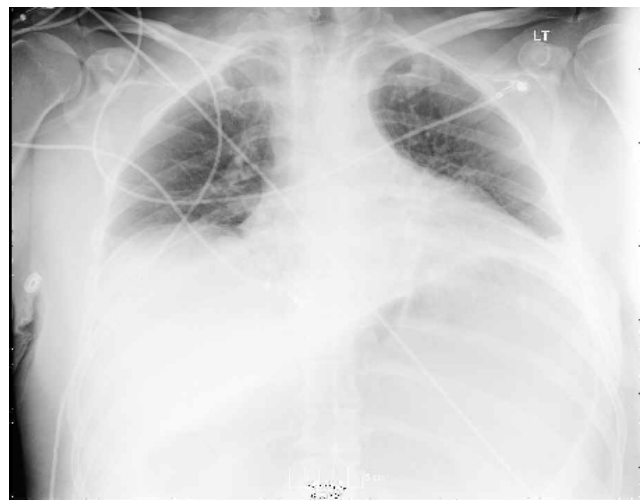


Figure 2. Initial abdominal X-ray demonstrating gastromegaly

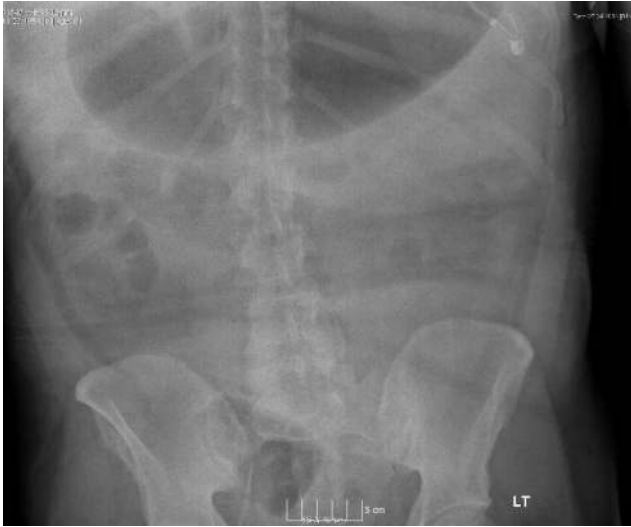

Figure 4. Follow-up chest X-ray following decompression with a nasogastric tube and continuous suction

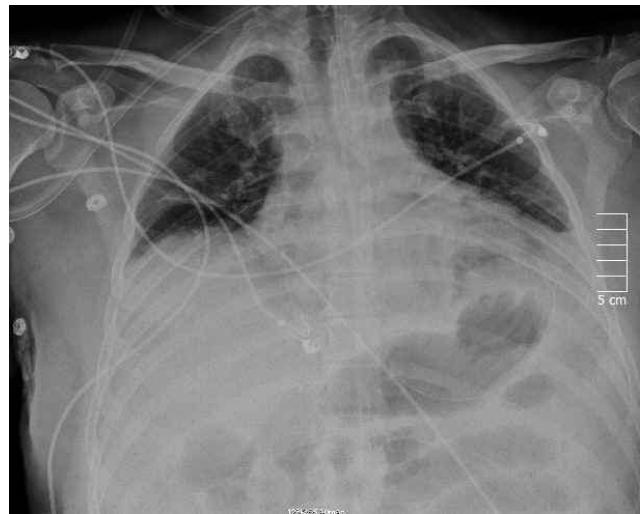

Figure 3. Abdominopelvic computed tomography (CT) confirming the presence of gastromegaly without distal small bowel obstruction

