

# Unilateral Diaphragmatic Pacing: An Innovative Solution for Unilateral Diaphragmatic Paralysis

Salim R. Surani, Atif Afzal, Eva Elizabeth Ayala, Joseph Varon

## Abstract

**Mechanical ventilation has always been a cornerstone of respiratory support for patients with respiratory muscle paralysis. In selected patients, diaphragm pacing (DP) through electrical stimulation of the phrenic nerves provides an**

**alternative to mechanical ventilation with significant advantages in life quality. We report an interesting case of unilateral diaphragmatic paralysis in which unilateral diaphragmatic pacing produced significant improvement in quality of life.**

Respiratory muscle paralysis can be deadly if not treated promptly. Several approaches exist to the management of this condition. Diaphragmatic pacing (DP) may be a reasonable alternative in the management of these patients. We recently had such a case.

to her compromised respiratory status.

The patient past medical history was significant for reactive airway disease, thyroidectomy, hysterectomy, and left foot surgery. She had no history of trauma or infection involving the neck or chest. Physical exam was significant for decreased breath sounds at the right lung base. Both first and second heart sounds were audible with no added heart sounds. The neurological exam was also normal with normal muscle strength and tone in all four extremities. Laboratory testing revealed a hemoglobin of 12.2 g/dl, hematocrit of 36.1%, and platelet count of 414,000/mm<sup>3</sup> and a white blood cell count of 10.2/mm<sup>3</sup>. The computed tomography (CT) scan showed an atelectasis of the right lung base and fluoroscopy was done, which confirmed right hemi-diaphragm paralysis. This was followed by a nerve conduction study and electromyography of both phrenic nerves. On nerve conduction study the right phrenic nerve did not respond to transcutaneous stimulation. Afterwards, the patient underwent a successful placement of a right diaphragmatic pacemaker. Her symptoms rapidly abated.

## Case Report

A 60 year-old Caucasian female presented with complaints of progressively worsening shortening of breath for three months. The dyspnea was insidious in onset and progressive. Her dyspnea on exertion was only few feet. The patient had a history of stage 1 breast cancer of the right breast, which was treated by modified radical mastectomy, followed by tamoxifen therapy for a few years. Her course was complicated by a diagnosis of multiple myeloma, after she presented with complaints of back pain. Thereafter, she underwent palliative radiation therapy and chemotherapy with poor response. She was not felt to be a candidate for stem cell transplantation due

---

From Texas A&M University, Corpus Christi, Texas, USA (Dr. Salim R. Surani), Aga Khan University, Karachi, Pakistan (Dr. Atif Afzal), University of North Texas Health Science Center-Texas College of Osteopathic Medicine, Fort Worth, Texas, USA (Eva Elizabeth Ayala), and The University of Texas Health Science Center at Houston, Texas, USA (Dr. Joseph Varon)

### Address for correspondence:

Salim Surani, MD  
613 Elizabeth Street, Suite 813  
Corpus Christi, Texas 78404  
Email: srsurani@hotmail.com

## Discussion

Diaphragmatic pacing, also known as electrophrenic respiration, phrenic pacing or electrophrenic nerve pacing, is the stimulation of the phrenic nerves with electrical current via an implanted pacemaker which results in the muscle contraction

of the diaphragm. The first idea about producing diaphragmatic contractions via stimulation of the phrenic nerves dates back over 200 years ago [1]. Waud reported in 1937 that rhythmic electrical stimulation of the phrenic nerves effects respiration [2]. In 1948, Sarnoff and his associates demonstrated that adequate ventilation could be obtained by unilateral stimulation of the phrenic nerve [3]. Dr. William Glenn pioneered the technique of diaphragmatic pacing in 1968, by successfully implanting a system to electrically stimulate the phrenic nerve [4]. Glenn adapted the implanted system for long term use in patients with central hypoventilation [5]. A few years later, in 1970, Glenn implanted a bilateral diaphragm pacemaker in a high tetraplegic patient [6].

Implanting a diaphragmatic pacer requires the surgical placement of an electrode into the phrenic nerve and it is connected to a subcutaneous receiver. When the external battery-operated transmitter and antenna emits energy, it is converted into an electrical current by the receiver, which stimulates the phrenic nerve thus causing a diaphragmatic contraction [7]. An intact phrenic nerve is necessary as it acts as the conduit for the applied stimulus [8]. Patients who have damage to the spinal cord at C<sub>3</sub>-C<sub>5</sub> or have a direct injury to the phrenic nerve are not candidates for diaphragmatic pacing [9].

Diaphragmatic pacing has provided an alternative to mechanical ventilation. It has provided ventilatory support in patients with central alveolar hypoventilation and quadriplegia, particularly those with C<sub>1</sub> or C<sub>2</sub> lesions [8]. Phrenic pacing has also been considered for patients with bulbar poliomyelitis and other central nervous system lesions involving the respiratory center, narcotic poisoning, and chronic emphysema and to assist respirations in the postoperative period [10]. Phrenic pacers have commonly been for patients with bilateral non-functioning diaphragms. Currently, for patients who have only unilateral phrenic nerve function, a unilateral diaphragmatic pacer has now

been developed [11]. Breathing pacemakers have also been used to treat patients with phrenic nerve damage, like it was done in our patient [12].

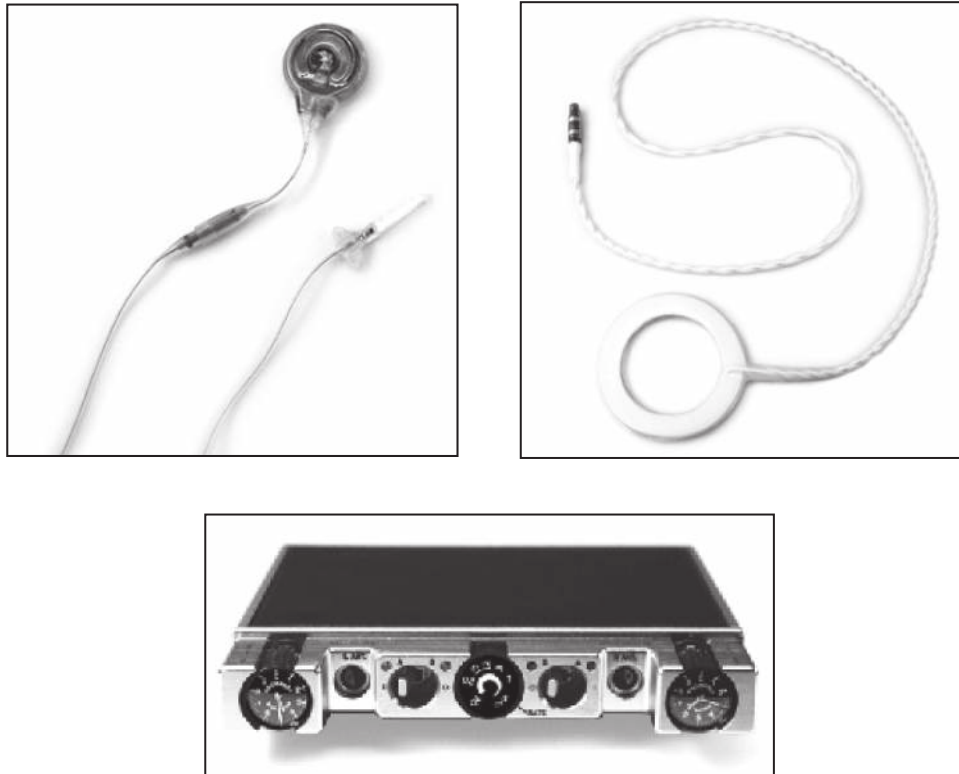
## Equipment Necessary

The implanted receiver is a small electronic device, about the size of a US quarter coin and approximately 1/4" thick, which receives radiofrequency energy and converts it to electrical impulses which stimulate the diaphragm. The implanted electrode is a highly flexible stainless steel wire, insulated by silicone rubber, with a platinum nerve contact on one end, and a connector that mates with the receiver at the other. An external antenna is worn over each implanted receiver and sends power and radio signals from the transmitter to the receiver transcutaneously. This radiofrequency coupled design means that there are no wires or plugs protruding from the skin, and no batteries in the implant that would require periodic replacement. An antenna is a durable disposable item which requires periodic replacement (**Figure 1**). It is recommended that antennas be replaced prophylactically every six months. The Transtelephonic Monitoring (TTM) data transmitter can provide quantitative data for routine and diagnostic monitoring of the external and implanted diaphragm pacing equipment as well as the patient's physiological response to stimulation.

## Conclusions

There are only a few reported cases of unilateral diaphragmatic pacing. It has been observed that unilateral pacing is normally possible with computer stimulus optimization, but it is only recommended for patients who have suffered irreversible injury of the phrenic nerve. This was the case in the patient mentioned in this case report. Our patient became fully functional after the pacemaker was inserted. Since her pacemaker was inserted, her dyspnea has resolved and she can now walk long distances without dyspnea.

**Figure 1. RECEIVER, ANTENNA AND TRANSMITTER**



## References:

1. nic respiration. *Ann Surg* 172:755-773 Fodstand H (1989) Pacing of the diaphragm to control breathing in patients with paralysis of central nervous system origin. *Stereotact Funct Neurosurg* 53: 209-222
2. Glenn WW, Holcomb WG, Gee JB, Rath R (1970) Central hypoventilation; long-term ventilatory assistance by radiofrequency electrophrenic respiration. *Ann Surg* 172:755-773 Fodstand H (1989) Pacing of the diaphragm to control breathing in patients with paralysis of central nervous system origin. *Stereotact Funct Neurosurg* 53: 209-222
3. Bach JR, O'Connor K (1991) Electrophrenic ventilation: a different perspective. *J Am Paraplegia Soc* 14: 9-17
4. Morgan JA, Morales DL, John R, Ginsburg ME, Kherani AR, Vigilance DW, Cheema FH, Smith CR, Oz MC, Argenziano M (2003) Endoscopic, robotically assisted implantation of phrenic pacemakers. *J Thorac Cardiovasc Surg* 126:582-583
5. Tibballs J (1991) Diaphragmatic Pacing: An alternative to long-term mechanical ventilation. *Anaesth Intensive Care* 19:597-601
6. Vanderlinden RG, Epstein SW, Hyland RH, Smythe HS, Vanderlinden LD (1988) Management of chronic ventilatory insufficiency with electrical diaphragm pacing. *Can J Neurol Sci* 15:63-67
7. Chen ML, Tablizo MA, Kun S, Keens TG (2005) Diaphragm pacers as a treatment for congenital central hypoventilation syndrome. *Expert Rev Med Devices* 2:577-585
8. Kreiger AJ, Gropper MR, Adler RJ (1994) Electrophrenic respiration after intercostal to phrenic nerve anastomosis in a patient with anterior spinal artery syndrome: technical case report. *Neurosurgery* 35:760-764
9. Kreiger LM, Kreiger AJ (2000) The intercostal to phrenic nerve transfer: An effective means of reanimating the diaphragm in patients with high cervical spine injury. *Plas Reconstr Surg* 105:1255-1261
10. Anagnostopoulos CE, Glenn WW (1966) Electronic pacemakers of the heart, gastrointestinal tract, phrenic nerve, bladder, and carotid sinus: current status. *Surgery* 60:480-494
11. DiMarco AF, Onders RP, Ignagni A, Kowalski KE (2006) Inspiratory muscle pacing in spinal cord injury: case report and clinical commentary. *J Spinal Cord Med* 29:95-108
12. Dobbelle WH, D'Angelo MS, Goetz BF, Kiefer DG, Lallier TJ, Lamb JJ, Yazwinsky JS (1994) 200 cases with a new breathing pacemaker dispel myths about diaphragm pacing. *ASAIO J* 40:M244-M252