

Portal venous gas entrapment secondary to mesenteric ischemia after withdrawal of intra-aortic balloon pump: A case report with a rare ultrasound image

Ying Tung Sia, Pierre Laurencelle

Abstract

After coronary artery bypass graft (CABG), mesenteric ischemia is a rare but dreadful complication with high mortality rates. Prophylactic use of intra-aortic balloon pump (IABP) is a common practice in patients with severe coronary artery disease awaiting CABG. During withdrawal of the IABP, there is a risk of dislodging atheromatous debris, thus causing peripheral and mesenteric emboli, which can cause mesenteric ischemia. Here we are reporting on a case where a patient had an IABP installed after a ST-elevation myocardial infarction (STEMI) while awaiting CABG surgery.

After surgery, the IABP was eventually removed, but rising lactates led to further investigation. The abdominal computerized tomography (CT) scan showed extensive bowel pneumatosis and portal venous gas entrapment. The patient died despite aggressive non-surgical management. This case shows a fatal complication of IABP use in a high-risk patient undergoing CABG surgery and highlights the need for careful aorta and peripheral vascular assessment prior to IABP device insertion to avoid intestinal compromise.

Key words: Intra-aortic balloon pump, portal venous gas, mesenteric ischemia, ultrasound.

Learning objective

Prophylactic intra-aortic balloon pump (IABP) insertion in patients with left main disease is still a common practice for most interventional cardiologists. However, IABP carries a non-negligible risk of complication in such patients, including thromboembolic events, vessel obstruction and dissection. It is important to realize the extent of its possible complications.

Introduction

After coronary artery bypass graft (CABG), acute mesenteric ischemia is a rare but dreadful complication with mortality rates higher than 70%. (1,2)

Prophylactic use of IABP is a common practice in patients with severe coronary artery disease awaiting CABG and it has been shown to reduce perioperative mortality in high-risk patients undergoing cardiac surgery. (3) Aortic atheromatous and peripheral vascular diseases are associated with an increased risk of limb and bowel ischemia with IABP. (4) During withdrawal of the IABP, there is a risk of dislodging atheromatous debris, thus causing peripheral and mesenteric emboli. Furthermore, malpositioning of the IABP has been shown to compromise visceral perfusion. (5) Here, we are reporting a case of bowel ischemia following IABP withdrawal in a patient undergoing CABG in a context of ST-elevation myocardial infarction (STEMI).

Case report

An 85-year-old Caucasian male presented with retrosternal pain relieved by nitroglycerin. The patient had a past medical history of hypertension, dyslipidemia, type II diabetes, severe chronic obstructive pulmonary disease (COPD) and coronary artery disease.

The patient suffered a hemodynamically significant STEMI and had an IABP installed. Corona-

From Montreal Cardiology Institute, Montreal, Canada (Ying Tung Sia) and University of Montreal, Montreal, Canada (Pierre Laurencelle).

Address for correspondence:

Pierre Laurencelle, MD
5135 pl. Louis-Riel, Montreal, QC, Canada, H1M2A4
Tel: 514-267-5301
Email: pierrelaurencelle@gmail.com

rography showed extensive triple vessel disease, which needed surgical revascularization. Post operatively, the patient was stable and required low doses of vasopressors to maintain a mean arterial pressure (MAP) of 65 mmHg. On post op day 2, vasopressors were weaned and the IABP was removed. Soon after IABP removal, lactates started to climb. The patient became vasoplegic once again, with high vasopressor requirements. The abdominal computerized tomography (CT) scan was performed and showed extensive bowel pneumatosis (**Figure 1**) and portal venous gas entrapment (**Figure 2**), suggestive of significant mesenteric ischemia. Trans abdominal ultrasound showed images of gas moving through the portal venous circulation (**Movie 1**). Despite aggressive treatment, the patient continued to deteriorate to multi-organ failure. The patient died in the ICU on the fourth day after surgery.

Discussion

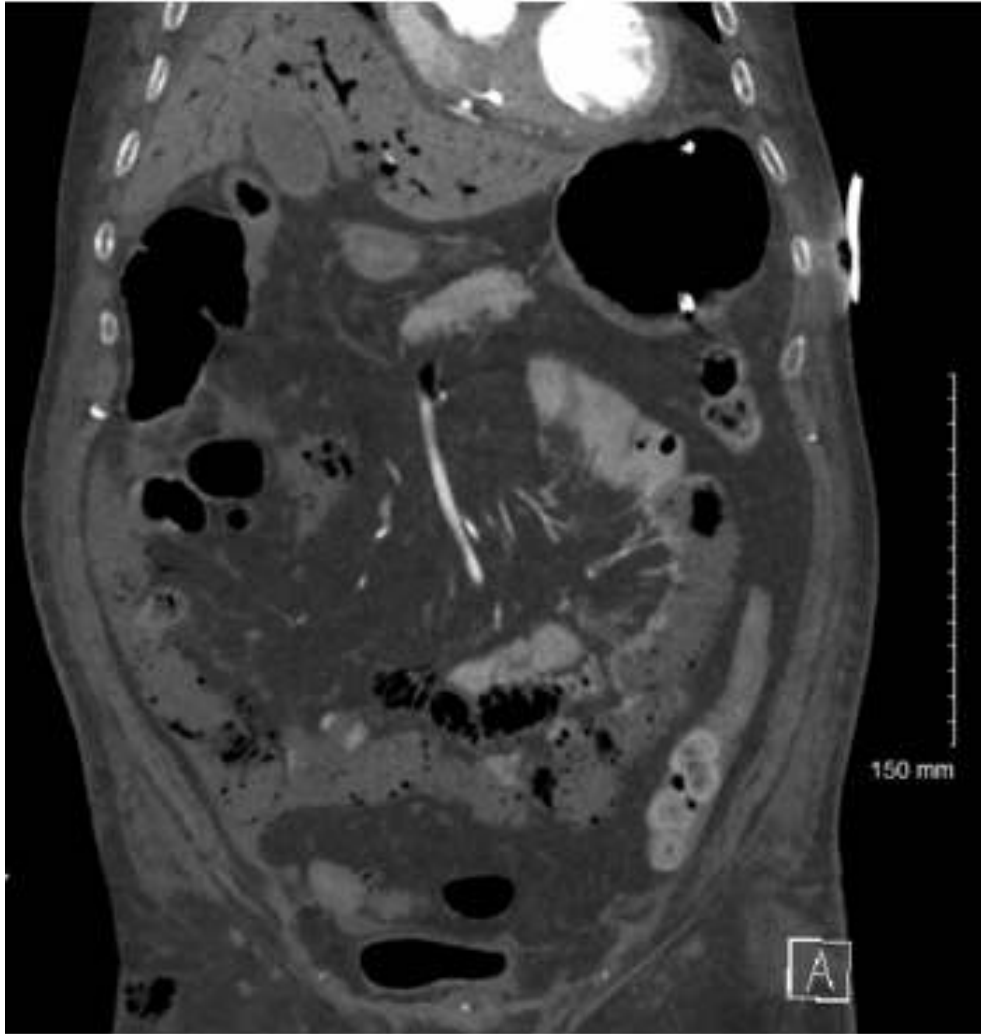
Despite the negative result from the IAPB-shock II trial, (6) IABP continues to be used in patients with cardiogenic shock. Furthermore, prophylactic IABP insertion in patients with left main disease is

still a common practice for most interventional cardiologists. However, IABP carries a non-negligible risk of complication in such patients, including thromboembolic events, vessel obstruction and dissection. Moreover, correctly positioned IABP devices according to the traditional left subclavian artery landmark have been shown in some cases to cover the celiac trunk and superior mesenteric artery during balloon inflation. (7,8) This case represents a rare but fatal complication related to mesenteric ischemia. During withdrawal of the IABP, atheromatous debris can be dislodged and cause peripheral emboli and ischemia. The abdominal CT scan showed extensive intestinal pneumatosis and the presence of air in the portal venous system. Interestingly, the air was identified by ultrasound, showing continuous airflow in the portal vein. This case highlights the need for careful aorta and peripheral vascular assessment prior to IABP device insertion to avoid intestinal compromise.

Acknowledgment

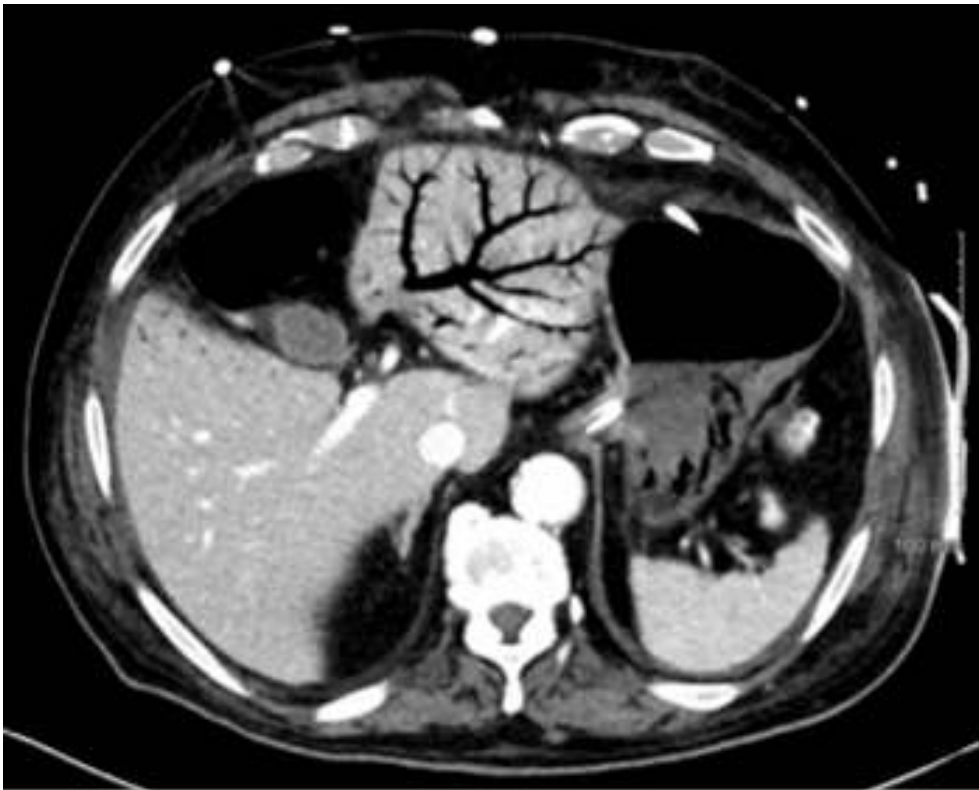
The authors declare that there is no conflict of interest.

Figure 1. CT image revealing pneumatosis, portal venous gas and a linearly delimited difference in mesenteric contrast expression suggestive of inadequate perfusion



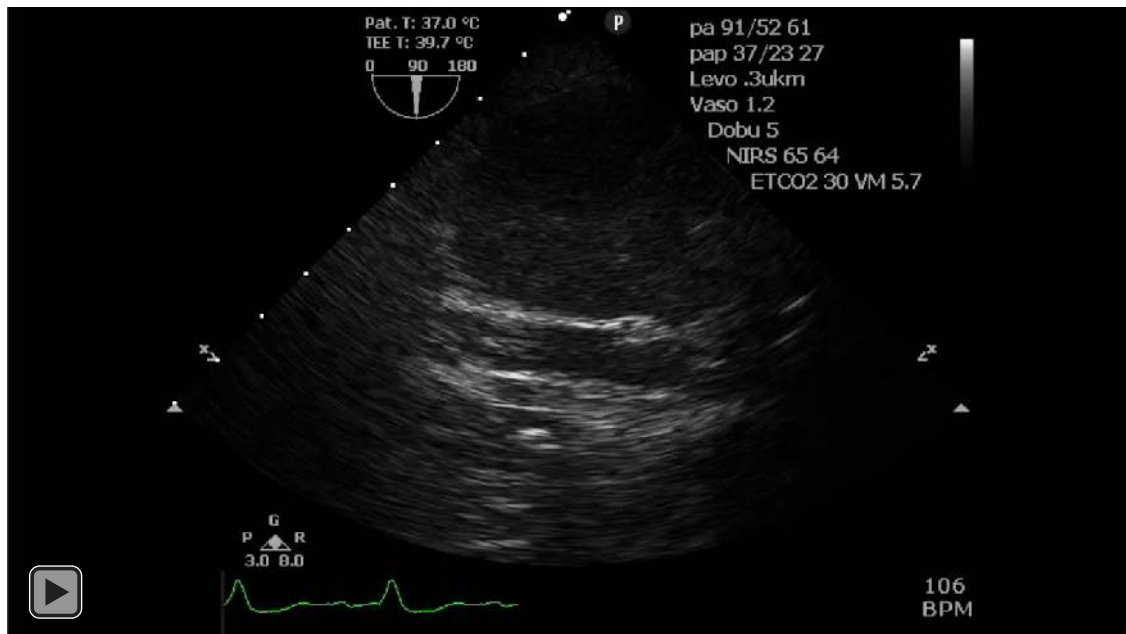
Legend: CT=computerized tomography.

Figure 2. CT image revealing portal venous gas entrapment



Legend: CT=computerized tomography.

Movie 1. Trans abdominal ultrasound image showing portal venous gas flow



References

1. Schütz A, Eichinger W, Breuer M, Gansera B, Kemkes BM. Acute mesenteric ischemia after open heart surgery. *Angiology* 1998;49:267-73.
2. Pang PY, Sin YK, Lim CH, Su JW, Chua YL. Outcome and survival analysis of intestinal ischaemia following cardiac surgery. *Interact Cardiovasc Thorac Surg* 2012;15:215-8.
3. Zangrillo A, Pappalardo F, Dossi R, Di Prima AL, Sassone ME, Greco T, et al. Preoperative intra-aortic balloon pump to reduce mortality in coronary artery bypass graft: a meta-analysis of randomized controlled trials. *Crit Care* 2015;19:10.
4. Arafa OE, Pedersen TH, Svennevig JL, Fosse E, Geiran OR. Vascular complications of the intraaortic balloon pump in patients undergoing open heart operations: 15-year experience. *Ann Thorac Surg* 1999;67:645-51.
5. Vondran M, Rastan AJ, Tillmann E, Seeburger J, Schröter T, Dhein S, et al. Intra-Aortic Balloon Pump Malposition Reduces Visceral Artery Perfusion in an Acute Animal Model. *Artif Organs* 2016;40:334-40.
6. Thiele H, Zeymer U, Neumann FJ, Ferenc M, Olbrich HG, Hausleiter J, et al. Intraaortic balloon support for myocardial infarction with cardiogenic shock. *N Engl J Med* 2012;367:2187-96.
7. Abboud B, Daher R, Boujaoude J. Acute mesenteric ischemia after cardio-pulmonary bypass surgery. *World J Gastroenterol* 2008;14:5361-70.
8. Sukhodolya T, Damjanovic D, Beyersdorf F, Benk C, Heilmann C, Blanke P, et al. Standard Intra-Aortic Counterpulsation Balloon May Cause Temporary Occlusion of Mesenterial and Renal Arteries. *ASAIO J* 2013;59:593-9.