

# Obstructive and severe septic shock following a ruptured mature mediastinal teratoma

*Jun-ichi Hirata, Munehiko Ohya, Seishiro Marukawa, Keiji Kumon*

## Abstract

Most mature mediastinal teratomas are not symptomatic until they rupture, and the mechanisms underlying their rupture remain controversial. A 40-year-old woman was admitted to the emergency room with increasing respiratory distress 24 h before admission. Her clinical examination results indicated systemic inflammatory response syndrome with jugular venous distension and bilateral pitting edema on her lower extremity. Thoracic computed tomography confirmed a well-defined anterior mediastinal giant heterogenous mass (22 x 17 x 15

cm) with fluid content that had the same density of pleural effusion. In the culture examination of both sputum and pleural effusion, *Streptococcus pneumoniae* was detected. Surgical findings showed that the tumor contained sebaceous material with some hair and teeth. No teratoma-pulmonary fistula was detected, but oozing through the thin and fragile microscopic hole on the tumor wall was observed. We describe a rare case of a patient with both obstructive and severe septic shock following a ruptured teratoma.

**Key words:** Obstructive shock, severe septic shock, mature mediastinal teratoma.

## Introduction

Most mediastinal teratomas are usually asymptomatic until they rupture into adjacent organs. (1) However, the diagnosis of a mediastinal teratoma is difficult even after its rupture, since the signs and symptoms vary with regard to the ruptured site, which can include the lung, pleural space, pericardial space, and bronchial tree. (2) Furthermore, when the fluids from the ruptured teratomas leak into the pleural sites of adjacent organs, the associated pathophysiological compounds may result in persistent inflammation, causing systemic inflammatory response syndrome and multiple organ dysfunction. However, the mechanisms underlying the

rupture of mediastinal teratomas remain controversial and include autolysis resulting from secreted proteolytic or digestive enzymes (e.g., amylase); ischemia resulting in rapid enlargement; and infection caused by pulmonary, hematologic, and teratoma-pulmonary fistulas. (3)

Here, we report a very rare case of both obstructive and severe septic shock that developed after a mature mediastinal teratoma ruptured, likely due to infection and ischemic changes during its rapid growth.

## Case presentation

A 40-year-old woman was admitted to the emergency room because of severe weakness, chills, shortness of breath, cough, yellow-green sputum, mild hemoptysis, severe pleuritic chest pain and back pain, and orthopnea that had started 24 h earlier. Her past medical history included a mediastinal tumor that had not been treated at a hospital for the last 10 years, even though surgery had been recommended for excision of the

---

From Department of Emergency and Critical Care Medicine, Kinki University Faculty of Medicine, Nara Hospital, Nara, Japan (Jun-ichi Hirata, Munehiko Ohya, and Keiji Kumon).

### Address for correspondence:

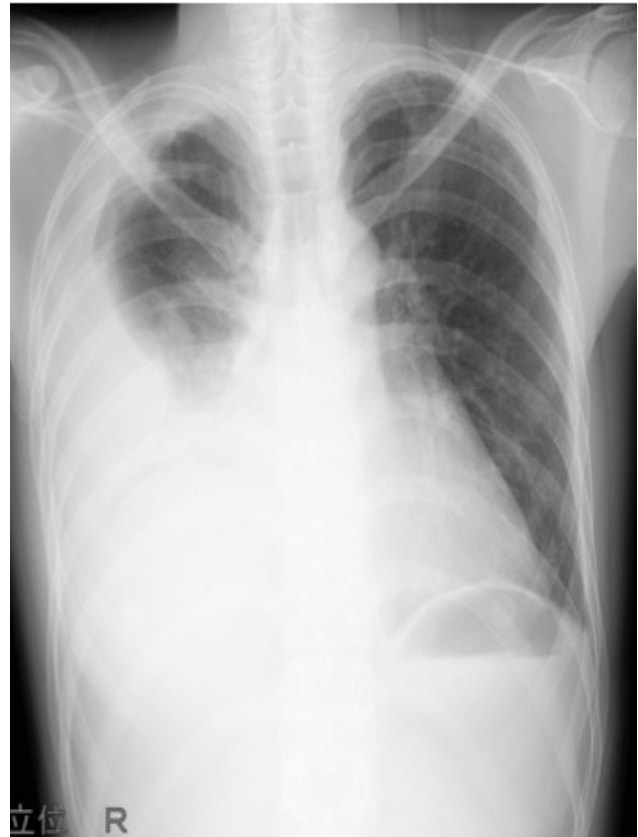
Jun-ichi Hirata  
Department of Emergency and Critical Care Medicine  
Kinki University Faculty of Medicine, Nara Hospital  
1-1248, Otsuda, Ikoma, 630-0293 Nara, Japan  
Tel: +81-743-77-0880  
Fax: +81-743-77-0890  
Email: qq-hira@i.softbank.jp and qq-hira@hyo-med.ac.jp

tumor. However, she was afraid of undergoing surgery and thereafter she has been generally tired. On her arrival at the emergency room, the results of her clinical examination confirmed hypotension (blood pressure, 82/61 mmHg), tachycardia (107 beats/min), and fever (temperature 38.5°C). Her breathing was labored in a lateral recumbent position, and her peripheral oxygen saturation in room air was 89%. A chest examination revealed jugular venous distension and her respiratory murmur decreased on the right side. She had bilateral pitting edema on her lower extremity. Findings of her thyroid, lymph node, abdominal, and gynecological examinations were normal.

An arterial blood gas test performed with the patient breathing room air showed acidemia (pH 7.1), a partial pressure of carbon dioxide of 48 mmHg, a low partial pressure of oxygen of 64 mmHg, and a low base excess of -1.6. Laboratory findings showed leukocytosis (23,600/mm<sup>3</sup>, with 91% neutrophils) and elevated serum C-reactive protein (9.13 mg/dL) and amylase (375 U/L) levels. The serum tumor markers carcinoembryonic antigen and alfa-fetoprotein, and the betasubunit of human chorionic gonadotropin were all at normal levels. Streptococcus pneumonia was detected in the examination of her sputum. Simple thoracic radiography suggested alveolar lung disease in the right middle and lower lung lobes with pleural effusion (**Figure 1a**). Thoracic computed tomography (CT) confirmed the presence of a well-defined anterior mediastinal giant mass (22x17x15 cm) extending to the right hemithorax that was composed of several large cystic spaces and a small, high-density area of soft tissue with pleural effusion (**Figure 1b**). In addition, Streptococcus pneumonia was detected in the cultures of aspirated pleural effusion. The tumor margin varied from smooth to irregular and involved adjacent lung consolidation. There was no difference in density between pleural effusion and the tumor contents. Moreover, the tumor caused extrinsic compression of the right atrium and occupied the anterior mediastinal space (**Figure 1b**). Right ventricular compression was observed and a left ventricle ejection fraction of approximately 58-60% was measured by echocardiography. Based on these findings, we suspected that the patient had both obstructive and severe septic shock caused by a ruptured mature mediastinal teratoma, resulting in a lung abscess.

The following differential diagnosis for the anterior mediastinum tumor was considered: thymic tumor such as thymoma, thymic carcinoma, thymic cartinoid, thymic cyst; germ-cell tumor such as immature teratoma,

**Figure 1a.** Thoracic radiography on admission

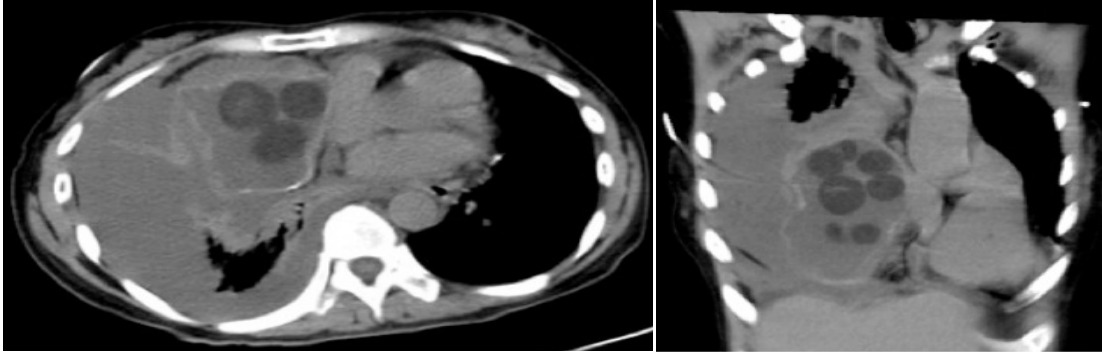


**Legend:** Simple thoracic radiography suggested alveolar lung disease in the right middle and lower lung lobes with pleural effusion.

seminoma, embryonal cartinoma, yolk sac tumor, and choriocarcinoma; and lymphoid malignancy.

The patient was administered intravenous ampicillin as an empiric treatment. Subsequently, median sternotomy was performed, and the tumor mass was tightly adhered to the medial surface, with consolidation and abscess formation (1750 mL) in the anterior upper lobe segments. Therefore, tumorectomy was successfully performed with curettage. Gross examination indicated a rounded tumor measuring 19.0x17.0x8.0 cm, which contained sebaceous material with some hair and teeth (**Figure 2**). The amylase level of 390 U/L in the pleural effusion was higher than its level of 375 U/L in the serum. Microscopically, the cystic lesion was lined by skin (columnar epithelium cells) and cartilaginous islands. An apparent fistula between the teratoma and the pulmonary lining layer, which had been suspected based on the presence of pneumonia, was not detected. However, a thin and fragile microscopic hole in the tumor wall, from which fluids in the teratoma were fluently oozing into the pleural cavity, was formed. On

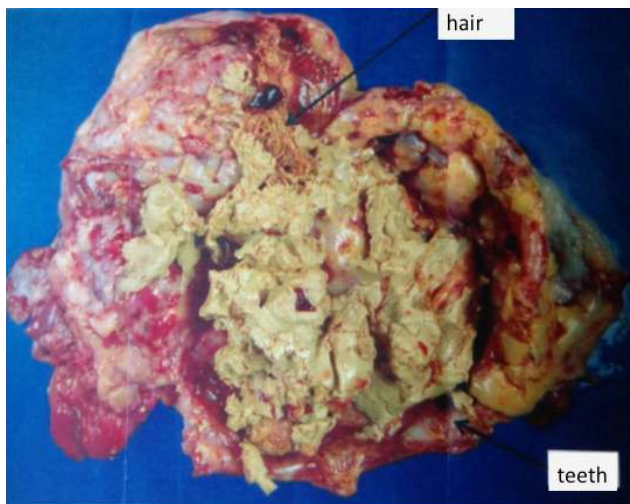
**Figure 1b.** Thoracic computed tomography (CT) on admission



Legend: Thoracic CT confirmed the presence of a well-defined anterior mediastinal giant mass (22x17x15 cm) extending to the right hemithorax. The mediastinal mass was composed of several large cystic spaces and a small, high-density area of soft tissue with pleural effusion.

the basis of the surgical findings, we diagnosed both right atrial compression and ruptured mature mediastinal teratoma. Therefore, we could not distinguish the fluid differences between the teratoma contents and pleural effusion. In addition, there was no malignant component. The patient was discharged on the 14th post-operative day with no major complications.

**Figure 2.** Gross examination indicated a rounded tumor measuring 19.0x17.0x8.0 cm, which contained sebaceous material with some hair and teeth



## Discussion

Thirty-six percent of all ruptured mediastinal teratomas are identified because of collateral symptoms, including chest pain, dyspnea, fever, and cough. (4) In the present case, febrile polypnea, severe chest and back pain, and hypotension indicated the presence of a systemic inflammatory response syndrome, result-

ing in a diagnosis of septic (or distributive) shock apart from ruptured mediastinal teratomas. However, on physical examination, discrepancies were evident in the etiology between the septic (or distributive) and obstructive shock due to the presence of jugular venous distention. However, the lung CT findings accounted for the coexistence of these 2 types of shock by revealing the extrinsic compression of the right atrium, lung consolidation, and heterogeneous changes in the internal architecture. Southgate et al. reported that proteolytic or digestive enzymes, such as those in pancreatic tissue, are released from mature teratomas in the mediastinum, leading to adhesion and erosion of the adjacent architecture. (5) Therefore, mediastinal teratomas have been considered to rupture more frequently than other teratomas. One possible mechanism for the rupture or formation of a fistula is the development of a chronic inflammatory spur on the cyst wall. This hypothesis is supported by the homogeneity involved in the only distinguishable CT feature from a ruptured teratoma. Additional changes include pericardial effusion and pleural effusion, bronchial invasion, and lung consolidation. (6)

In our histological study, although an apparent fistula formation was not observed, there were some changes in the tumor wall that made it thin and fragile. Moreover, an elevation in amylase level was observed in the pleural effusion or in the tumor contents. There was no difference in density between the pleural effusion and the tumor contents revealed in the thoracic CT. Hence, a different mechanism appeared to be responsible for the rupture of the mediastinal teratoma.

In the current case, infection resulting from the presence of pneumonia, abscess, and bacteremia subsequent to sepsis is the most reasonable explanation

for the tumor perforation. Although evidence for an infectious process involved in the rupturing of teratomas has rarely been reported, the presence of infection was clearly detected in the present case. Furthermore, infection can lead to necrosis of the tumor wall, which then becomes thin and fragile. However, it should be noted that the tumor might grow at a more rapid pace compared to the development of blood supply, which can promote ischemic changes. If ischemic changes occurred in the present case because of rapid tumor growth, it could explain the rapid development (within 24 h) of symptoms, with the tumor located in a narrow space compressing the surrounding structures according to its position.

Based on these findings, although there was an apparent fistula in the tumor, we considered that the tumor, which ruptured into the pleural space, likely oozed due to the presence of a hole in the thin and fragile tumor wall.

The presence of both obstructive and septic shock following rupture of a mature mediastinal teratoma is very rarely reported. Both infection and ischemic changes were considered to affect the progression of complications in the present case. The symptoms of a ruptured mature mediastinal teratoma vary with regard to the site of pleural rupture, with life-threatening complications that occasionally require treatment with emergency surgery.

## Conclusion

Both obstructive and severe septic shock can result from ruptured mature mediastinal teratomas. Infection and ischemic changes were considered the mechanisms that likely resulted in the rupture of the teratoma. The patient was successfully treated with a median sternotomy followed by tumorectomy.

---

## References

1. Lewis BD, Hurt RD, Payne WS, Farrow GM, Knapp RH, Muhm JR. Benign teratomas of the mediastinum. *J Thorac Cardiovasc Surg* 1983;86:727-31.
2. Strollo DC, Rosado de Christenson ML, Jett JR. Primary mediastinal tumors. Part 1: tumors of the anterior mediastinum. *Chest* 1997;112:511-22.
3. Pikin O, Kolbanov K, Kazakevich V, Korolev A. Mediastinal mature cystic teratoma perforating into the lung. *Interact Cardiovasc Thorac Surg* 2010;11:827-9.
4. Sasaka K, Kurihara Y, Nakajima Y, Seto Y, Endo I, Ishikawa T, et al. Spontaneous rupture: a complication of benign mature teratomas of the mediastinum. *AJR Am J Roentgenol* 1998;170:323-8.
5. Southgate J, Slade PR. Teratodermoid cyst of the mediastinum with pancreatic enzyme secretion. *Thorax* 1982;37:476-7.
6. Moeller KH, Rosado-de-Christenson ML, Templeton PA. Mediastinal mature teratoma: imaging features. *AJR Am J Roentgenol* 1997;169:985-90.