

Biloma: multiple organ failure after laparoscopic cholecystectomy

Javier Baidon, Joseph Varon

Abstract

Multiple organ failure and septic shock due to a biloma secondary to laparoscopic cholecystectomy (LC) is an infrequent and rare complication of this procedure. We present the case of a patient that presented to the emergency department with septic shock and multiple organ failure after undergoing

LC two weeks prior to admission. An abdominal computerized tomography (CT) depicted a large biloma. The patient underwent ultrasound guided percutaneous drainage, with follow up by an endoscopic retrograde cholangiopancreatography and a laparotomy.

Key words: Biloma, cholecystectomy, multiple organ failure, sepsis, septic shock.

Introduction

The term biloma was first described by Gould and Patel in 1979. A "biloma" is a loculated bile collection located outside the biliary tree that can be caused by traumatic, iatrogenic or spontaneous rupture of the biliary tree. (1) This is an uncommon complication of laparoscopic procedures. Laparoscopic cholecystectomy (LC) has become the treatment of choice in the management of cholelithiasis. With approximately 700,000 LCs being performed every year, the reported incidence of bile duct injury is between 0.5% and 0.85%. (2-4) There are only few cases in the literature of this complication after LC. We recently had one such case.

Case report

A 60-year-old gentleman who had undergone an LC due to chronic abdominal pain and fatty food intolerance (apparently without any intraoperative complications), presented to the emergency department two weeks later complaining of right up-

per quadrant abdominal pain. He was noted to have altered mental status at that time with a blood pressure of 70/40 mmHg and a respiratory rate of 35 respirations per minute. On physical examination, he had diffuse abdominal tenderness, palpable liver, no evidence of generalized jaundice. Both feet were cyanotic (**Figure 1**). Initial laboratory data is depicted in **Table 1**.

The patient was promptly intubated and placed on assisted mechanical ventilation. An arterial line and central venous catheter were also placed and treated with empiric antibiotics. After adequate volume resuscitation, norepinephrine and vasopressin were started to maintain an acceptable perfusion pressure. An abdominal computed tomography (CT) scan was emergently performed and revealed a large hypodense collection in the right upper quadrant (19 x 14.5 x 18.1 cm) (**Figures 2**). A percutaneous ultrasound (US)-guided drainage was performed draining more than 2000 cc of dark green fluid consistent with bile (**Figure 3**).

Over 24 hours, his hemodynamic state improves as well as his laboratory results (**Table 1**) The cyanosis of his lower extremities resolved. The patient had an endoscopic retrograde cholangiopancreatography (ERCP) showing an active leak. A stent was unable to be placed due to severe inflammation of the ampulla of Vater. The patient underwent laparotomy with biliary reconstruction, and remained in the hospital for another 2 weeks. He was discharged in stable condition.

Discussion

The clinical signs and symptoms of a biloma are nonspecific, ranging from no symptoms to abdominal pain, fever, leukocytosis, jaundice, and tenderness in the right upper abdominal quadrant. (5) Our patient presented with abdominal pain,

From Dorrington Medical Associates, Universidad Del Valle de Mexico, Campus Hermosillo, School of Medicine, Houston, Texas, USA (Javier Baidon) and University General Hospital, The University of Texas Health Science Center at Houston, The University of Texas Medical Branch at Galveston, Dorrington Medical Associates, Houston, Texas, USA (Joseph Varon).

Address for correspondence:

Joseph Varon, MD, FACP, FCCP, FCCM, FRSM
2219 Dorrington Street
Houston, Texas, 77030, USA
Tel: +1-713-669-1670
Fax: +1-713-669-1671
Email: joseph.varon@uth.tmc.edu

fever, leukocytosis, jaundice, and tenderness in the right upper abdominal quadrant. (5) Our patient presented with abdominal pain, leukocytosis, cyanosis secondary to septic shock, but no evidence of jaundice.

In the past, the treatment of choice for bilomas was surgery. New advances in technology provide a wider variety of treatment options such as, catheter drainage, endoscopic sphincterotomy, and endoscopic biliary drainage. Small bilomas, of few centimeters in diameter, can have an expectative therapy. (3) Before laparoscopic surgery, the incidence of bile duct injury was about 0.1%, however now with LC the incidence is 0.5%-0.85%. (6)

In our case the diagnosis was established by CT scan, and emergency drainage was accomplished percutaneously under US guidance. Some authors reserve surgery for cases of major bile duct injury,

especially when percutaneous drainage and ERCP fail, as in the case of our patient. (6-10)

A bile leak should be suspected in any patient with persistent abdominal pain, fever or leukocytosis after undergoing LC. Ultrasound, CT scan and hepatobiliary scintigraphy should be used for evaluation. The combined used of radiologic and endoscopic management may avoid surgery in 70% of cases. (9)

Conclusions

Any persistent abdominal pain after an LC should be assessed with at least an US to rule out a biloma. Early diagnosis and percutaneous drainage under US guidance is the recommended treatment to prevent further complications. In cases where radiologic and endoscopic management are not effective, surgery is the treatment of choice.

Table 1. Laboratory data on arrival and at 24 hours after admission

	Day #1	Day #2
WBC (cells/mm ³)	25.7	16
ALP (IU/L)	346	237
ALT (U/L)	469	243
AST (U/L)	848	255
Bilit (mg/dL)	4.30	2.30
Sodium (mEq/L)	125	138
BUN (mg/100 cc)	74	25
CR-S (mg/dL)	3.76	1.0
CK (U/L)	2395	1621
PCT (ug/L)	4.01	

Legend: WBC=white blood cell count; ALP=alkaline phosphatase; ALT=alanine aminotransferase; AST=aspartate aminotransferase; Bilit=total bilirubin; BUN=blood urea nitrogen; CR-S=serum creatinine; CK=creatinine kinase; PCT=procalcitonin.

Figure 1. Cyanosis noted on both feet of the patient on arrival to the hospital

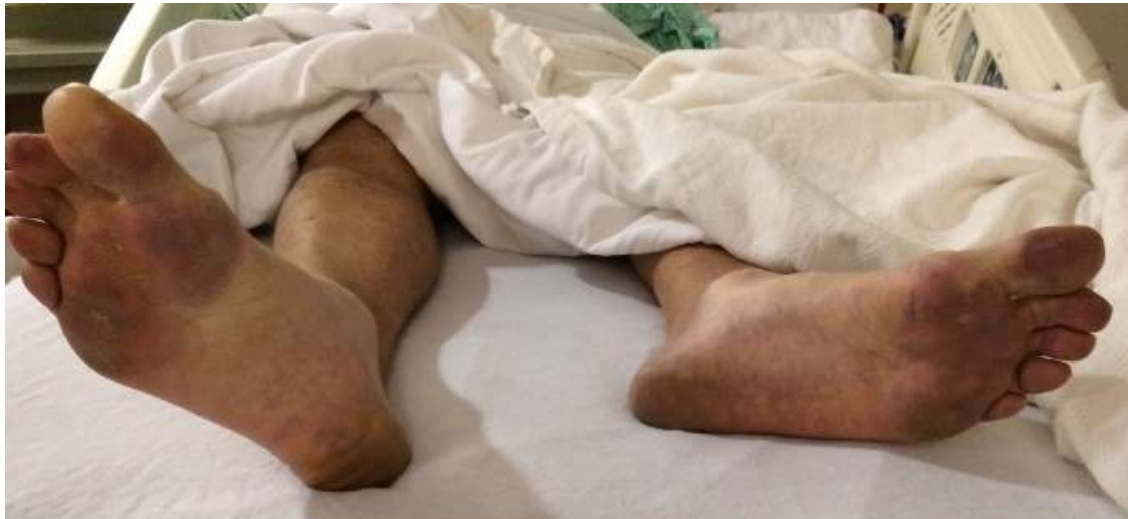

Figure 2. Computed tomography of the patient on arrival to the intensive care unit revealing a large hypodense in the right upper quadrant

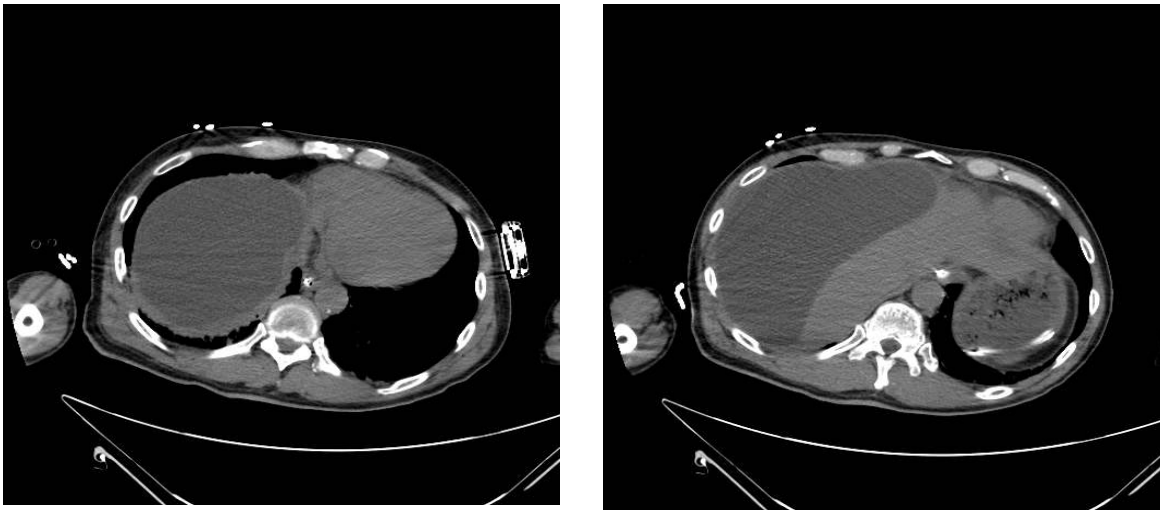
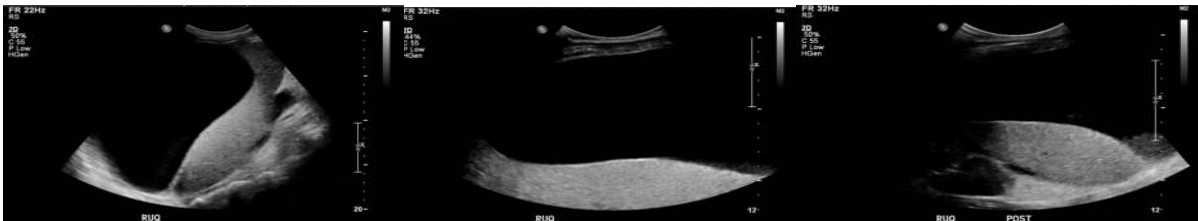


Figure 3. Large perihepatic fluid collection noted on ultrasonography



References

1. Gould L, Patel A. Ultrasound detection of extrahepatic encapsulated bile: "Biloma." *AJR Am J Roentgenol* 1979;132:1014-5.
2. Pavlidis TE, Atmatzidis KS, Papaziogas BT, Galanis IN, Koutelidakis IM, Papaziogas TB. Biloma after laparoscopic cholecystectomy. *Ann Gastroenterol* 2002;15:178-80.
3. Lee JH, Suh JI. A case of infected biloma due to spontaneous intrahepatic biliary rupture. *Korean J Intern Med* 2007;22:220-4.
4. Nair RG, Dunn DC, Fowler S, McCloy RF. Progress with cholecystectomy: Improving results in England and Wales. *Br J Surg* 1997; 84:1396-8.
5. Binmoeller KF, Katon RM, Shneidman R. Endoscopic management of postoperative biliary leaks: review of 77 cases and report of two cases with biloma formation. *Am J Gastroenterol* 1991;86:227-31.
6. Stathopoulos V, Georganas M, Stratakis K, Delaporta E, Karallas E, Koutsopoulos K. Hepatic subcapsular biloma: A rare complication of laparoscopic cholecystectomy. *Case Rep Surg* 2014;2014:186819.
7. Braithwaite BM, Cabanilla LT, Lilly M. Hepatic subcapsular biloma: A rare complication of laparoscopic cholecystectomy and common bile duct exploration. *Curr Surg* 2003;60:196-8.
8. Dev V, Shah D, Gaw F, Lefor AT. Gastric outlet obstruction secondary to post cholecystectomy biloma: Case report and review of the literature. *JLS* 1998;2:185-8.
9. Bezzi M, Silecchia G, Orsi F, Materia A, Salvatori FM, Fiocca F, et al. Complications after laparoscopic cholecystectomy. Coordinated radiologic, endoscopic, and surgical treatment. *Surg Endosc* 1995;9:29-36.
10. Sammak BM, Yousef BA, Gali MH, al Karawi MA, Mohamed AE. Case report: Radiological and endoscopic management of bile leak following laparoscopic cholecystectomy. *J Gastroenterol Hepatol* 1997;12:34-8.