

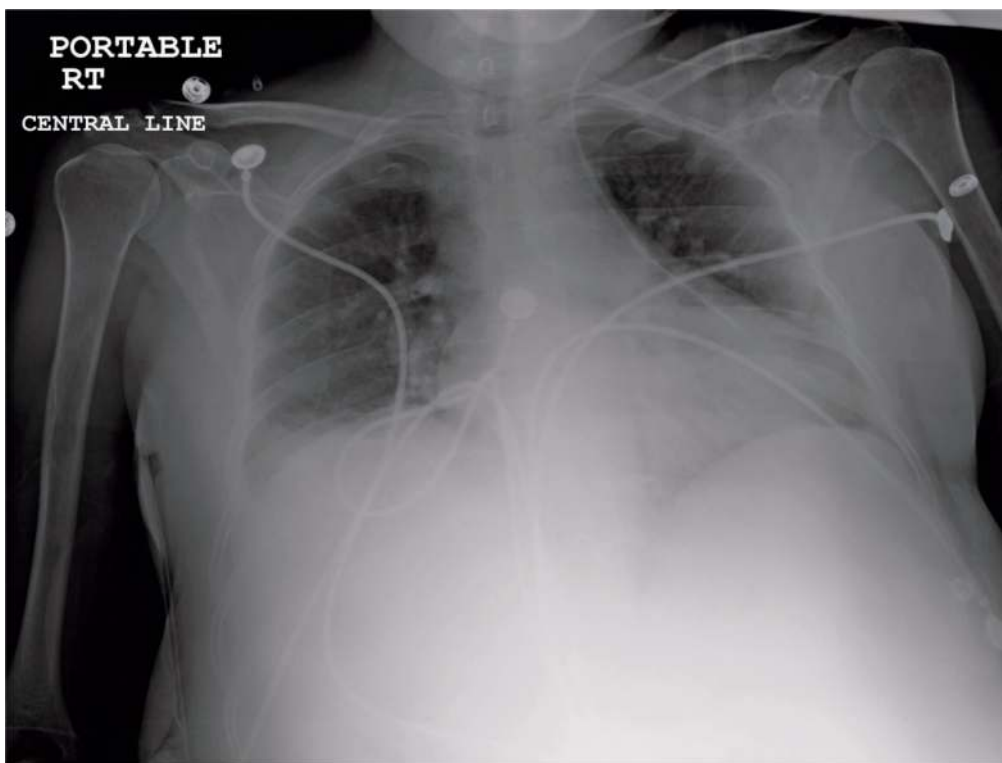
## Aberrant central venous cannulation of the pericardial vein

*Amina Khimani, Saherish Surani, Joseph Varon, Salim Surani*

Central venous catheter placement is one of the most common procedures in Emergency Departments (ED) and Intensive Care Units (ICU) across the world. A variety of potential complications can occur in patients undergoing these procedures. Incorrect position of the catheter is quite common. Cannulation of azygous arch, occurs in 0.7-1.2% of all central venous catheter insertion, and is seven times more common when access is approached from the left

side. (1,2) Due to the venous drainage of the chest wall region, cannulation especially from left side, can lead to the catheters being placed in the aberrant location in hemiazygous vein or one of its tributaries, such as the pericardial veins, as shown in the Figure. The aberrant cannulation of azygous vein or its tributaries carries a high risk for perforation leading to effusions and mediastinal hematomas. (2)

**Figure.** Chest X-ray AP view showing central venous line in pericardial vein via the left internal jugular venous approach



From University of California, Berkeley, USA (Amina Khimani), Corpus Christi, Texas, USA (Saheerish Surani), University General Hospital, and The University of Texas Health Science Center at Houston (Joseph Varon), and Texas A&M University, Texas, USA (Salim Surani).

**Address for correspondence:**

Salim Surani, MD  
1177 West Wheeler Ave, suite 1  
Aransas Pass, Texas 78336, USA

## References

1. Hsu KF, Yeh CL, Huang GH, Chang HC, Tang SH. Aberrant central venous catheter-bilateral superior vena cava. *J Trauma* 2010;69:E108.
2. Bankier AA, Mallek R, Wiesmayr MN, Fleischmann D, Kranz A, Kontrus M, et al. Azygos arch cannulation by central venous catheters: Radiographic detection of malposition and subsequent complications. *J Thorac Imaging* 1997;12:64-9.