

# Pseudo hydropneumothorax: The importance of history taking in critical care

*Siva Padmanabhan Sivakumar, Sivakumar Sudhakaran, Saherish Surani, Salim Surani*

## Abstract

**History taking is an important part of the diagnosis of every patient. With the advancement of technology and limited time, this art seems forgotten. We hereby present an image of pseudo**

**hydropneumothorax, which can have wide differential diagnoses. Proper history taking in critical care setting can help in early diagnosis; decrease length of hospital stay and diagnostic costs.**

**Key words:** Hydropneumothorax, intestinal obstruction, chest radiograph.

## Case presentation

A 62-year-old man presented to the emergency department (ED) with gastrointestinal bleeding. He was admitted to the intensive care unit. The patient's past medical history was significant for hypertension, gastroesophageal reflux disease, deep vein thrombosis, cardiomyopathy, and paroxysmal atrial fibrillation. Chest X-ray (CXR) revealed hydropneumothorax in the right chest, and lung abscess was high on the list of differential diagnoses (**Figure 1**). However, a computed tomography (CT) of the chest showed a portion of the patient's stomach in the right thoracic cavity (**Figure 2**). Gastrografin swallow study revealed delayed gastric emptying due to pylorospasm (**Figure 3**). Interestingly, assessment of CXRs showed a pattern of intermittent gastric obstruction that could easily be misconstrued as hydropneumothorax. After a more detailed patient history was taken, it was discovered that the patient had undergone a number of surgical procedures including Ivor-Lewis esophagogastrectomy with gastric pull-through (via laparotomy and thoracotomy) for adenocarcinoma at the gastroesophageal junction

years prior to his presentation to our ED.

## Discussion

This unique case of pseudo pneumothorax highlights the importance of understanding a patient's history and clinical picture before reviewing CXR images. It exhibits the ease in which one may arrive at a misdiagnosis if a good patient history is not taken. One study found that general practitioners using routine assessment methods correctly diagnosed only 64.5% of CXRs with pneumothorax. (1) Besides an incomplete patient history, there are a number of extraneous factors that may lead to confusion and misdiagnosis when reviewing a CXR including pseudo pneumothorax. Various artifacts including skin folds, shirt folds, and medial border of the scapula have been reported to mimic pneumothorax on CXRs. (2-4) It is essential to correlate radiological evidence with clinical findings before finalizing any treatment strategies. Moreover, though CXR remains a valuable tool for diagnosis of pneumothorax, CT or chest ultrasound can be used to confirm a diagnosis. (5)

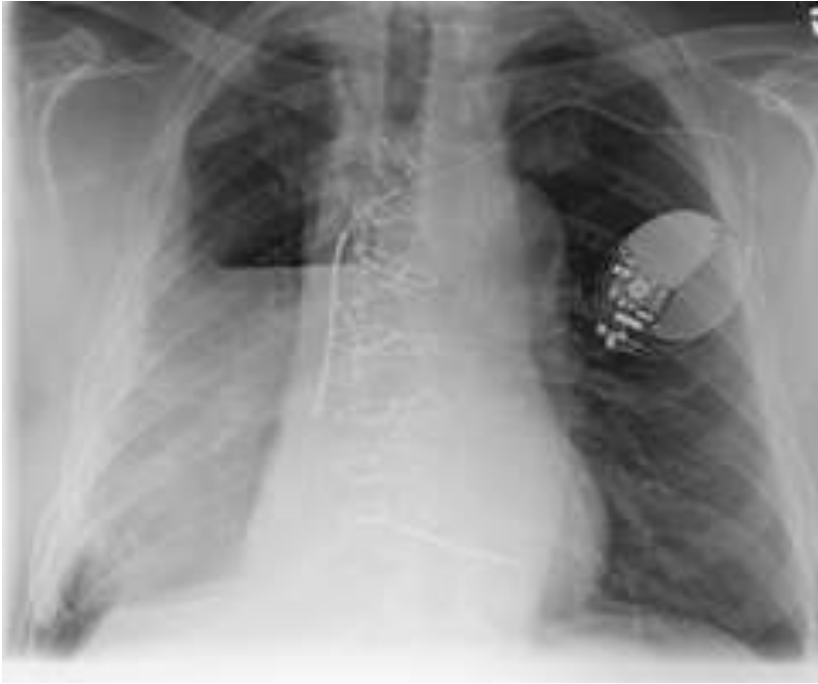---

From Holyoke Medical Center, Holyoke, MA 01040 USA (Siva Padmanabhan Sivakumar), Texas A&M University Health Science Center (Sivakumar Sudhakaran), Pulmonary Associates of Corpus Christi, Texas USA (Saherish Surani), and Texas A&M University, Corpus Christi, Texas, USA (Salim Surani).

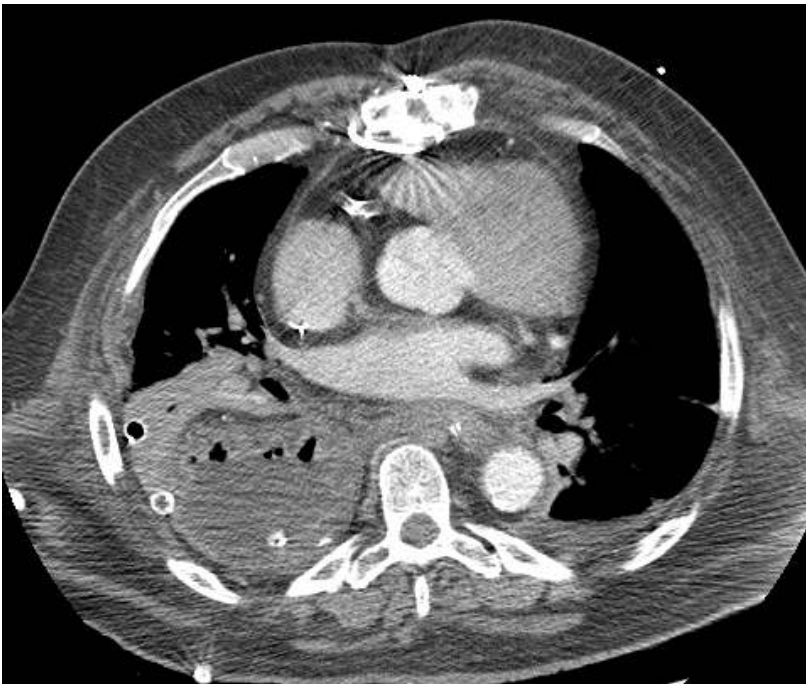
## Address for correspondence:

Salim Surani, MD  
1177 West Wheeler Ave  
Aransas Pass Texas, 78336, USA  
Tel: 361-885-7722  
Fax: 361-850756  
Email: srsurani@hotmail.com

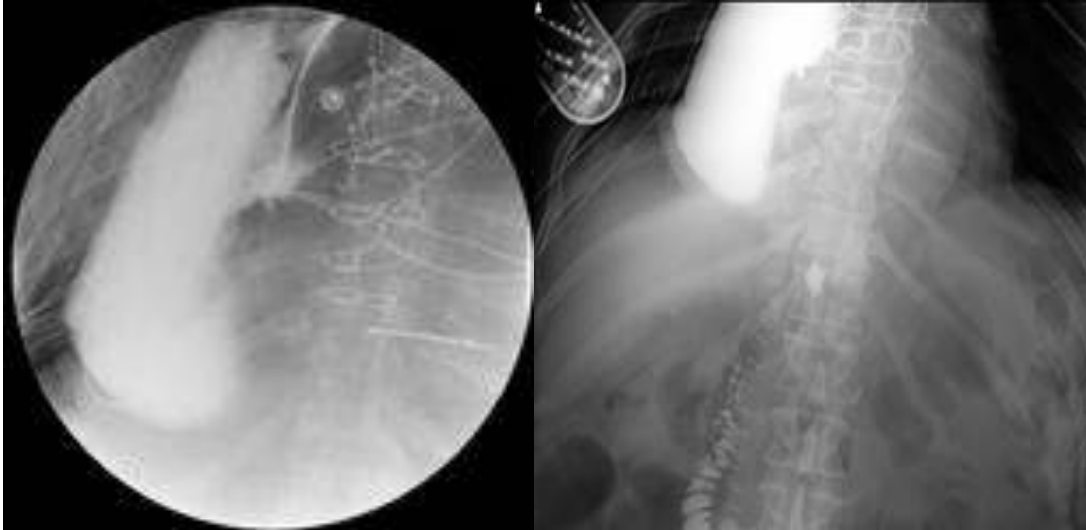
**Figure 1.** Pseudo obstruction in a patient with Ivor-Lewis esophagogastrectomy with gastric pull-through resembling hydropneumothorax



**Figure 2.** Chest CT scan revealing a portion of the stomach in the right thoracic cavity



**Figure 3.** Gastrografin swallow study revealing delayed gastric emptying due to pylorospasm



## References

1. Ghane MR, Saburi A, Javadzadeh HR. A recommended method in order to interpret chest x-rays for diagnosing small size pneumothorax. *Int J Crit Illn Inj Sci* 2013;3: 36-9.
2. Silva FR. Shirt fold mimicking pneumothorax on chest radiograph: accurate diagnosis by ultrasound. *Intern Emerg Med* 2007;2:236-8.
3. Fisher JK. Skin fold versus pneumothorax. *AJR Am J Roentgenol* 1978;130:791-2.
4. Lahzami S, Eggenberger P, Lehmann BC. Listen to your patient.... *Eur J Emerg Med* 2007;14:274-5.
5. Kamath S, Balethbail S, Parthasarathi G. Pseudo-pneumothorax: look before you leap! *Anesth Analg* 2008;107:1759.