

## McConnell's sign is not specific for acute pulmonary embolism - A case report

Mohamad Iqbal Bin Kunji Mohamad, Mohd Fazrul Bin Mokhtar, Julina @Azimah Mohd Noor, Nur Abdul Karim, Izzat Bin Ismail, Abdul Halim Bin Sanib, Mohd Amin Mohd Mokhtar, Safreeda SF Salim

### Abstract

Since 1996, McConnell's sign, defined as right free wall hypokinesia with apical sparing, described as one of the most specific echocardiographic finding for acute pulmonary embolism. It was incorporated in the standard teaching and text book as a tell-tale sign for the condition. This is a case report of a patient presented with chest pain and presyncope with markedly raised D-dimer and suspicious electrocardiogram finding. The bedside focused cardiac ultrasound revealed the classical McConnell's

sign. However, the computed tomography pulmonary angiogram for pulmonary embolism was negative. The patient was subsequently diagnosed as pulmonary hypertension secondary from chronic methamphetamine abuse. This case highlights that McConnell's sign is not specific for acute pulmonary embolism. It is also important to stratify patient according to a validated clinical probability score for pulmonary embolism before initiating definitive acute treatment.

**Key words:** McConnell's sign, FOCUS, pulmonary embolism, echocardiography, pulmonary hypertension, methamphetamine abuse.

### Introduction

The use of focused cardiac ultrasound (FOCUS) in emergency and critical care department is becoming widespread and part of standard of care. (1,2) It is used in myriad of condition to rule out time dependent life-threatening condition, such as pulmonary embolism (PE). (3) Certain echocardiographic finding had been described as classical and specific for the diagnosis of PE. One of it is the right ventricular free wall hypokinesia with apical sparing,

also known as "McConnell's sign". (4)

This is a case report of a patient with positive McConnell's sign with no evidence of PE.

### Case report

A 22-year-old Vietnamese lady presented to Department of Emergency Medicine, Hospital Sungai Buloh, with an episode of presyncope after a jog. It was preceded by mild chest pain described as compressing in nature which lasted for a few minutes. There was no shortness of breath, palpitations or diaphoresis. There was no loss of consciousness. She was arousable during the episode without seizure, jerky movement, urinary incontinence or post ictal drowsiness.

She had been having reduced effort tolerance and occasionally palpitations since the past few weeks but did not obtain any medical consultation.

She had no history of excessive per vaginal bleeding. Her last menstrual period was two weeks prior and currently on contraceptive pills. She denied fever, diarrhea, vomiting, or abdominal pain. There was no history of long-haul travel or prolonged immobilization.

She worked as bartender and had been abusing methamphetamine and ketamine for many years.

---

From Department of Emergency Medicine, Faculty of Medicine, Universiti Teknologi Mara, Sungai Buloh, Selangor, Malaysia (Mohamad Iqbal Bin Kunji Mohamad, Mohd Fazrul Bin Mokhtar, Julina @Azimah Mohd Noor, Nur Abdul Karim, Izzat Bin Ismail, Abdul Halim Bin Sanib, Mohd Amin Mohd Mokhtar, and Safreeda SF Salim).

### Address for correspondence:

Dr. Mohamad Iqbal Bin Kunji Mohamad, MD, MMED, MRCP

Department of Emergency Medicine, Faculty of Medicine, Universiti Teknologi Mara, 47000, Sungai Buloh, Selangor, Malaysia.

HP: +60126605231

Email: alif\_1979@yahoo.com

She had no family members with history of sudden death.

On general examination, she was thin. She was alert and orientated to time, place, and person. She was pink and her hydration was good, heart rate was 98 beats per minute, blood pressure was 91/58 mmHg, O<sub>2</sub> saturation was 99% on room air, and she was afebrile. Her pulse was regular rhythm with normal volume. Her cardiovascular examination revealed normal first and second heart sounds with no additional sound or murmur. Her respiratory, abdominal and neurological examinations were normal. No leg swelling or organomegaly found.

The electrocardiogram (ECG) showed sinus tachycardia, with partial right bundle branch block and T wave inversion in leads II, III, aVF, V1-V3.

The total white cell count was  $14.9 \times 10^9/l$ , hemoglobin was 14.4 g/l, platelet was  $685 \times 10^9/l$ . Her sodium, potassium, urea, creatinine levels, liver function test were all normal. However, the D-dimer was raised (1813 ng/ml FEU). High-sensitivity Troponin I was also raised (44 pg/ml) and it doubled four hours after that to 109 pg/ml (normal value <15.6 pg/ml). Her urine pregnancy test was negative.

The attending Emergency physician performed FOCUS which showed right ventricular enlargement with paradoxical septal motion, ventricular septal flattening on diastole, akinesia of the right ventricular free wall with presence of contractility of the right apical region (McConnell's sign) (**Figures 1,2,3,4**)

In view of the combination of risk factors i.e. usage of oral contraceptive pills, ECG findings, echocardiography findings, and markedly raised D-dimer, our provisional diagnosis was pulmonary embolism (PE). Subcutaneous fraxiparine was administered and emergent computed tomography pulmonary angiogram (CTPA) was ordered.

CTPA revealed no evidence of embolism, and the main pulmonary trunk, right, and left pulmonary arteries, its segmental and subsegmental branches were normal and well opacified with no filling defect, and not dilated. The aortopulmonary ratio was preserved. The lungs field were all clear. The diagnosis of PE was revisited and she was admitted to medical ward for further investigation of possible pulmonary hypertension secondary to sympathomimetic drug abuse.

A comprehensive echocardiogram done by cardiology unit revealed right ventricular enlargement with right ventricular systolic pressure of 39 mmHg. It was also specifically mentioned the presence of McConnell's sign. In the ward, as the patient remain stable with normal blood pressure,

she was discharged the next day with appointment given for right heart catheterization study with cardiologist. She unfortunately defaulted the follow up.

## Discussion

Pulmonary embolism (PE) and deep vein thrombosis (DVT) are the third commonest cardiovascular disease with overall annual incidence of 100 per 100,000 person-years. (5) Epidemiological data from the European Union reported that majority of death from PE were the undiagnosed PE during life, and less than 10% of patients who died early were correctly diagnosed with PE before death. (6) This correlates with several studies showing that the clinical presentation and severity of PE are variable and correct diagnosis can be difficult. (7) Similar to the Caucasians, the South-East Asian patients may have a wide range of signs and symptoms. Even the incidence of syncope is between 3-6%, unexplained syncope may warrant further investigation for PE. (8,9)

The European Society of Cardiology (ESC) guidelines recommended the use of clinical judgment and probability tests as key steps in the diagnostic algorithms of PE. (10) This risk stratification guides physician on further investigations towards the diagnosis for the high-risk patients.

One of the bedside investigations that can be performed is the FOCUS. In an acute PE, the right ventricular (RV) overload and dysfunction can be detected by echocardiography. In 1996, Michael McConnell introduced an echocardiogram finding of normal motion at the apex and abnormal wall motion in the mid-free wall of right ventricular as highly specific for acute PE (sensitivity of 77% and specificity of 94%), and since then it was labeled as the McConnell's sign. (4) It was also suggested that the sign could be used to differentiate PE and chronic pulmonary hypertension. In 2008, Lodato et al reported a high specificity of 96% for McConnell's sign to be diagnostic for PE but with very low sensitivity (16%). The right ventricular/left ventricular end diastolic diameter ratio >0.7 has 66% sensitivity and 77% specificity for PE. (11) In a study of 146 participants with moderate and high probability of pulmonary embolism, it was noted that right ventricular dilatation on bedside echocardiography had 50% sensitivity for pulmonary embolism, specificity of 98%, positive predictive value of 88% and negative predictive value of 88%. (12) Seong et al further elaborated that the presence of McConnell's sign as very distinctive for massive pulmonary embolism. (13) Many more data have provided a strong predilec-

tion of PE with the presence of the sign, so much so it is incorporated in some critical care ultrasound textbook. (14,15)

However, in 2005 Cassaza et al compared 107 patients with confirmed PE and 54 patients with pulmonary infarct and found no difference in the finding of McConnell's sign between two groups, thus suggested its low sensitivity (70%) and specificity (33%) for PE. (16) In another study by Lopez-Candales et al involving 60 patients, they noted that McConnell's sign was positive in 60% of patient with acute PE and 17% of chronic pulmonary hypertension. (17) Urvashi reported low positive predictive value of McConnell's sign (57%) in diagnosing pulmonary embolism in a study done on 73 patients. (18)

As our patient presented with presyncope, with low-border blood pressure, highly suspicious electrocardiogram finding, markedly high D-dimer and highly sensitive Troponin (HS Troponin) and burden of history with chronic usage of contraceptive pills, the FOCUS finding of McConnell's sign had drove us towards the diagnosis of acute pulmonary embolism, hence the initiation of anticoagulant before CTPA was done. This is in tandem with some report of initiating treatment based on presence of McConnell's sign without confirmatory CT in a highly suspicious case. (19) The American College of Chest Physician also recommended parenteral anticoagulant in a patient with a high and intermediate clinical suspicion of acute PE while awaiting the results of diagnostic test. (20)

However, given all the mixed data, it is prudent

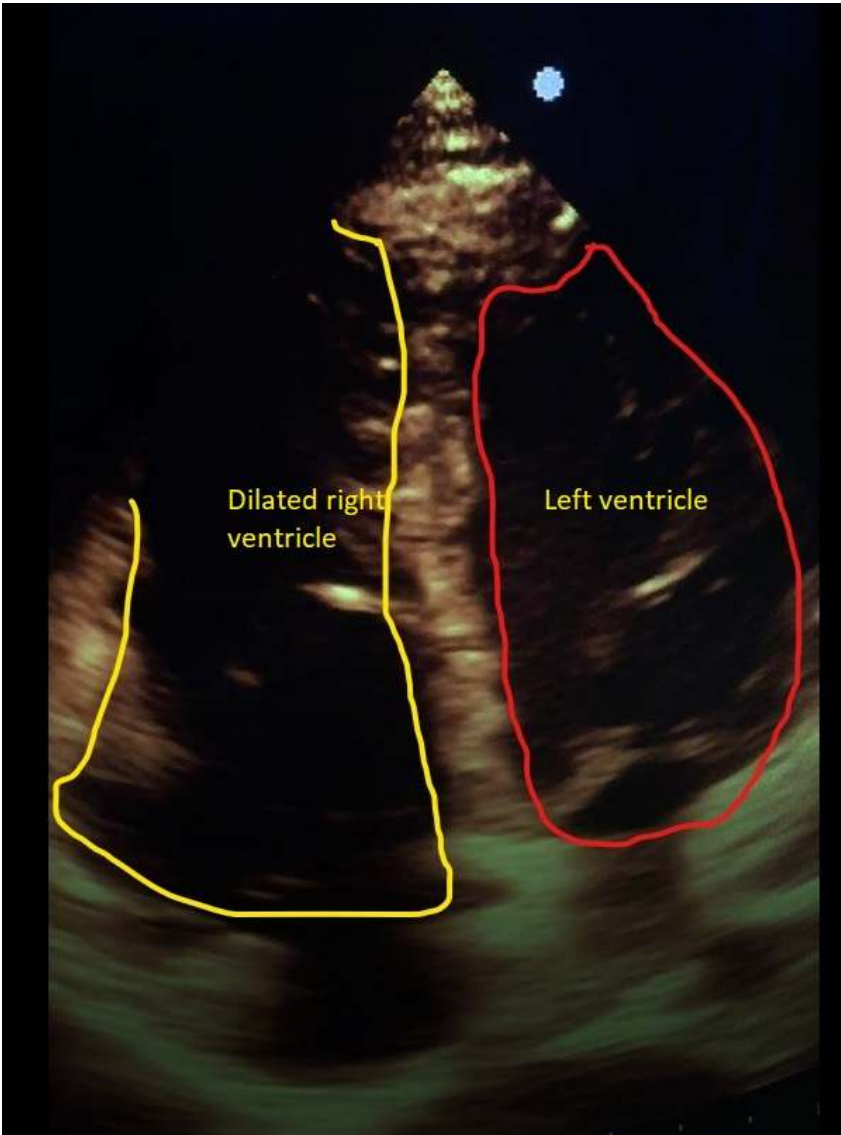
that the echocardiographic finding not interpreted in isolation and all other parameters should be taken into account before establishing the diagnosis. The recommendation to start anticoagulant empirically need to be taken in the context of hemodynamic unstable patient with high risk of PE. (21) The 2014 European Society of Cardiology (ESC) also do not recommend the usage bedside echocardiography as diagnostic work-up in hemodynamically stable and low risk PE. (10)

Even our patient deemed to be highly suspicious of PE, it is still within low to moderate risk according to the clinical probability test recommended by the ESC guideline. (22) Given the history of methamphetamine abuse, the most likely cause of all the clinical features is pulmonary hypertension due to chronic sympathomimetics which is a known complication. (23) The raised D-dimer and HS Troponin can be attributed to the pulmonary hypertension. (24,25)

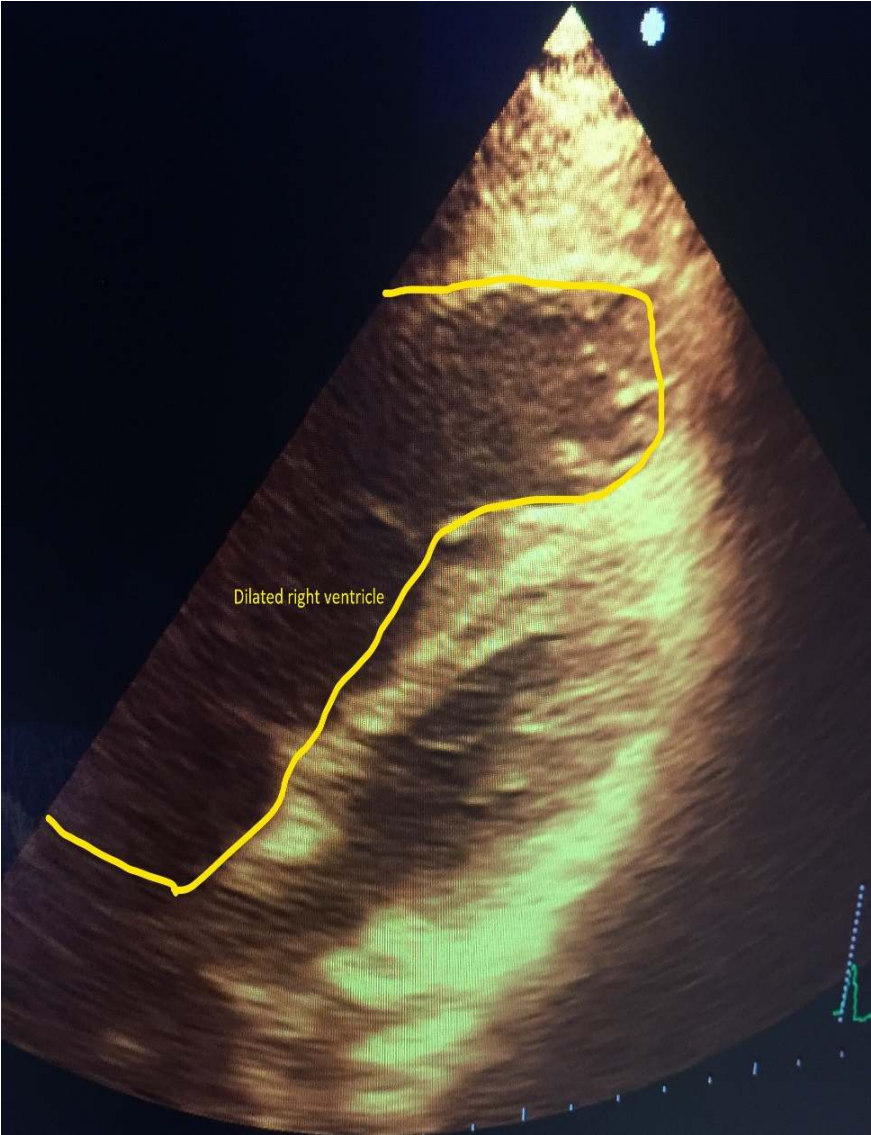### **Conclusion**

This case highlights the importance of thorough clinical judgement when diagnosing PE. The objective clinical probability test should be used in all patient suspected of PE. The usage of FOCUS must be interpreted cautiously and all the clinical parameters with their caveats should be evaluated. The presence of McConnell's sign in low probability PE and hemodynamic stable patient should not be warranted for specific management until confirmatory test is done.

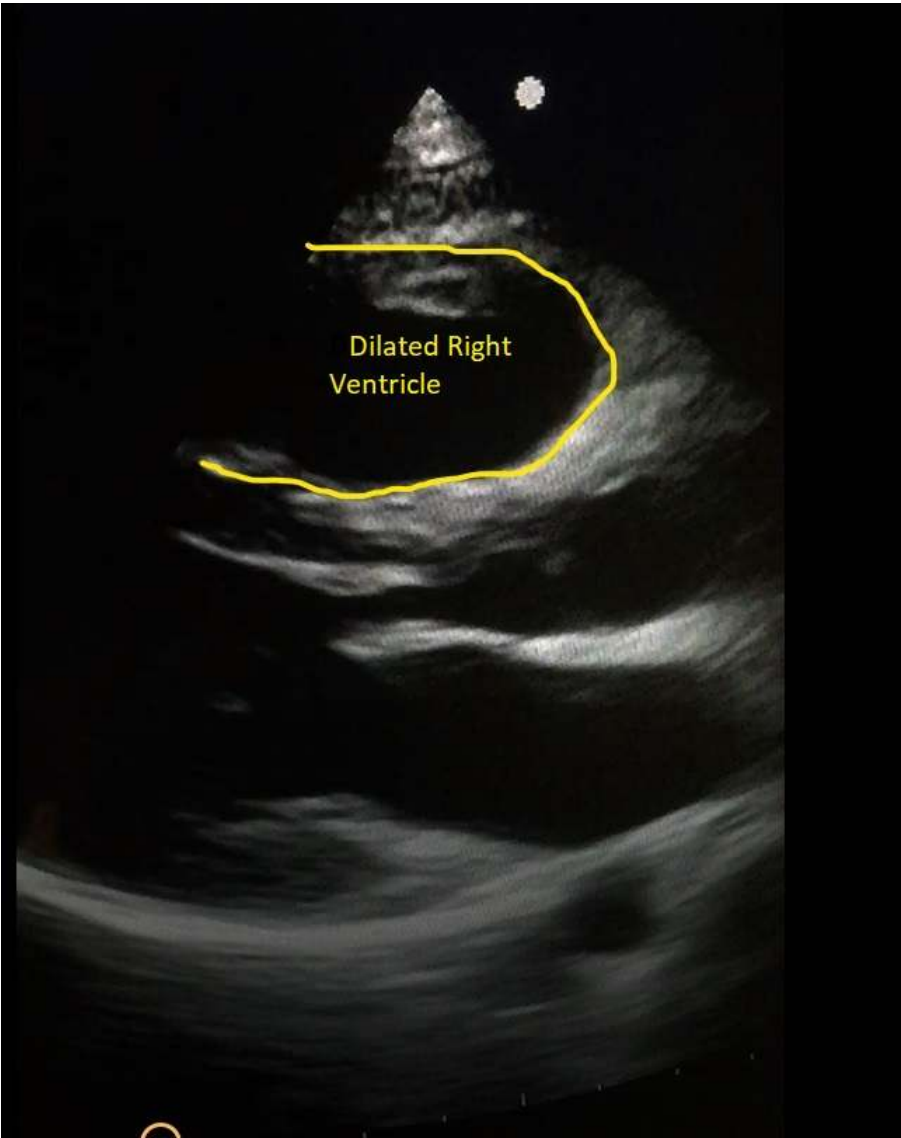**Figure 1.** Apical 4 chamber view showing dilated right ventricle compared to left ventricle



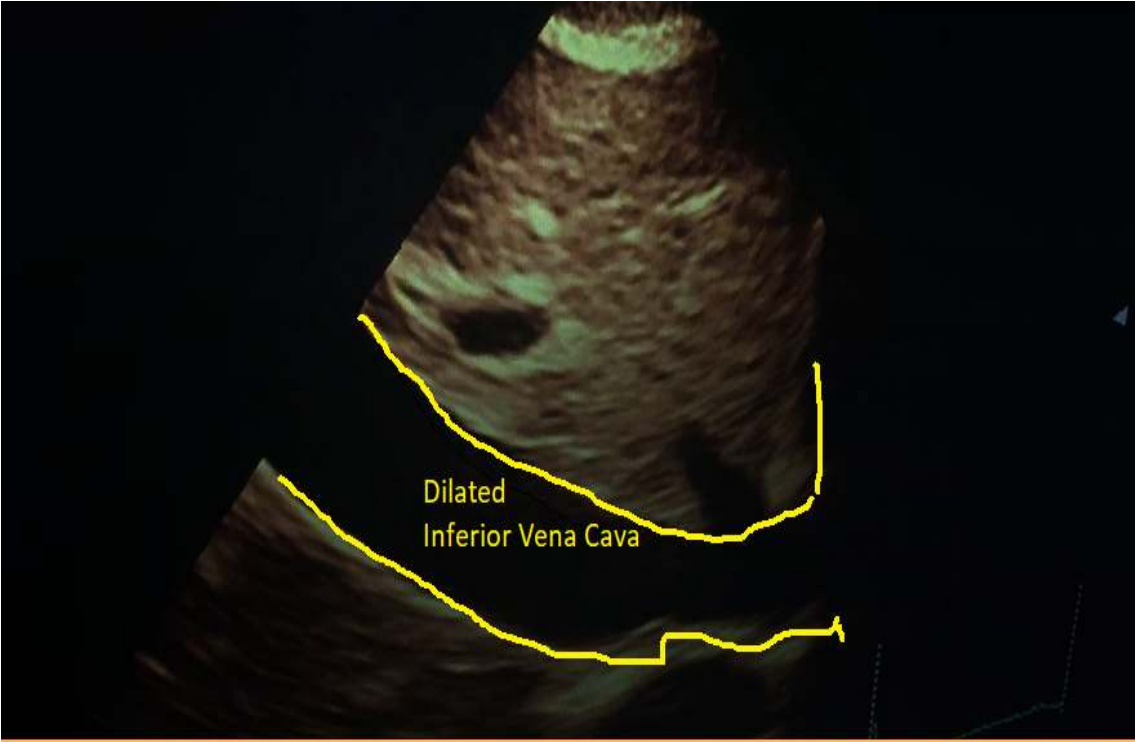
**Figure 2.** Subcostal 4 chamber view showing dilated right ventricle



**Figure 3.** Parasternal long axis view



**Figure 4.** Subcostal view showing dilated inferior vena cava



## References

1. Sippel S, Muruganandan K, Levine A, Shah S. Review article: Use of ultrasound in the developing world. *Int J Emerg Med* 2011;4:72.
2. Nelson BP, Chason K. Use of ultrasound by emergency medical services: a review. *Int J Emerg Med* 2008;1:253-9.
3. Labovitz AJ, Noble VE, Bierig M, Goldstein SA, Jones R, Kort S, et al. Focused cardiac ultrasound in the emergent setting: A consensus statement of the American society of Echocardiography and American College of Emergency Physicians. *J Am Soc Echocardiogr* 2010;23:1225-30.
4. McConnell MV, Solomon SD, Rayan ME, Come PC, Goldhaber SZ, Lee RT. Regional right ventricular dysfunction detected by echocardiography in acute pulmonary embolism. *Am J Cardiol* 1996;78:469-73.
5. Heit JA. The Epidemiology of Venous Thromboembolism in the Community. *Arterioscler Thromb Vasc Biol* 2008;28:370-2.
6. Cohen AT, Agnelli G, Anderson FA, Arcelus JI, Bergqvist D, Brecht JG, et al. Venous thromboembolism (VTE) in Europe. The number of VTE events and associated morbidity and mortality. *Thromb Haemost* 2007;98:756-64.
7. Apostolakis SZ, Konstantinides SV. Acute pulmonary embolism. In: Stergiopoulos K, Brown DL, editors. *Evidence-Based Cardiology Consult*. London: Springer-Verlag; 2014. P. 299-310.
8. Pollack CV, Schreiber D, Goldhaber SZ, Slattery D, Fanikos J, O'Neil BJ, et al. Clinical Characteristics, Management, and Outcomes of Patients Diagnosed With Acute Pulmonary Embolism in the Emergency Department: initial report of EMPEROR (Multicenter Emergency Medicine Pulmonary Embolism in the Real World Registry). *J Am Coll Cardiol* 2011;57:700-6.
9. Mok KH, Wong SW, Wong YM, Foo D, Watson TJ, Ho HH. Clinical characteristics, risk factors and outcomes of South-East Asian patients with acute pulmonary embolism. *Int J Cardiol* 2017;249:431-3.
10. Konstantinides SV, Torbicki A, Agnelli G, Danchin N, Fitzmaurice D, Galiè N, et al. 2014 ESC Guidelines on the diagnosis and management of acute pulmonary embolism. *Eur Heart J* 2014;35:3033-69.
11. Lodato JA, Ward RP, Lang RM. Echocardiographic predictors of pulmonary embolism in patients referred for helical CT. *Echocardiography* 2008;25:584-90.
12. Dresden S, Mitchell P, Rahimi L, Leo M, Rubin-Smith J, Bibi S, et al. Right ventricular dilatation on bedside echocardiography performed by emergency physicians aids in the diagnosis of pulmonary embolism. *Ann Emerg Med* 2014;63:16-24.
13. Oh SB, Bang SJ, Kim MJ. McConnell's sign; a distinctive echocardiographic finding for diagnosing acute pulmonary embolism in emergency department. *Crit Ultrasound J* 2015;7(Suppl 1):A20.
14. Lumb P, Karakitsos D, editors. *Critical care ultrasound*. 1st ed. Los Angeles (CA): Elsevier/Saunders; 2015.
15. Chenzbraun A. Emergency Echocardiography. In: Chenzbraun A, editor. *Emergency Echocardiography*. London: Springer London; 2009. P. 29-54.
16. Casazza F, Bongarzone A, Capozzi A, Agostoni O. Regional right ventricular dysfunction in acute pulmonary embolism and right ventricular infarction. *Eur J Echocardiogr* 2005; 6:11-4.
17. López-Candales A, Edelman K. Right Ventricular Outflow Tract Systolic Excursion: A Distinguishing Echocardiographic Finding in Acute Pulmonary Embolism. *Echocardiography* 2013;30:649-57.
18. Vaid U, Singer E, Marhefka GD, Kraft WK, Baram M. Poor positive predictive value of McConnell's sign on transthoracic echocardiography for the diagnosis of acute pulmonary embolism. *Hosp Pract (1995)* 2013;41:23-7.
19. Liao MM, Theoret J, Dannemiller EM, Erickson C, Sanz GE, Kendall JL. Emergency bedside ultrasound diagnosis of sub-massive acute pulmonary embolism: a case of the McConnell's sign. *Crit Ultrasound J* 2010;2: 25-7.
20. Guyatt GH, Akl EA, Crowther M, Gutterman DD, Schünemann HJ, American College of Chest Physicians Antithrombotic Therapy and Prevention of Thrombosis Panel. Executive summary: Antithrombotic therapy and prevention of thrombosis, 9th ed: American College of Chest Physicians evidence-based clinical practice guidelines. *Chest* 2012;141(Suppl):7S-47S.

21. Kucher N, Luder CM, Dörmhöfer T, Windecker S, Meier B, Hess OM. Novel management strategy for patients with suspected pulmonary embolism. *Eur Heart J* 2003;24: 366-76.
22. Wells PS, Anderson DR, Rodger M, Ginsberg JS, Kearon C, Gent M, et al. Derivation of a simple clinical model to categorize patients probability of pulmonary embolism: increasing the models utility with the SimpliRED D-dimer. *Thromb Haemost* 2000;83:416-20.
23. Chin KM, Channick RN, Rubin LJ. Is Methamphetamine Use Associated With Idiopathic Pulmonary Arterial Hypertension? *Chest* 2006;130:1657-63.
24. Shitrit D, Bendayan D, Bar-Gil-Shitrit A, Huerta M, Rudensky B, Fink G, et al. Significance of a plasma D-dimer test in patients with primary pulmonary hypertension. *Chest* 2002;122:1674-8.
25. Heresi GA, Tang WHW, Aytakin M, Hammel J, Hazen SL, Dweik RA. Sensitive cardiac troponin I predicts poor outcomes in pulmonary arterial hypertension. *Eur Respir J* 2012; 39:939-44.