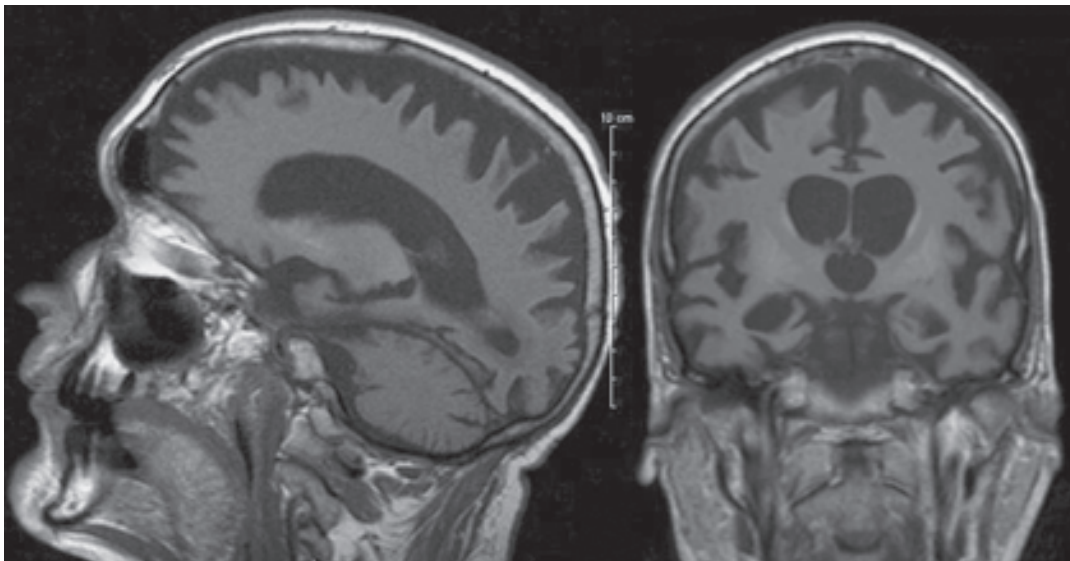


Images in Medicine

Persistent Vegetative State*Pilar Acosta, Lucas Restrepo, Joseph Varon*

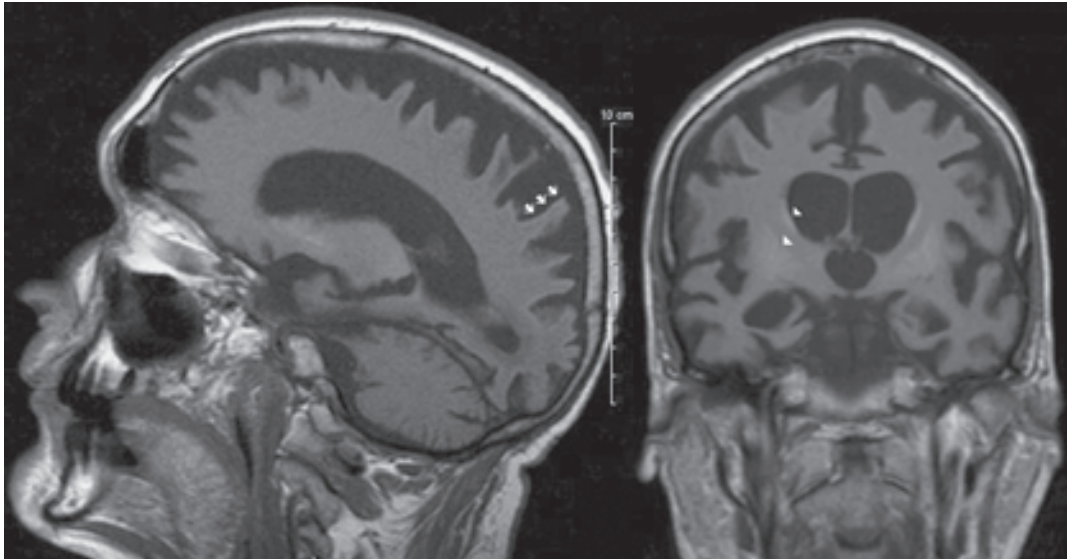
A 39-year old gentleman with pancreatitis sustained cardiorespiratory arrest due to tension pneumothorax after a Swan-Ganz catheter placement. Despite recovering cardio-respiratory function, he did not regain consciousness. Three months later, he seemed awake, but did not answer questions, follow commands, blink to threat or exhibit purposeful movements. He had spastic quadraparesis, decerebrate posturing in response to noxious stimuli, sustained ankle clonus and bilateral Babinski sign. The electroencephalogram showed burst-suppression. MRI revealed cerebral atrophy with diffuse gray matter loss. Hyperintense signal involving remnants of the cerebral cortex (arrows) and basal ganglia (arrowheads) was also appreciated. Before falling ill, the patient casually manifested his wishes of not receiving life-sustaining therapies if he suffered irreversible brain injury. Medications and tube-feedings were discontinued.



From the Universidad Autonoma de Tamaulipas, School of Medicine, Tampico, Mexico (Dr. Pilar Acosta), Clinical Assistant Professor of Neurology, University of Texas Health Science Center at Houston Medical School, Houston, Texas (Dr. Lucas Restrepo) and Professor, The University of Texas Health Science Center, Houston, Texas (Dr. Joseph Varon).

Address requests for reprints to:

Joseph Varon, MD, FACP, FCCP, FCCM, 2219 Dorrington Street, Houston, Texas 77030
Tel. +1-713-669-1670, Fax. +1-713-669-1671, E_mail: Joseph.Varon@uth.tmc.edu



*“...I could not
Speak, and my eyes failed, I was neither
Living nor dead, and I knew nothing,
Looking into the heart of light, the silence.”
T.S. Eliot, The Waste Land*