

The case of the malpositioned feeding tube... while in plain sight

Thomas Lynch V, Brian T. Wessman

Patient WS is a 63-year-old male who presented to the Emergency Department (ED) with a chief complaint of progressive shortness of breath (SOB) over the past two weeks. Associated symptoms at time of presentation included acute bilateral lower extremity edema, orthopnea, and paroxysmal nocturnal dyspnea. His past medical history was significant for diabetes mellitus type II, hypertension, hypothyroidism, paroxysmal atrial fibrillation, paroxysmal ventricular fibrillation, non-ischemic cardiomyopathy (ejection fraction of 25%), severe mitral valve regurgitation, and newly diagnosed adenocarcinoma of the colon. The patient's surgical history was significant for bi-ventricular ICD placement and gastric sleeve surgery. He was admitted to the hospital from the ED for acute on chronic heart failure. During his hospital course, he was deemed a surgical candidate for his colon cancer with planned resection. However, it was felt that he needed medical optimization for his heart failure (admission echo showing a diminished ejection fraction of approximately 16% with biventricular wall motion abnormalities).

His hospital course included placement of an Impella ventricular assist device for his severe heart failure on hospital day (HD) 9. This was then converted to a Heartmate II left ventricular assist device (LVAD), on HD 14. The LVAD placement was complicated by anemia of acute blood loss, innominate vein injury, a brief cardiac arrest, and right heart failure. During his operative case, he had right-sided extra-corporeal membrane oxygenation (RECMO) placed for his acute on chronic right sided heart failure. His RECMO circuit was

eventually exchanged to an external right ventricular assist device (RVAD). During his prolonged ICU stay, the patient regained mental status and was following commands.

WS underwent tracheostomy for his prolonged respiratory failure and inability to wean from ventilator. Throughout his ICU stay, he remained on continuous renal replacement therapy for acute kidney failure. On HD 42 he underwent a transesophageal echocardiogram (TEE) to evaluate his right heart function. During this procedure, his Doppoff feeding tube was removed per standard practice to facilitate TEE probe placement.

After the TEE procedure, his enteral access (Doppoff feeding tube) was replaced using Cortrak technology with confirmation by conventional chest radiography (CXR). The Cortrak images were normal for gastric placement (**Figure 1**); however, did not demonstrate progression into the small bowel (stylet crossing midline). A confirmatory CXR (per ICU standard protocol), reviewed by a junior-level housestaff, was misinterpreted as adequate gastric placement with a confirmatory nursing order provided to use the gastric tube. Further review of the CXR clearly demonstrates the Doppoff enteral access tube in the left lower lobe (**Figure 2**). Subsequently, the patient received a small amount of liquid medication through the tube and subsequently began to desaturate.

On initial evaluation with bedside surface echocardiogram, he was found to have an under-filled left ventricle and dilated right ventricle. After adjustment of the RVAD flow, the patient remained hypoxic, and an emergent bronchoscopy was performed. At the time of bronchoscopy, the ICU team was under the impression that the Doppoff was appropriately positioned in the stomach. Bronchoscopy findings included visualization of the feeding tube in the left lung with large left main stem bronchus plug (**Figure 3**). The Doppoff was immediately removed. Aggressive measures were instituted for lavage and removal of the extensive mucus plug burden. Over the next several days, WS continued to suffer from his ongoing multi-system organ failure. Continued goals of care discussions were held with family members with a

From Washington University in St. Louis, School of Medicine, Missouri, USA (Thomas Lynch V and Brian T. Wessman).

Address for correspondence:

Brian T. Wessman, MD, FACEP, FCCM
Washington University in St. Louis, School of Medicine
660 South Euclid Ave, St. Louis, MO 63110, USA
Tel: 314-747-3581 (work)
Email: brianwessman@wustl.edu

subsequent decision made to transition to comfort care. WS subsequently passed away.

Enteral access is a common necessity in the critically ill patient, with an estimated 1.2 million styleted feeding tubes placed every year in the United States. (1) The blind placement of enteral feeding tubes is a daily practice in the ICU setting. One of the most common complications is misplacement, specifically in the tracheobronchial tree. This occurs about 1.9% of the time. (2) Raszias and colleagues looked at 740 patients with a similar complication rate, and 2/14 (14%) had the confirmatory chest x-ray misread. (3)

Cortrak is a U.S. Food Drug and Administration (FDA) approved device to aid in the placement of small-bore styletated feeding tubes into the small bowel and limit the need for confirmatory radiography. It uses electromagnetic detection to trace the path of feeding tube. Therefore, gastric and pulmonary placement can appear similar (due to their overlying anatomical planes). Using Cortrak adds an additional layer of patient safety and assistance in placing feeding tubes, however it does not replace CXR confirmation. Metheny's 2014 review article demonstrated that there is small percentage of cases where despite correct Cortrak images, the feeding tube is malpositioned. (1) At the time of that publication, there were 21 cases identified

from the MAUDE (FDA manufacturer and user facility device experience) database. Of these 21 cases, at least 2 had the CXR misinterpreted. Besides malpositioning, the overall complication rate with the use of Cortrak also includes 17 self-reported cases of pneumothoraces in the MAUDE database. As this database depends on self-reporting, it is presumed that the overall rate of enteral tube misplacement maybe higher.

Many medical myths have been propagated about confirmation of nasogastric tube (NGT) placement. One major myth include insufflation for confirmation and aspiration of fluid, both which have been demonstrated to be unreliable. (4,6) Another major myth is that endotracheal intubation will prevent the feeding tube from entering the tracheobronchial tree. (5,6) Sorokin, et al demonstrated in a review of 187 enteral tube misplacements that 60.4% were placed in patients with cuffed endotracheal tubes. (2) The gold standard for tube placement confirmation is still considered confirmatory radiography imaging reviewed by a seasoned clinician. (6) The major point to remember is that when placing NGT, whether large bore Salem sump tubes or Doppoff tubes for feeding, they should be confirmed with radiographic imaging reviewed by a seasoned clinician prior to infusing anything through them.

Figure 1. Cortrak image from enteral tube placement showing presumed gastric placement (red tip that does not cross midline)


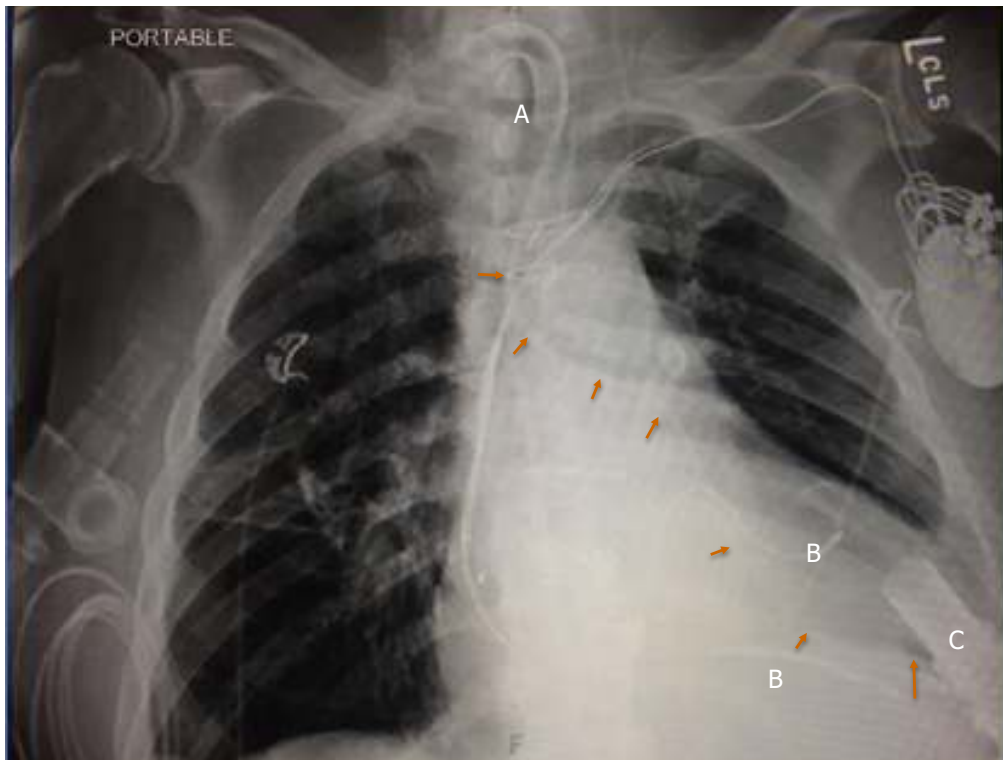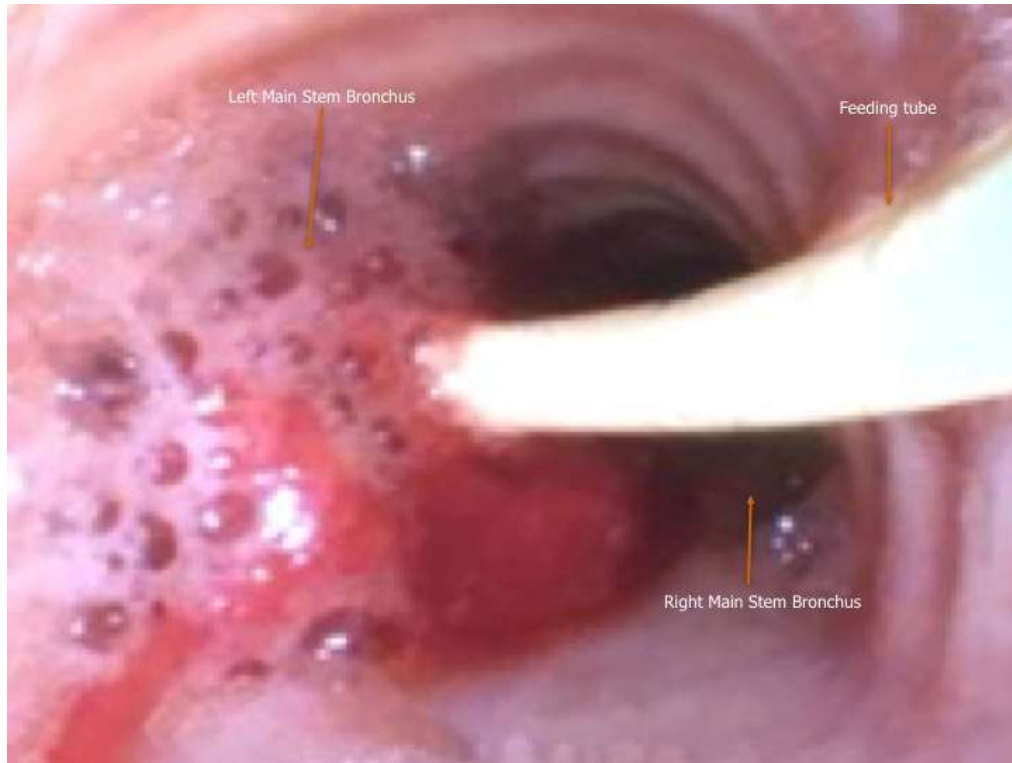


Figure 2. Chest radiograph demonstrating malpositioned feeding tube following the left main bronchus (closed arrows)



Legend: A=tracheostomy tube; B=pacer/defibrillator wire; C=left ventricular assist device cannula

Figure 3. Bedside emergent bronchoscopy showing carinal rings, left/right main stem bronchus (solid arrow/label), and demonstrating the yellow small bowel feeding tube (solid arrow/label) malpositioned in the left mainstem bronchus



References

1. Metheny NA, Meert KL. Effectiveness of an Electromagnetic Feeding Tube Placement Device in Detecting Inadvertent Respiratory Placement. *Am J Crit Care* 2014;23:240-7.
2. Sorokin R, Gottlieb JE. Enhancing Patient Safety during feeding tube insertion: A review of more than 2,000 insertions. *JPEN J Parenter Enteral Nutr* 2006;30:440-5.
3. Rassias AJ, Ball PA, Corwin HL. A prospective study of tracheopulmonary complications associated with the placement of narrow-bore enteral feeding tubes. *Crit Care* 1998;2:25-8.
4. Simons SR, Abdallah LM. Bedside Assessment of Enteral Tube Placement: Aligning Practice with Evidence. *Am J Nurs* 2012;112:40-8.
5. Sparks DA, Chase DM, Coughlin LM, Perry E. Pulmonary Complications of 9931 Narrow-Bore Nasoenteric Tubes During Blind Placement: A Critical Review. *JPEN J Parenter Enteral Nutr* 2011;35:625-9.
6. Stayner JL, Bhatnagar A, McGinn AN, Fang JC. Feeding Tube Placement: Errors and Complications. *Nutr Clin Pract* 2012;27:738-48.