

Acute Confusion: An Unusual Presentation of Miliary Tuberculosis

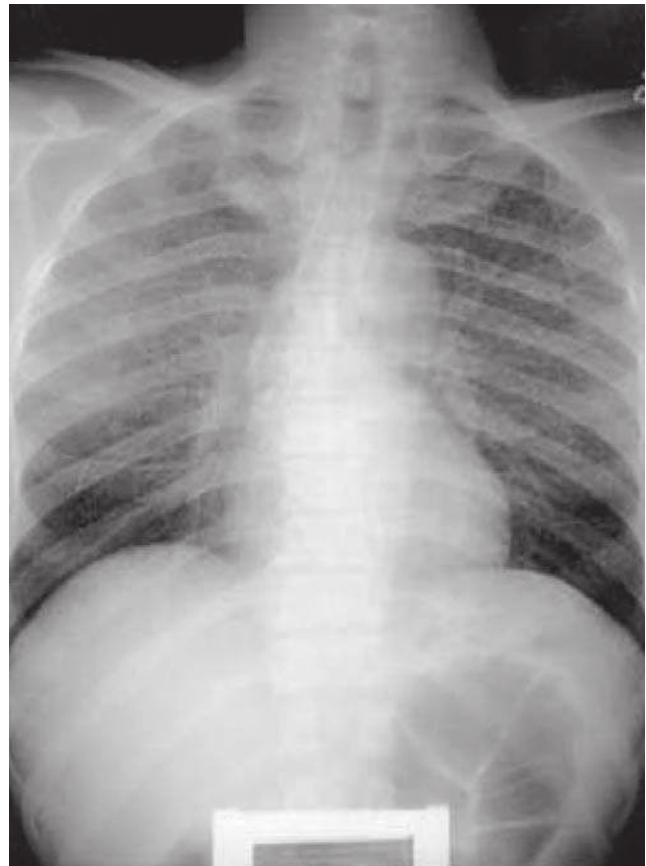
Salim Surani, Alim Nagji, Barbara Estement, Subham Manchada, Joseph Varon, Pilar Acosta

Case Report

A middle aged African-American gentleman was brought to the emergency department by the emergency medical services with altered mental status. The patient was found confused, malnourished and in mild respiratory distress. On initial assessment he was found to be mildly hypoxemic. Chest X-ray on arrival revealed a miliary pattern, consistent with miliary tuberculosis (**Figure 1**). A computed tomography (CT) scan of the head revealed a left parietal mass with surrounding edema (**Figure 2**). The patient underwent lumbar puncture, bronchoscopy with bronchoalveolar lavage (BAL), blood and urine cultures. Because of the high suspicion of miliary tuberculosis the patient was started on a four drug anti-tuberculosis regimen. A magnetic resonance imaging (MRI) with and without contrast showed multiple enhancing lesions with enhancement of the leptomeninges and an image consistent with tuberculomas (**Figure 3**). Stains for acid fast bacilli (AFB) done in sputum, BAL, cerebrospinal fluid, and urine were negative. After a period of six weeks all cultures were positive for *Mycobacterium tuberculosis*.

Clinical presentation of miliary tuberculosis is highly variable. Patients that present with central nervous system disease such as meningitis or tuberculoma is seen in up to 20% of the cases. Meningeal involvement is usually seen in up to 54% of the cases of miliary tuberculosis, and in just a few minority of patients the AFB smears are positive.

Figure 1. MILIARY PATTERN ON CHEST X-RAY



From Texas A&M University, Corpus Christi, Texas ((Drs Salim Surani and Barbara Estement), University of Texas Dallas (Subham Manchada), McMaster University, Hamilton, Ontario, Canada (Dr. Alim Nagji), The University of Texas Health Science Center, Houston, Texas (Dr. Joseph Varon), and Dorrington Medical Associates, Houston, Texas (Pilar Acosta).

Address for correspondence:

Salim Surani, MD, MPH, FCCP, FACP.
613 Elizabeth Street Suite 813
Corpus Christi, Texas 78404 USA
Email: srsurani@hotmail.com

Figure 2. LEFT PARIETAL MASS WITH SURROUNDING EDEMA

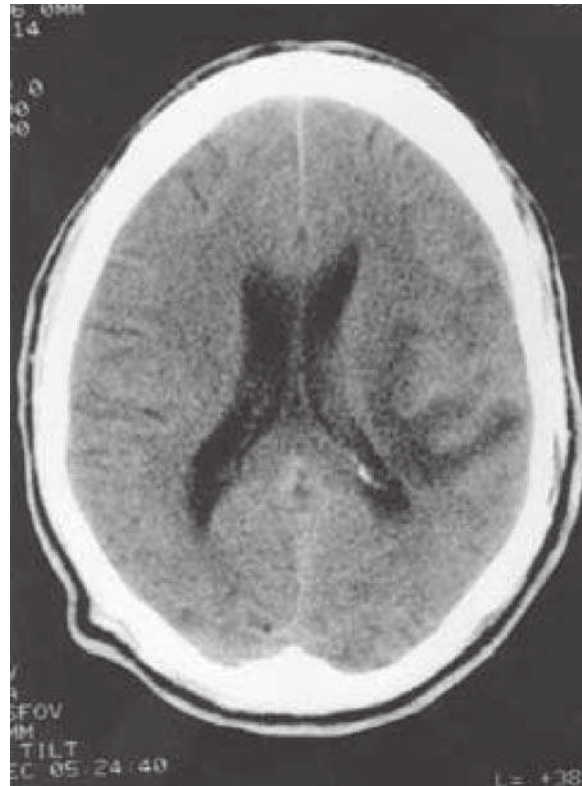


Figure 3. T1 IMAGES WITH MULTIPLE ENHANCING LESIONS

