

# An Unusual Presentation of Staphylococcal Induced Paravertebral Myositis Causing Septic Shock

J. O'Leary, M. Kelleher, C. Motherway

## Abstract

**Background:** Paravertebral myositis is uncommon, and this case highlights a number of important therapeutic and diagnostic considerations. We discuss the role of appropriate antimicrobial therapy and the potential dilemma regarding the use of immunoglobulin in the septic patient. The key elements of treatment are early recognition, and the early initiation of appropriate antibiotics, typically a  $\beta$ -lactamase resistant anti-staphylococcal agent and clindamycin. Clindamycin is added to anti-staphylococcal treatment due to its ability to reduce exotoxin production, a result of its ability to

suppress translation of toxin genes.

**Methods:** We present a case report of a *Staphylococcus aureus* (*S. aureus*) induced paravertebral myositis resulting in septic shock.

**Conclusions:** It remains that the role of IVIG in the management of sepsis is as yet not clearly defined, at present it is neither advocated nor dismissed by current guidelines, given the presence of both positive and negative findings in recent meta-analysis.

**Key words:** Sepsis, immunoglobulins, Staphylococcus, Staphylococcus aureus, myositis

## Introduction

We report a case of a *Staphylococcus aureus* (*S. aureus*) induced paravertebral myositis resulting in septic shock. Paravertebral myositis is uncommon, and this case highlights a number of important therapeutic and diagnostic considerations. We discuss the role of appropriate antimicrobial therapy and the potential dilemma regarding the use of immunoglobulin in

the septic patient. The role of immunoglobulin in the management of sepsis remains controversial [1] with recent meta-analysis differing in their recommendations [2,3,4,5].

## Case history

A 19 year-old man presented to hospital with a 7 day history of right sided lower back pain and flu-like symptoms. He had been attending his general practitioner with a diagnosis of musculo-skeletal back pain. He had no significant co-morbidities, and was taking non-steroidal anti-inflammatory drugs and diazepam on a PRN basis for the preceding 3 days. Of note, he was allergic to penicillins. Within 12 hours of admission he deteriorated clinically, becoming haemodynamically unstable (BP 68/45 mmHg),

---

From Department of Anaesthesia and Intensive Care Medicine, Mid-Western Regional Hospital, Limerick, Ireland (Drs. James O'Leary, M. Kelleher, and C. Motherway)

### Address for correspondence:

Dr. James O'Leary

Department of Anaesthesia and Intensive Care Medicine, Mid-Western Regional Hospital

Limerick, Ireland.

Tel: 00-353-61-301111

Fax: 00-353-61-306927

Email: jamesol1980@hotmail.com

requiring  $\text{FiO}_2$  0.4 via a Venturi mask to maintain oxygen saturation  $>95\%$ . He was pyrexial ( $38.5^\circ\text{C}$ ), and anuric, but maintained a Glasgow Coma Scale of 15/15. Examination revealed a desquamating erythematous rash extending from his trunk to his lower limbs. A clinical diagnosis of possible toxic shock syndrome (TSS) was made and he was transferred to the Intensive Care Unit (ICU) for ongoing care.

Electrocardiogram and initial chest X-ray were normal. Laboratory tests, at this time, revealed a white cell count (WCC) of  $5.94 \times 10^9 \cdot \text{litre}^{-1}$  (neutrophils  $5.51$ , lymphocytes  $0.08$ , and monocytes  $0.21 \times 10^9 \cdot \text{litre}^{-1}$ ), urea  $12.5 \text{ mmol} \cdot \text{litre}^{-1}$ , creatinine  $272 \text{ mmol} \cdot \text{litre}^{-1}$ , erythrocyte sedimentation rate (ESR)  $7 \text{ mm} \cdot \text{h}^{-1}$ , and lactic acid of  $8.50 \text{ mmol} \cdot \text{litre}^{-1}$ . His International Normalized Ratio (INR) was elevated at 1.9. APACHE II score on admission to ICU was 14. Further investigations included trans-thoracic echocardiography which was unremarkable, and in particular did not reveal any abnormalities nor vegetations. Computerized tomography of his abdomen performed to rule out paravertebral or intra-abdominal collections was negative. Due to the clinical presentation and severity of disease, as well as the patient gave a history of soft tissue swelling following administration of penicillins; he was initially commenced on intravenous Vancomycin. Subsequently *S. aureus* was isolated from separate peripheral blood cultures after only 17 and 22 hours incubation and clindamycin was introduced. At this time, given the patients ongoing lumbar symptoms, it was decided to proceed to image his lumbar spine using magnetic resonance imaging (MRI) to rule out a para-spinal abscess. The patient was sedated and intubated prior to this procedure. The MRI demonstrated high signal change in the right sided paravertebral tissues at the L4/L5 level suggestive of a myositis. This did not involve the epidural space and there was no abscess or focal fluid collection seen (**Figures 1 and 2**).

He was treated supportively, according to Surviving Sepsis guidelines [5]. This included fluid loading, inotropes, respiratory support, and targeted antimicrobial therapy. In addition, an initial dose of  $2 \text{ g} \cdot \text{kg}^{-1}$  of human normal immunoglobulin, Intratect®

( $50 \text{ g} \cdot \text{litre}^{-1}$ , of which at least 96% is immunoglobulin G (IgG)), was administered over a period of 24 hours. This was followed by  $0.4 \text{ g} \cdot \text{kg}^{-1} \cdot 24 \text{ hrs}^{-1}$ , for 4 days. He made a rapid recovery over several days, was extubated on day 5, and was discharged home on day 19. Of note, on subsequent investigation complement levels were normal, HIV antibodies negative, and superantigen (SAg) D was isolated from the initial blood cultures. Follow-up was uneventful, and he made a complete recovery.

## Discussion

The case describes a young man presenting with vague, non-specific, symptoms who quickly developed septic shock and multi-organ dysfunction secondary to *S. aureus* infection.

*S. aureus*, a Gram positive coccus, is a common commensal organism [6]. In this case, *S. aureus* was a potent source of infection causing septic shock, as defined by the International Surviving Sepsis guidelines [7,8]. Of note, the *S. aureus* isolated here was a secretor of super antigen D (SAg D). This presentation does not fulfill the defining criteria of the Centers for Disease Control and Prevention for TSS [9]. It does however share several features of TSS, most typically the diffuse desquamating erythematous rash with rapid onset of multi-organ dysfunction syndrome, and can be classified as a probable case. The key elements of treatment of TSS are early recognition, and the early initiation of appropriate antibiotics, typically a  $\beta$ -lactamase resistant anti-staphylococcal agent and clindamycin [10]. Clindamycin is added to anti-staphylococcal treatment due to its ability to reduce exotoxin production by both methicillin sensitive and methicillin resistant *S. aureus*. Recent studies suggest this effect is due to its ability to suppress translation of toxin genes, in a similar manner to linezolid, a newer anti-staphylococcal agent [11].

The pathophysiology of sepsis is thought to be due to an imbalance between pro- and anti-inflammatory mediators produced by toxin activated cells [12]. As already mentioned in this case SAg D was identified in

the weeks following presentation. Super antigens are most commonly secreted by *S. aureus*, or *Streptococcus pyogenes*, and exhibit highly potent lymphocyte-transforming activity directed towards T-lymphocytes and can cause a massive non-specific immune response [10,13]. In this instance, the low ESR (7 mm.h<sup>-1</sup>) in the face of septic shock with a markedly elevated serum lactate level indicates that this presentation was possibly predominantly toxin mediated. Confirmation of the presence of toxin production is usually confirmed days after the clinical presentation.

Intravenous immunoglobulin (IVIG) may modulate the immune response in sepsis by neutralizing bacterial endo- and exotoxins, and increasing anti-inflammatory mediators [13]. The use of IVIG has been described extensively in the management of sepsis [2,3,14-17], but its role in sepsis remains controversial [1]. It does not form part of the Surviving Sepsis guidelines for adults, but its potential benefit in the management of pediatric septic shock, while not proven, is acknowledged [7].

There is a lack of high quality trials examining the role of IVIG in sepsis, as demonstrated by Pidal *et al*, in a recent meta-analysis [3]. These authors found that trials were underpowered and differed in their definition of sepsis, severe sepsis and septic shock, making analysis and comparison difficult. They found no survival benefit with the use of IVIG in sepsis compared to placebo or no intervention [3].

A meta-analysis by Turgeon *et al* observed a 26% survival benefit in 20 trials conducted in 2621 patients [2]. This is at odds with the meta-analysis performed by Pidal *et al*, which included 16 of the same trials as Turgeon *et al*, but differed in that the latter included pediatric and neonatal trials. A Cochrane review in 2002, also included 5 neonatal trials, and in subgroup analysis of adults they demonstrated a clear survival benefit with the use of polyclonal IVIG in sepsis [4].

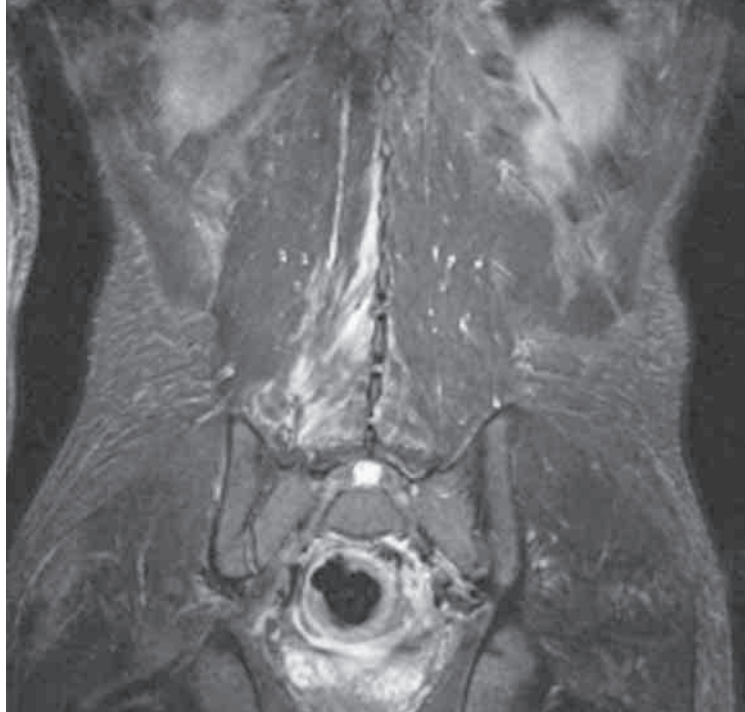
More recently, Laupland *et al* using meta-analysis demonstrated an overall reduction in mortality with the use of IVIG for the adjunctive treatment of severe sepsis and septic shock in adults; although this result was not confirmed when only high-quality studies were analyzed [5].

These meta-analysis [2,3], as well as a randomized, controlled trial by Hentrich *et al*, support the role of IVIG in the more severely ill patient (APACHE >25), with those patients having two or more dysfunctional organs most likely to gain a beneficial treatment effect [2,3,18]. The benefit of IVIG therapy was also most prominent in severe sepsis when higher doses were used for longer periods [2,3,5].

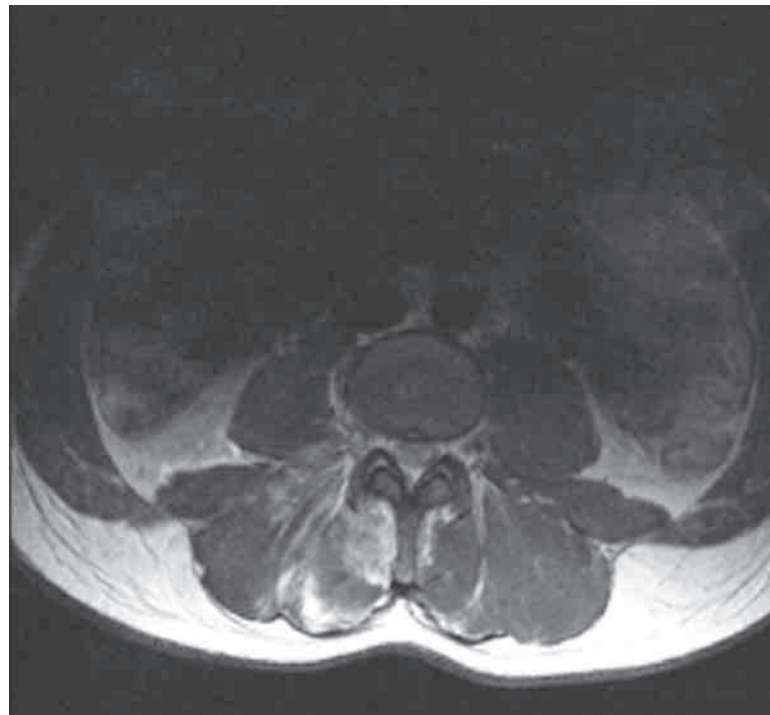
## Conclusions

We have presented a case of septic shock with an unusual source, *S. aureus* induced paravertebral myositis. This case serves as a reminder of the importance of early implementation of the Surviving Sepsis treatment bundles [7]. It also highlights the role of appropriate anti-microbial therapy in the treatment of *S. aureus* induced sepsis. In this instance, recognizing that although a  $\beta$ -lactamase resistant anti-staphylococcal agent is first choice in the treatment of *methicillin sensitive Staphylococcus aureus*, given the patient's diagnosis and a known allergy to penicillins, the introduction of vancomycin and clindamycin was appropriate. The role of appropriate imaging in the diagnostic process is highlighted as the source of sepsis was identified by MRI but not CT. In this case we chose to use IVIG given our clinical suspicion of TSS. It remains however that the role of IVIG in the management of sepsis is as yet not clearly defined. At present it is neither advocated nor dismissed by current guidelines [7], given the presence of both positive and negative findings in recent meta-analysis [2,3,5].

**Figure 1.** MAGNETIC RESONANCE IMAGING (CORONAL VIEW) DEMONSTRATING HIGH SIGNAL CHANGE IN THE RIGHT SIDED PARA-VERTEBRAL TISSUES AT THE L4/L5 LEVEL SUGGESTIVE OF A MYOSITIS



**Figure 2.** MAGNETIC RESONANCE IMAGING (AXIAL VIEW) DEMONSTRATING HIGH SIGNAL CHANGE IN THE RIGHT SIDED PARAVERTEBRAL TISSUES AT THE L4/L5 LEVEL SUGGESTIVE OF A MYOSITIS



## References

1. Werdan K (2006) Immunoglobulin treatment in sepsis--is the answer "no"? *Crit Care Med* 34:1542-1544
2. Turgeon AF, Hutton B, Fergusson DA, McIntyre L, Tinmouth AA, Cameron DW, Hébert PC (2007) Meta-analysis: intravenous immunoglobulin in critically ill adult patients with sepsis. *Ann Intern Med* 146:193-203
3. Pildal J, Gøtzsche PC (2004) Polyclonal immunoglobulin for treatment of bacterial sepsis: a systematic review. *Clin Infect Dis* 39:38-46
4. Alejandria MM, Lansang MA, Dans LF, Mantaring JB (2002) Intravenous immunoglobulin for treating sepsis and septic shock. *Cochrane Database Syst Rev* (1):CD001090
5. Laupland KB, Kirkpatrick AW, Delaney A (2007) Polyclonal intravenous immunoglobulin for the treatment of severe sepsis and septic shock in critically ill adults: a systematic review and meta-analysis. *Crit Care Med* 35:2686-2692
6. Foster TJ (2004) The *Staphylococcus aureus* "superbug". *J Clin Invest* 114:1693-1696
7. Dellinger RP, Carlet JM, Masur H, Gerlach H, Calandra T, Cohen J, Gea-Banacloche J, Keh D, Marshall JC, Parker MM, Ramsay G, Zimmerman JL, Vincent JL, Levy MM; Surviving Sepsis Campaign Management Guidelines Committee (2004) Surviving Sepsis Campaign guidelines for management of severe sepsis and septic shock. *Crit Care Med* 32:858-873
8. (1992) American College of Chest Physicians/ Society of Critical Care Medicine Consensus Conference: Definition for sepsis and organ failure and guidelines for the use of innovative therapies in sepsis. *Crit Care Med* 20:864-874
9. Centers for Disease Control and Prevention (1997) Toxic-Shock Syndrome (TSS). <http://www.cdc.gov/epo/dphsi/casedef/toxicsscurent.htm>
10. McCormick JK, Yarwood JM, Schlievert PM (2001) Toxic shock syndrome and bacterial superantigens: an update. *Annu Rev Microbiol* 55:77-104
11. Stevens DL, Ma Y, Salmi DB, McIndoo E, Wallace RJ, Bryant AE (2007) Impact of antibiotics on expression of virulence-associated exotoxin genes in methicillin-sensitive and methicillin-resistant *Staphylococcus aureus*. *J Infect Dis* 195:202-211
12. Hotchkiss RS, Karl IE (2003) The pathophysiology and treatment of sepsis. *N Engl J Med* 348:138-150
13. Alouf JE, Müller-Alouf H (2003) Staphylococcal and streptococcal superantigens: molecular, biological and clinical aspects. *Int J Med Microbiol* 292:429-440
14. Rodríguez A, Rello J, Neira J, Maskin B, Ceraso D, Vasta L, Palizas F (2005) Effects of high-dose of intravenous immunoglobulin and antibiotics on survival for severe sepsis undergoing surgery. *Shock* 23:298-304
15. De Simone C, Delogu G, Corbetta G (1988) Intravenous immunoglobulins in association with antibiotics: a therapeutic trial in septic intensive care unit patients. *Crit Care Med* 16:23-26
16. Darenberg J, Ihendyane N, Sjölin J, Aufwerber E, Haidl S, Follin P, Andersson J, Norrby-Teglund A; StreptIg Study Group (2003) Intravenous immunoglobulin G therapy in streptococcal toxic shock syndrome: a European randomized, double-blind, placebo-controlled trial. *Clin Infect Dis* 37:333-340
17. Kaul R, McGeer A, Norrby-Teglund A, Kotb M, Schwartz B, O'Rourke K, Talbot J, Low DE (1999) Intravenous immunoglobulin therapy for streptococcal toxic shock syndrome--a comparative observational study. The Canadian Streptococcal Study Group. *Clin Infect Dis* 28:800-807
18. Hentrich M, Fehnle K, Ostermann H, Kienast J, Cornely O, Salat C, Uebelacker R, Buchheidt D, Behre G, Hiddemann W, Schiel X (2006) IgMA-enriched immunoglobulin in neutropenic patients with sepsis syndrome and septic shock: a randomized, controlled, multiple-center trial. *Crit Care Med* 34:1319-1325