

A case of anaphylactic shock due to an uncommon cause

Diana Cimpoesu, Lucian Stoica, Antoniu Petris, Joseph Varon

Editor-in-Chief Introductory Note

In this new section of the Journal, we present a clinical case followed by the different steps taken by the medical team caring for this critically ill patient. A description of the events is true and accurate, and the diagnosis established in the order in which it is presented. A series of images depict the primary issues encountered by the authors. In addition, the authors include selected references to complement and enhance the educational value of this article.

Case Presentation

A 20-year-old man was brought by ambulance to the emergency department (ED) of our hospital, with a Glasgow Coma Score (GCS) of 6, endotracheal intubation and mechanical ventilation after respiratory arrest in the pre-hospital setting. He collapsed during physical effort, working in a garden. No medical history except two ED presentations, in some other hospital, for shortness of breath, without any specific diagnosis that the relatives could tell the medical team. Physical exam in ED revealed a patient with GCS 6, receiving benzodiazepine before airway management in pre-hospital, with the signs of anaphylactic shock manifested by facial edema, edema of the upper lip, bronchial hypersecretion, BP 60/40 mmHg, heart rate 110/min. Physical examination showed no other pathological signs. Twelve-lead electrocardiogram revealed sinus tachycardia. The ED treatment included high-flow oxygen through the endotracheal tube, intravenous epinephrine, steroids, fluids and fresh frozen plasma.

From University of Medicine and Pharmacy "Gr. T. Popa" Iasi, Romania, Emergency County Hospital "Sf. Spiridon" Iasi, Romania, and Institute of Cardiovascular Diseases "Prof. Dr. George I. M. Georgescu" Iasi, Romania (Diana Cimpoesu, Lucian Stoica, and Antoniu Petris), and Department of Critical Care Services, University General Hospital, Houston, Texas, USA (Joseph Varon).

Address for correspondence:

Joseph Varon, MD, FACP, FCCP, FCCM, FRSM
2219 Dorrington Street
Houston, Texas 77030, USA
Tel: +1-713-669-1670
Fax: +1-713-669-1671
Email: Joseph.Varon@uth.tmc.edu

Based on the physical examination, his anaphylaxis was real, but what was the etiology?

History obtained from his relatives did not indicate any recent allergen exposure. To identify the etiology of anaphylactic shock, laboratory and imaging data were obtained. First, suspicion arised from FAST ultrasonography (performed by the emergency physician in ED during the first assessment and resuscitation efforts), which found some fluid accumulations on the lateral left ventricular wall in the pericardial sac (**Figure 1**). A complete blood count (CBC) revealed leukocytosis WBC $24.2 \times 10^3/\mu\text{L}$ (Ly 7.6%, Mo 2.6%, GR 89.8%) with PLT $356 \times 10^3/\mu\text{L}$. Other results included a serum lactate 10.0 mmol/L, fibrinogen 1.93 mg%, blood glucose 129 mg/dL. Arterial blood gases while receiving supplemental oxygen showed a pH 7.28, pCO₂ 39 mmHg, pO₂ 91 mmHg, Na 141 mEq/L, K 3.3 mEq/L, Ca²⁺ 1.10 mmol/L and coagulation disturbance: PT 31.7 sec, AP 26.255, INR 2.75, APTT unable to clot. Chest radiograph depicted few encapsulated, homogeneous cystic lesions 25 mm x 30 mm near the left ventricle (**Figure 2**), confirmed by thoracic and trans-esophageal echocardiography (**Figure 3**). Contrast-enhanced computed tomography (CT) scan was performed and revealed a well-defined, thin-walled, multiple liquid formations at the heart apex and near aorta within 10 to 45 mm diameter (**Figure 4**).

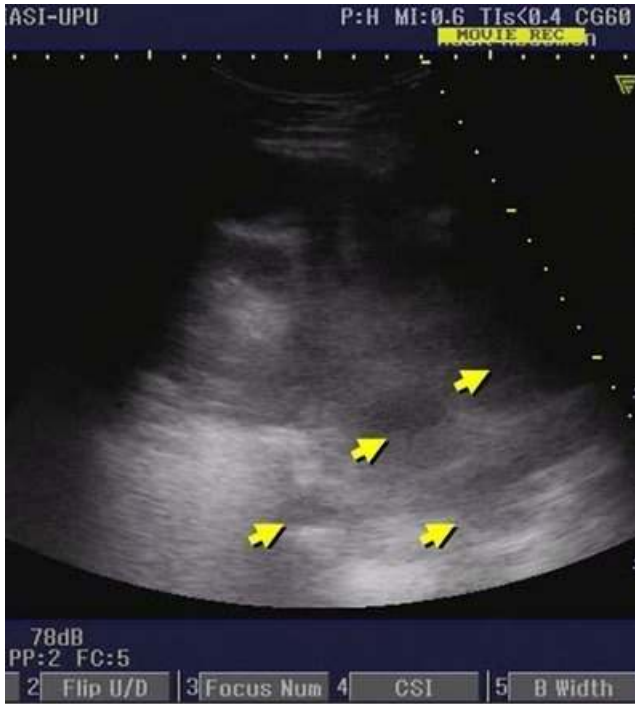What is the diagnosis?

Anaphylactic shock due to broken intra-pericardial multiple hydatid cysts.

Discussion

Hydatid disease is a worldwide zoonosis caused by the larval stage of the Echinococcus (most frequently *E. granulosus* and *E. multilocularis*). The disease is endemic in cattle and sheep in the rearing region of the world and sporadic in the European countries. The

Figure 1. FAST ultrasonography performed by emergency physician



Legend: Arrows indicate cystic areas of fluid accumulation.

Figure 2. Chest radiograph performed in the ED and enlarged cardiovascular silhouette with abnormal heart borders

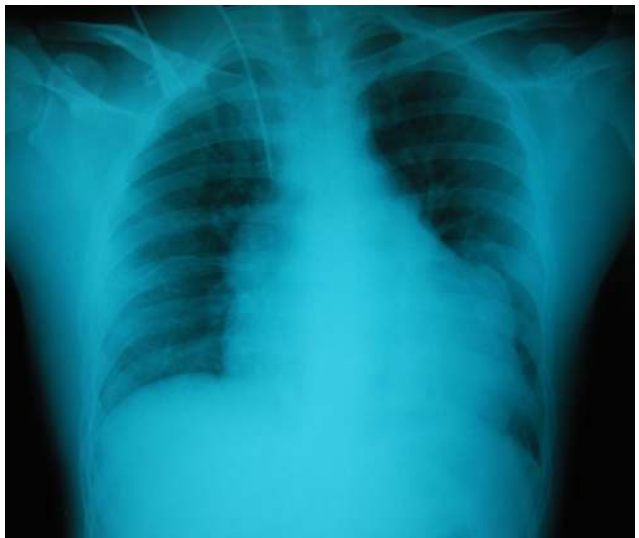

Figure 3. Transesophageal and transthoracic echocardiography revealing multiple cysts

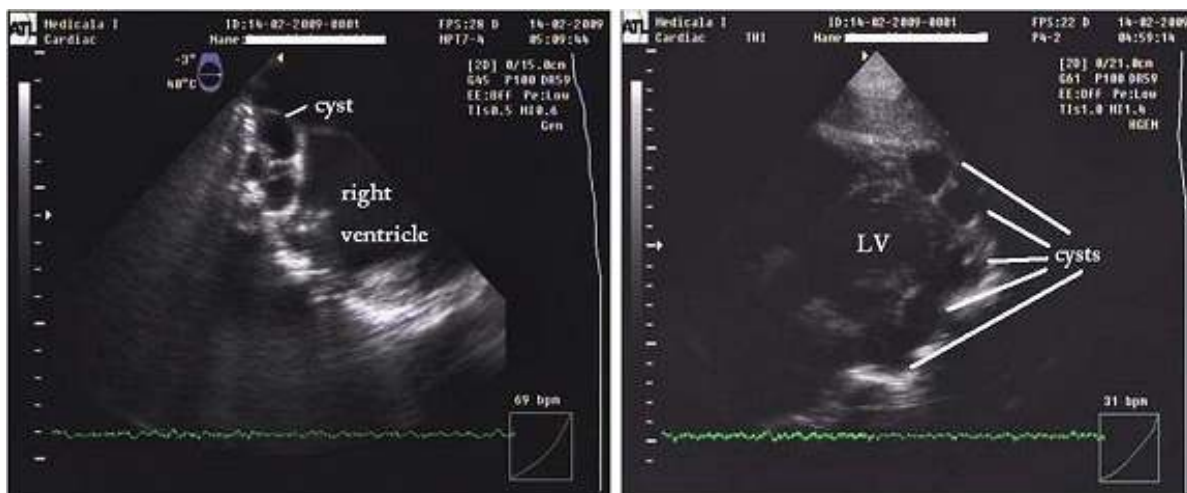


Figure 4. Computed tomography of the chest revealing in the mediastinal windows multiple areas consistent with cysts

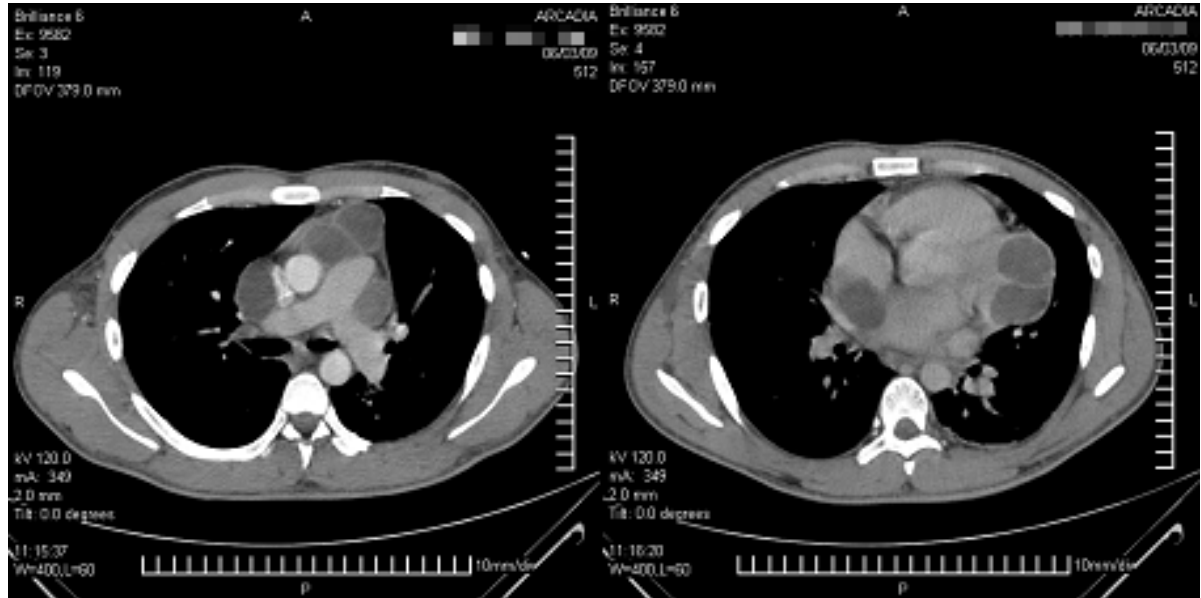


Figure 5. Initial surgical intervention and drainage of the cysts

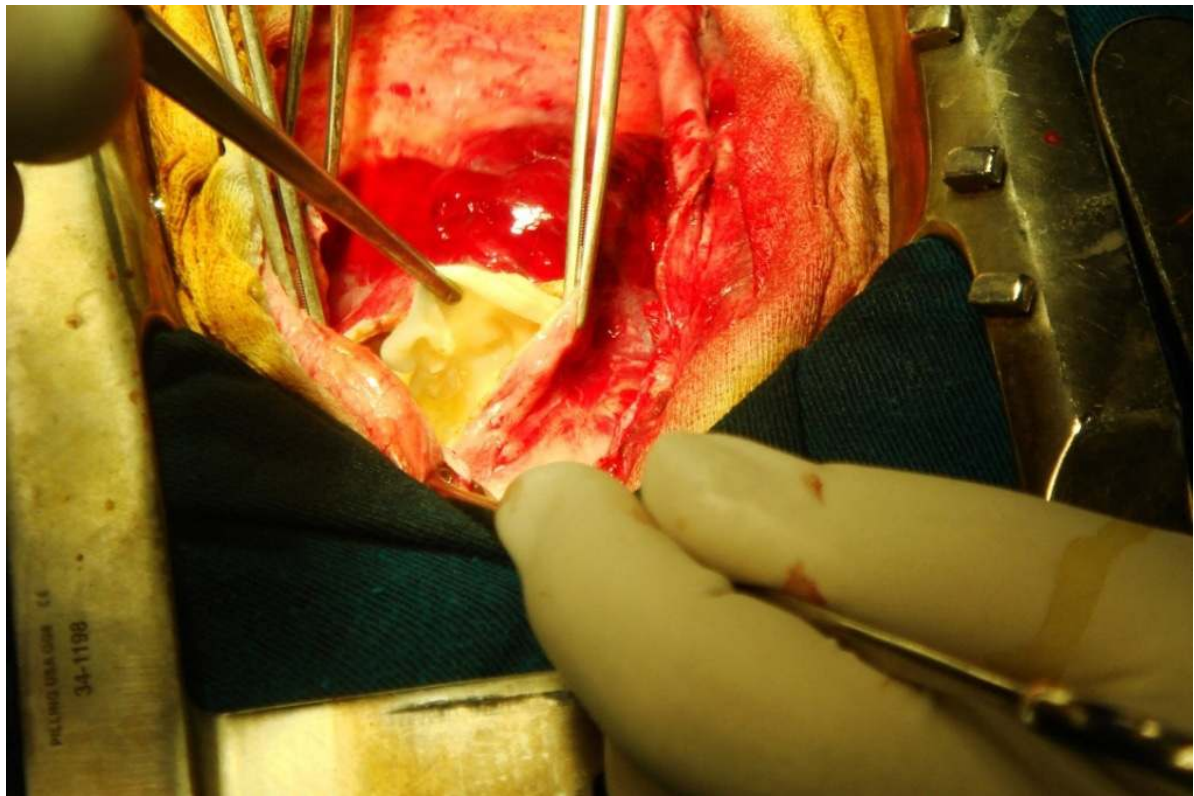
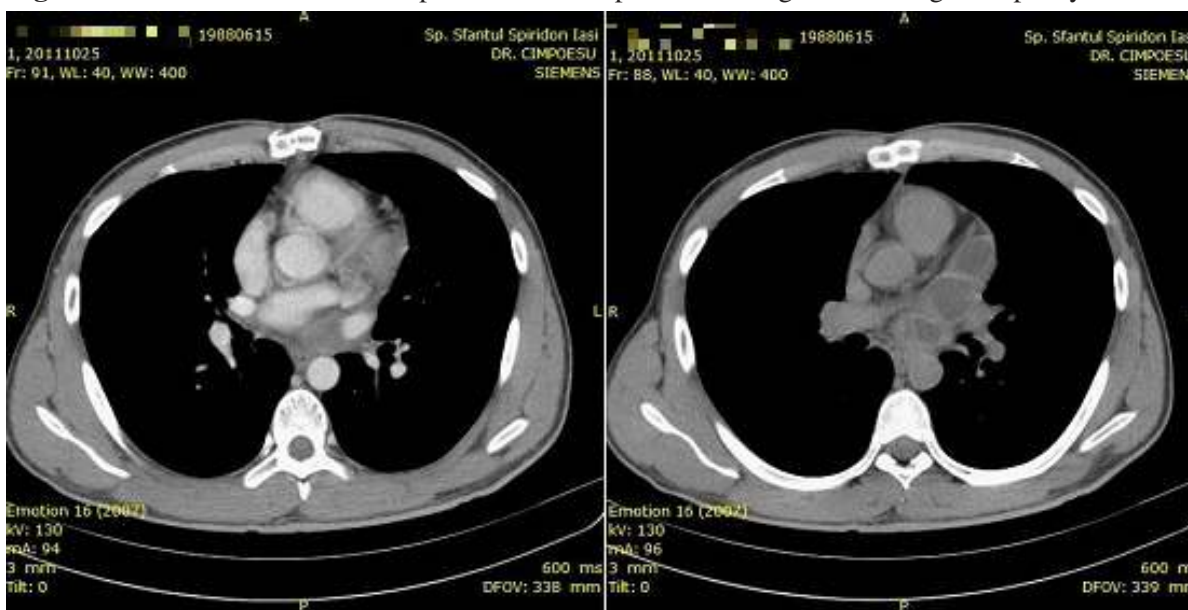


Figure 6. CT scan obtained on the patient's second presentation again revealing multiple cysts



incidence of Echinococcosis in Romania, east European country, is reported to be of 5 cases/100,000 citizens.

Humans become inadvertent intermediate hosts when they ingest eggs from the feces of infected dogs or other canids. Hydatid cysts develop over months or years. Most of them will remain asymptomatic but some of them become large enough to cause symptoms. Hydatid cysts commonly affect the liver and lung though any organ can get affected. The incidence of cardiac involvement is uncommon among patients with hydatid disease (0.5-3%), and a pericardial site of implantation is even less common while presentation with anaphylaxis, as in our case, is even more unusual. As the clinical signs and symptoms of the cardiac and pericardial hydatid cyst are nonspecific and varied, this disease may be difficult to diagnose. Severe complications, as cardiac tamponade or anaphylactic shock impose a prompt diagnosis and treatment in ED for all the life-threatening conditions. Most cases of pericardial echinococcosis may be due to the spreading from an initial location to the liver dome.

The diagnosis relies on the positive serologic testing and imagistic findings. Ultrasonography is particularly useful for the detection of cystic membranes, septa,

and hydatid sand. Computed tomography best demonstrates cyst wall calcification and cyst infection. CT and magnetic resonance imaging may demonstrate cyst wall defects as well as the passage of contents through a defect.

Transthoracic, trans-esophageal echocardiography and abdominal echocardiography can show the intra-pericardial masses. The computed tomography of the chest indicates the diagnosis, localization and approximate number of cysts as well as their connection with the intra-thoracic organs. Imaging characteristics as multi-vesicular cysts, calcification, intra-cystic membranes can sustain the diagnosis of hydatid cyst.

Immunodiagnostic tests like indirect hemagglutination (IHA), indirect fluorescent antibody (IFA) tests, and enzyme immunoassays (EIA) are sensitive tests for detecting antibodies in serum of patients with cystic disease; sensitivity rates vary from 60% to 90%, depending on the characteristics of the cases. The best available serologic diagnosis is obtained by using combinations of tests.

Surgical excision and medical treatment represent the treatment to choose for pericardial hydatid cyst. The drugs of choice for the treatment of echinococcosis is

albendazole or praziquantel. Recurrence more than 2 years after treatment is uncommon, especially if the treatment with albendazole is continued at least for 12 months. Surgical treatment is recommended in the management of cardiac echinococcosis as a result of high associated morbidity and mortality rates.

Clinical Course

With diagnosis of broken intra-pericardial, still intubated with mechanical ventilation and adrenaline on automatic syringe, the patient was admitted into intensive care unit, with complete neurology recovery in 12 hours and stable hemodynamic parameters. The pharmacological therapy with oral albendazole started. The patient was transferred to the cardiac surgery department and multiple cysts of pericardium were removed during cardiac surgery with complete resolution of symptoms. The surgical procedure initiated with a median sternotomy, using extracorporeal circulation (without cross-clamping) and continued with total and partial resection of multiple hydatid cysts, neutralization using hydrogen peroxide, hypertonic sodium chloride (33%) and povidone-iodine and, finally, aspiration of the contents (hydatid liquid and proligera) (**Figure 5**).

Histo-pathologic examination of the masses confirmed the diagnosis of hydatid cysts. After 10 days, the patient was discharged and albendazole therapy was followed for one year.

One year and half later, the patient presented by himself to our ED with anaphylactic signs: edema of the upper lip, vertigo, palpitations and dyspnea. Clinical exam confirmed the lip edema with tachycardia 110/min and BP of 100/60 mmHg without any other pathologic sign. CT scan performed in ED showed the recurrence of multiple pericardial cysts (**Figure 6**) and the patient was admitted again to the critical care unit.

In order to establish the immunodiagnosis, we used the ELISA immunoenzymatic test for IgG antibodies. The result was 9.1 U (the values above 1.1 U are considered positive). The team formed by the emergency physician, the cardiologist, the infection disease specialist and the cardio-vascular surgeon decided the medical treatment anticipating the difficulty of a surgical extraction of multiple cysts (after the first findings of the cardiac surgery intervention) and the suspicion of them being very adherent to the mediastinum structures posed an increased surgical.

Clinical Pearls

- Pericardial hydatid cysts are however rare entities even in the endemic areas.
- The diagnosis is based on positive serologic testing and imaging studies. Chest radiography, ultrasonography, CT, and MR imaging are all useful in the diagnosis of hydatid disease, even in emergency conditions.
- Surgical excision and medical management with albendazole represent the treatment of choice for multiple pericardial hydatid cysts.
- In a patient presenting with anaphylactic signs, without any obvious historical required considerations of “special circumstances”.
- Pericardial hydatid cyst presenting as anaphylactic shock is uncommon.
- Anaphylactic shock due to broken intra-pericardial hydatid cyst, is a real medical and surgical emergency.

Acknowledgments

The authors would like to acknowledge the contribution of Doina Butcovan, MD, PhD, Dan Iliescu, MD, PhD, Anda Paulet, MD and Alina Tiron, MD.

