

# The effects of probiotics during refeeding period on jejunum mucosal morphology after short-term starvation in Wistar rats

*Alifi Maulidyan, Dikki Drajat Kusmayadi, Bethy S. Hernowo, Tri Wahyu Murni*

## Abstract

**Aim:** A period of enteral feeding absence is known to cause intestinal atrophy, damaging mucosal barrier and decrease of enterocyte absorption capacity. However, sometimes nothing per oral is inevitable as a part of medical management. During refeeding, damaged intestinal cells are restored. Probiotics are living microorganism, which yields trophic effect on gut. The aim of this research was to investigate the effects of probiotics, which were given during refeeding period on gut morphology after short-term starvation in rats model.

**Methods:** Twenty-four Wistar rats were assigned into 4 groups, and each group consists of 6 rats. Group I: rats starved for 3 days, then refed with probiotics for 3 days (probiotics group), group II: rats starved for 3 days then refed for 3 days (refed group), group III: rats starved for 3 days (starved group), group IV: rats with normal diet for 3 days (control group). Probiotics dispensed on this research were a combination of *Lactobacillus rhamnosus* and *Lactobacillus acidophilus* (Lacidofil®). Jejunum was harvested at day 7 for group I and II, and at day 4 for group III and IV, then was stained with

hematoxylin & eosin. A pathologist analyzed number of villi, mucosal thickness, villi height and crypt depth within each specimen. We analyzed the result with Anova or Kruskal Wallis and post-hoc analysis. The study was conducted in Pathology Anatomy Laboratory in Hasan Sadikin Hospital, Bandung, Indonesia.

**Results:** Starved groups revealed significantly less number of villi, thinner mucosa, shorter villi, shallower crypt depth and more pronounced mucosal damage compared to control group. Refed group had improved all parameters studied compared to starved group, but still had statistical differences compared to control group. In the probiotics group, there were no significant differences in all parameters measured compared to normal group except for crypt depth.

**Conclusion:** This research revealed that probiotics given during refeeding period in starved rats exerts positive effect on number of villi, mucosal thickness, villi height, and mucosal damage score, but there was no significant effect concerning to crypt depth.

**Key words:** Probiotics, starvation, refeeding, intestinal mucosa, morphology.

---

From Department of Pediatric Surgery, Hasan Sadikin General Hospital/Padjadjaran University, Bandung, Indonesia (Alifi Maulidyan and Dikki Drajat Kusmayadi), Department of Pathology Anatomy, Hasan Sadikin General Hospital/Padjadjaran University, Bandung, Indonesia (Bethy S. Hernowo), and Department of Cardiothoracic Surgery, Hasan Sadikin General Hospital/Padjadjaran University, Bandung, Indonesia (Tri Wahyu Murni).

## Address for correspondence:

Alifi Maulidyan, MD

Department of Pediatric Surgery, Hasan Sadikin General Hospital/Padjadjaran University

Jl. Pasteur no. 38, Bandung 40161, Indonesia

Email: alifi.poerboyo@gmail.com

## Introduction

A period of enteral nutrients absence is known to alter gut mucosal morphology and function. Long term starvation will lead to intestinal atrophy, decrease in intestinal absorptive capacity, damage of gut barrier and increase in mucosal permeability, which has profound effect on mucosal integrity. (1-3) In critically ill patients, it is known that gut atrophy occurs after 5-8 days of fasting. (4) Meanwhile, in rat model, gut atrophy occurs only after 2-3 days of starvation, hence makes rats commonly used as a gut atrophy model. (5) Probiotics are living organisms that exert health benefit to the host if ingested. (6,7) Several studies reveal that probiotics promote epithelial mucosal restoration and increasing the gut barrier function. (7,8) This study aimed to investigate the effect of probiotics, which were given during refeeding period on gut morphology after short term starvation.

## Material and Methods

Twenty-four male Wistar rats, weighing 220-270 grams were used. The rats were divided into 4 groups of 6 animals each. Animal ethical clearance was obtained from Hasan Sadikin Hospital Ethical and Research Committee (no. LB.04.01./A05/EC/024/III/2012). After acclimatization period, animals were divided into 4 groups (**Table 1**).

Diet given was standard rat chow. Probiotics used in this study were mixture of *Lactobacillus acidophilus* and *Lactobacillus rhamnosus* (*Lacidophil*<sup>®</sup>), with  $2 \times 10^9$  CFU dosage. The probiotics were prepared by dissolving the products in 3 ml water and administered intragastrically. In group I and II, the jejunum specimens were harvested at day 7, meanwhile in group III and IV the jejunum specimens were obtained at day 4. Rats received anesthesia by intramuscular ketamine injection and were subjected to midline laparotomy. The jejunum specimens were identified and removed with gentle manipulation. The specimens were opened, rinsed with normal saline, fixed in neutral buffered formalin, embedded in paraffin, sectioned at 5  $\mu$ m and stained with hematoxylin & eosin for light microscopic examination. The examination of morphological studies performed in 10 random areas with well-preserved villi in each specimen. Analysis of the specimens consists of number of villi/millimeter, mucosal thickness, villi height,

and crypt depth (**Figure 1**). Mucosal thickness measured from the tip of the villi to the muscularis mucosa. Villi height measured from the tip of the villi to the junction of villi and crypt. Crypt depth measured from the junction of villi and crypt to the bottom of the crypt. Histology examination was performed by a histologist.

All data from the parameters studied were expressed as mean value  $\pm$  standard deviation. Anova test or Kruskal Wallis test with post-hoc analysis was performed for statistical analysis when applicable, with p value  $<0.05$  was considered significant.

## Results

Analysis of morphometric results revealed that starved rats (group III) had significantly fewer number of villi, thinner mucosa, shorter villi and shallower crypt depth compared to normal group (group IV), with p value  $<0.05$  (**Table 2**). Refed group revealed improvements within each parameter studied compared to the starved group. However, refed group (group II) still revealed significantly fewer number of villi, thinner mucosa, shorter villi and shallower crypt depth compared to normal group (group IV). In probiotics group (group I), there were no significant differences concerning number of villi, mucosal thickness and length of villi compared to control group, except the crypt depth ( $166.67 \pm 51.64 \mu\text{m}$  vs  $283.33 \pm 75.28 \mu\text{m}$ ) (**Figure 2-5**).

## Discussion

Gut is an important organ not only functioning in digestive system but also serves as the largest immunology organ. (3,4) It is widely known that starvation, especially in long term period could lead into intestinal atrophy. (4,9,10) In critically ill patients intestinal atrophy could occur even only in 5 days of total parenteral nutrition. (11)

Mucosal growth is a dynamic and balanced process of cell shedding and replacement. Sessile enterocyte is located at the tip of villi and continually renewed by younger cells from intestinal crypt. (12-14) Intestinal mucosal regulation depends on gut hormones, growth factors, luminal nutrition and luminal microbes. The presence of enteral nutrition is known to promote epithelial cell proliferation because it

induces ornithine decarboxylase, which would enhance intracellular polyamine, which is essential for DNA synthesis. Enteral nutrition also has direct effect of workload absorption and indirect effect due to gut trophic hormones such as gastrin and cholecystokinin, which are released during feeding. (13,15-17)

Absence of enteral nutrition was known to shorten the villi, impair immunoglobulin transport to epithelial surface, decrease of mucin, and impairment of tight junction, which might lead to bacterial translocation. (1,2,18-21) During starvation period, energy is chiefly used to maintain cell metabolism, and damaged cells would not be balanced with regeneration, therefore intestinal atrophy features would be visible. (22) During starvation, enzyme which neutralize reactive oxygen species would be diminished, therefore the enterocyte would be more prone to inflammation and further damage. (23) In healthy human, starvation for two weeks is known to cause intestinal atrophy, meanwhile in critically ill patients atrophy occurs even after 5-8 days starvation. (11,24) Refeeding is known to restore the mucosal atrophy, meanwhile the time needed exactly for mucosal recovery is still uncertain. (9,10) In rats, it is known that 3 days refeeding would improve mucosal morphology to a certain extent. (8)

Intestinal microbes also have an important role on intestinal cell growth regulation. Luminal microbes ferment polysaccharide, oligosaccharides, protein, peptide and glycoprotein into short chain fatty acids (SCFA) such as acetate, propionate, butyrate and several other products such as lactate, ethanol and succinate through glycolytic and phosphate pentose pathway. (13) Butyrate is the most potent SCFA promoting cell proliferation which reveals an inhibition activity for histone deacetylase enzyme, hence histone hyperacetylation occurs which make the DNA is

more accessible for various replication enzyme. (25-27)

Probiotics are microorganism, which have benefit effect for the host if consumed. This study uses mixture *L. acidophilus* and *L. rhamnosus*, which widely dispensed for medical purposes. (6) Probiotics are known to improve cell survival by increasing anti apoptotic protein Akt/protein kinase B and inhibition of pro apoptotic protein p38 MAP kinase. Probiotics also produce SCFA such as acetate, propionate and butyrate, which are major fuel of intestinal cells and promoting mucosal cell proliferation. (28-34)

In the present study, starved groups obviously reveal decreased value of all parameters resembling mucosal atrophy. Refed animals had less profound mucosal damage if compared to starved animals, and it was concordance with this study. In the other hand, refed group parameters were significantly lower in relation to control group. Meanwhile, probiotics group was not significantly different in relation group in respect to number of villi, mucosal thickness and villi height. The results of this research was in concordance with other research that probiotics might positively impact mucosal cell proliferation. (8,35-37) Meanwhile, a research by Ichikawa also revealed an increasing of crypt cell production rate by 25% in jejunum. (38) The only parameter in the probiotics group which was statistically different from control group was crypt depth. However, crypt regeneration in rats takes 12 weeks and perhaps during this study the effect of probiotics on crypt depth was not visible if only given in 3 days after starvation. (12,39)

This research reveals that probiotics given during refeeding period enhance restoration of jejunal mucosa atrophy. These findings might be helpful for further research of management starved patients.

**Table 1.** Animal groups

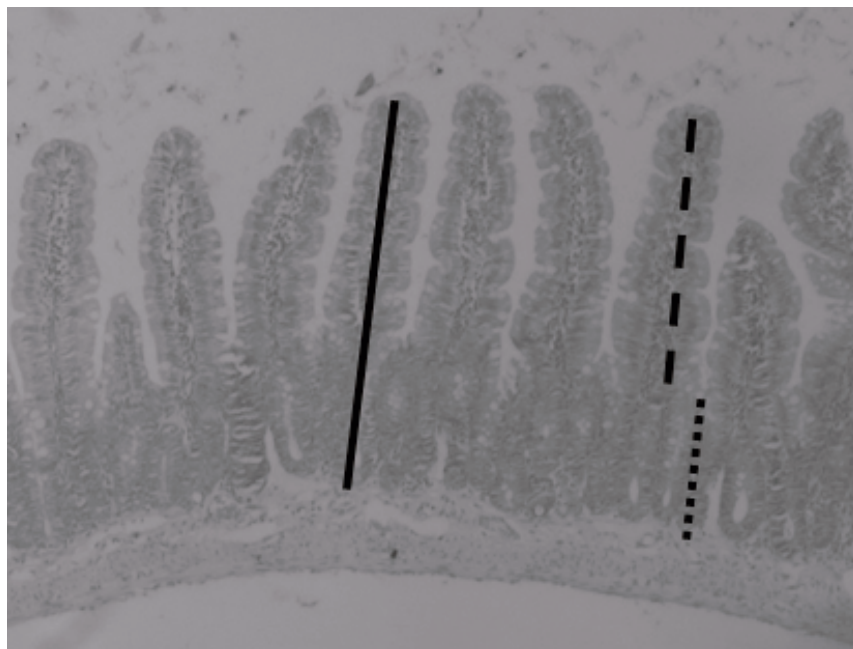
Group	Intake for day 1-3	Intake for day 4-6
I (probiotics group)	Water only	Rat chow ad libitum+probiotics
II (refed group)	Water only	Rat chow ad libitum
III (starved group)	Water only	None (sacrificed at the day 4)
IV (control group)	Rat chow	None (sacrificed at the day 4)

**Table 2.** Results of mucosa morphometry analysis

Group	Number of villi/millimeter	Mucosal thickness (μm)	Villi height (μm)	Crypt depth (μm)
I	10.33±0.82 <sup>ad</sup>	616.67±116.91 <sup>ad</sup>	450.00±122.48 <sup>ad</sup>	166.67±51.64 <sup>df</sup>
II	8.33±1.03 <sup>ac</sup>	466.67±81.65 <sup>ace</sup>	300.00±83.67 <sup>ace</sup>	175.00±41.83 <sup>ce</sup>
III	7.83±0.98 <sup>bcd</sup>	333.33±40.83 <sup>bcd</sup>	216.67±25.82 <sup>bcd</sup>	116.67±25.82 <sup>bcd</sup>
IV	10.67±1.03 <sup>bc</sup>	741.67±14.89 <sup>bc</sup>	458.33±91.74 <sup>bc</sup>	283.33±75.28 <sup>bef</sup>

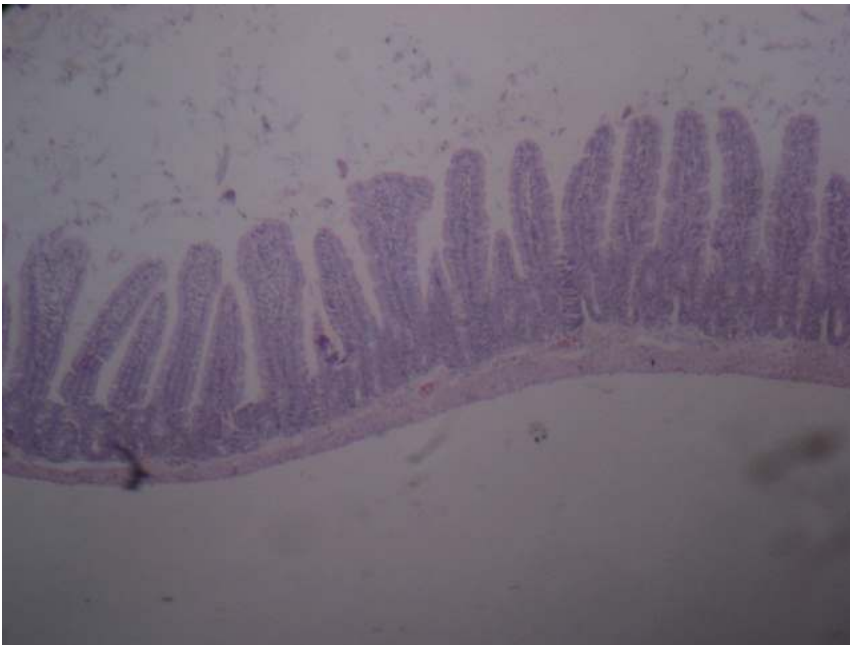Legend: <sup>a</sup>p<0.05 between probiotics and refed groups in respect to number of villi, mucosal thickness and villi height; <sup>b</sup>p<0.05 between control and starved rats within each parameter studied; <sup>c</sup>p<0.05 between refed and starved groups in respect to mucosal thickness, villi height and crypt depth; <sup>d</sup>p<0.05 between probiotics and starved groups within each parameter studied; <sup>e</sup>p<0.05 between refed and control groups within each parameter studied; <sup>f</sup>p<0.05 between probiotics and control group in respect to crypt depth

**Figure 1.** Measurement of the specimen



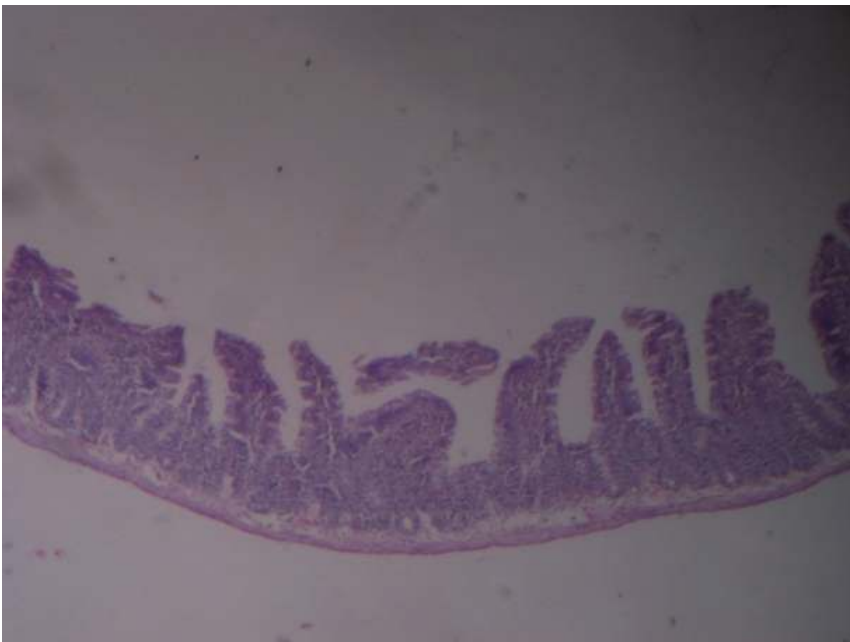Legend: Line=mucosal thickness; dash=villus height; dot=crypt depth.

**Figure 2.** The specimen of group I (probiotics group)



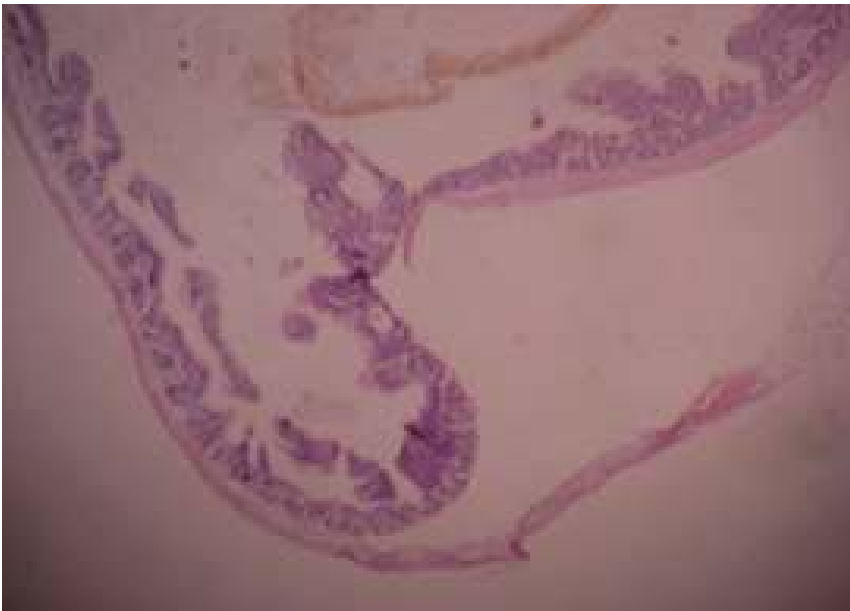
Legend: The number of villi, mucosal thickness and crypt resemble normal jejunum.

**Figure 3.** The specimen of group II (refed group)



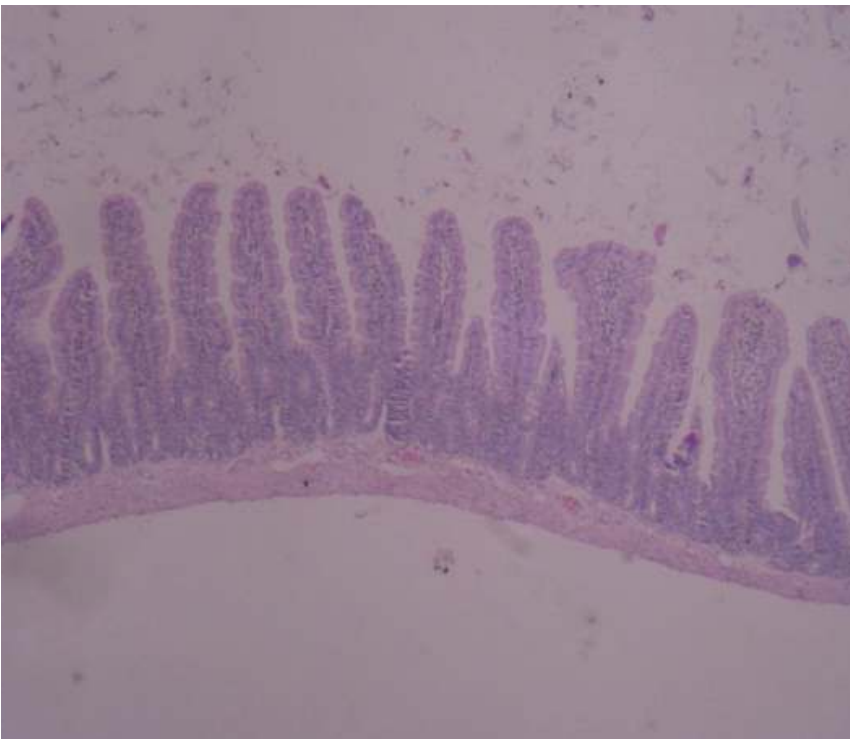
Legend: The amount of villi were reduced, the villi were flattened and mucosa was thinner compared to control group.

**Figure 4.** The specimen of group III (starved group)



Legend: The number of villi were severely reduced and flattened, and mucosa was thinner compared to probiotics, refed and control groups.

**Figure 5.** Specimen of group IV (control group)



Legend: Villi, crypt and mucosal thickness were normal.

## References

1. Strodbeck F. The pathophysiology of prolonged periods of no enteral nutrition or nothing by mouth. *Newborn Inf Nurs Rev* 2003;3:47-54.
2. Sun X, Spencer AU, Yang H, Haxhija EQ, Teitelbaum DH. Impact of caloric intake on parenteral nutrition-associated intestinal morphology and mucosal barrier function. *JPEN J Parenter Enteral Nutr* 2006;30:474-9.
3. Marino PL. *Alimentary prophylaxis in the ICU*. 3rd ed. Philadelphia (PA): Lippincott; 2007. p. 67-94.
4. Hernandez G, Velasco N, Wainstein C, Castillo L, Buggedo G, Maiz A, et al. Gut mucosal atrophy after a short enteral fasting period in critically ill patients. *J Crit Care* 1999;14:73-7.
5. Archer SY, Hodin RA (2001) Intestinal regeneration and adaptation models. In: Souba WW, Wilmore DW. *Surgical research*. New York: Academic Press; 2001. p. 562-5.
6. World Health Organization. *Probiotics in food. Health and nutritional properties and guidelines for evaluation*. Rome: World Health Organization; 2006.
7. Floramonti J, Theodorou V, Bueno L. Probiotics: what are they? What are their effects on gut physiology? *Best Pract Res Clin Gastroenterol* 2003;17:711-24.
8. Papavramidis TS, Kaidoglou K, Grosomanidis V, Kazamias P, Anagnostopoulos TH, Paramythiotis D, et al. Short-term fasting-induced jejunal mucosal atrophy in rats: the role of probiotics during refeeding. *Ann Gastroenterol* 2009;22:268-74.
9. Duran B. The effects of long-term total parenteral nutrition on gut mucosal immunity in children with short bowel syndrome: a systematic review. *BMC Nurs* 2005;4:1-22.
10. Buchman AL, Moukarzel AA, Bhuta S, Belle M, Ament ME, Eckhart CD, et al. Parenteral nutrition is associated with intestinal morphologic and functional changes in humans. *JPEN J Parenter Enteral Nutr* 1995;19:453-60.
11. Chappell VL, Thompson MD, Jeschke MG, Chung DH, Thompson JC, Wolf SE. Effects of incremental starvation on gut mucosa. *Dig Dis Sci* 2003;48:765-9.
12. Winton DJ, Ponder BA. Stem-cell organization in mouse small intestine. *Proc Biol Sci* 1990;241:13-8.
13. Jaladanki RN, Wang JY. Regulation of gastrointestinal mucosal growth. San Rafael (CA): Morgan & Claypool Life Sciences; 2010.
14. Crosnier C, Stamataki D, Lewis J. Organizing cell renewal in the intestine: stem cells, signals and combinatorial control. *Nat Rev Genet* 2006;7:349-59.
15. Kotunia A, Zabielski R. Ghrelin in the postnatal development of the gastrointestinal tract. *J Physiol Pharmacol* 2006;57:97-111.
16. Ohland CL, Macnaughton WK. Probiotic bacteria and intestinal epithelial barrier function. *Am J Physiol Gastrointest Liver Physiol* 2010;298:G807-19.
17. Jenkins AP, Thompson RP. Enteral nutrition and the small intestine. *Gut* 1994;35:1765-9.
18. Johnson LR. Regulation of gastrointestinal mucosal growth. *Physiol Rev* 1988;68:456-502.
19. Clarke RM. The time-course of changes in mucosal architecture and epithelial cell production and cell shedding in the small intestine of the rat fed after fasting. *J Anat* 1975;120:321-7.
20. Smirnov A, Sklan D, Uni Z. Mucin dynamics in the chick small intestine are altered by starvation. *J Nutr* 2004;134:736-42.
21. Kang W, Gomez FE, Lan J, Sano Y, Ueno C, Kudsk KA. Parenteral nutrition impairs gut-associated lymphoid tissue and mucosal immunity by reducing lymphotoxin beta receptor expression. *Ann Surg* 2006;244:392-9.
22. Mescher AL. *Junqueira's basic histology: text and atlas*. 12th ed. New York: Lange; 2010. p. 266-80.
23. Swiderska-Kolacz G, Klusek J, Kolataj A, Faray J. Effect of starvation and immobilization on glutathione level and activity of glutathione enzymes in the liver and kidney of rabbits. *Slov J Anim Sci* 2006;39:151-4.
24. Pironi L, Paganelli GM, Miglioli M, Biasco G, Santucci R, Ruggeri E, et al. Morphologic and cytoproliferative patterns of duodenal mucosa in two patients after long-term total parenteral nutrition: changes with oral refeeding and relation to intestinal resection. *JPEN J Parenter Enteral Nutr* 1994;18:351-4.
25. Hijova E, Chmelarova A. Short chain fatty acids and colonic health. *Bratisl Lek Listy* 2007;108:354-8.
26. Scheppach W. Effects of short chain fatty acids on gut morphology and function. *Gut* 1994;35:S35-8.
27. Blottiere HM, Buecher B, Galmiche JP, Cherbut C. Molecular analysis of the effect of short-chain fatty acids on intestinal cell proliferation. *Proc Nutr Soc* 2003;62:101-6.
28. Gill HS, Guarner F. Probiotics and human health: a clinical perspective. *Postgrad Med J* 2004;80:516-26.
29. Matur E, Eraslan E. The impacts of probiotics on gastrointestinal physiology. In: *New advances in the basic and clinical gastroenterology*. [Online]. 2012. Available from: URL:<http://www.intechopen.com/books/new-advances-in-the-basic-and-clinical-gastroenterology/the-impact-of-probiotics-on-the-gastrointestinal-physiology>
30. Michail S. Irritable Bowel Syndrome. In: Michail S, Sherman PM, editors. *Probiotics in Pediatric Medicine (Nutrition and Health)*. Totowa (NJ): Humana Press; 2009. p. 131-41.
31. Saavedra JM. Use of probiotics in pediatrics: rationale, mechanisms of action, and practical aspects. *Nutr Clin Pract* 2007;22:251-65.
32. Mechanisms of probiotics. In: Lee YK, Salminen S, editors. *Handbook of probiotics and prebiotics*. 2nd ed. Hoboken (NJ): John Wiley & Sons; 2009. p. 377-440.
33. Yan F, Polk DB. Probiotic bacterium prevents cytokine-induced apoptosis in intestinal epithelial cells. *J Biol Chem* 2005;277:50959-65.
34. Ng SC, Hart AL, Kamm MA, Stagg AJ, Knight SC. Mechanisms of action of probiotics: recent advances. *Inflamm Bowel Dis* 2009;15:300-10.
35. Peric L, Milosevic N, Zikic D, Bjedov S, Cvetkovic D, Markov S, et al. Effects of probiotics and phyto-genic products on performance, gut morphology and cecal microflora of boiler chickens. *Arhiv Tierzucht* 2010;3:350-9.
36. Zang AW, Lee BD, Lee SK, Lee KW, An GH, Song KB, et al. Effects of yeast (*Saccharomyces cerevisiae*) cell components on growth performance, meat quality and ileal mucosa development of broiler chicks. *Poult Sci* 2005;84:1015-21.
37. Pelicano ERL, Souza PA, Souza HBA, Figueiredo DF, Boiago MM, Carvalho SR, et al. Intestinal mucosa development in boiler chickens fed natural growth promoters. *Bra J Poult Sci* 2005;7:221-9.
38. Ichikawa H, Kuroiwa T, Inagaki A, Shineha R, Nishihira T, Satomi S, et al. Probiotic bacteria stimulate gut epithelial cell proliferation in rat. *Dig Dis Sci* 1999;44:2119-23.
39. Stappenbeck TS, Wong MH, Saam JR, Mysorekar IU, Gordon JI. Notes from some crypt watchers: regulation of renewal in the mouse intestinal epithelium. *Curr Opin Cell Biol* 1998;10:702-9.