

Case report and review – Nasogastric tube complications

Nicholas L. Smith, Michael Park, Ross Freebairn

Abstract

The placement of nasogastric (NG) tubes is an extremely common intervention in general surgical wards and intensive care units. We report a case series of two patients who developed life threatening complications from the insertion of nasogastric tubes. Case 1 was a 71 year old man admitted to the Intensive Care Unit with pancreatitis who had three isolated complications from NG tube insertion. Firstly he developed a severe aspiration pneumonitis requiring intubation and ventilation; secondly on reinserting a NG tube he developed a narrow complex tachycardia with cardiovascular compromise requiring electrical cardioversion; and thirdly he developed a large pneumothorax following inadvertent insertion of a fine bore feeding tube into his left pleural space. Case 2 was an 83 year old woman with a large

sacral pressure sore who was admitted to a surgical ward for enteral feeding. She also developed a pneumothorax following pleural insertion of a fine bore feeding tube.

This case series serves as a reminder to the rare but potentially serious complications associated with NG tube insertion. Following our experience and of review of the literature we want to stress the importance of avoiding NG tubes in facial trauma; correctly positioning the patient prior to insertion; being aware of the limitation of bedside tests in establishing the position of the NG tube; using x-ray to confirm tube placement and monitoring patients closely following the removal of a misplaced tube.

Key words: Nasogastric tube, adverse effects, pneumothorax, cardiac arrhythmia, aspiration pneumonitis.

Introduction

The placement of nasogastric (NG) tubes is an extremely common intervention in general surgical wards and intensive care units. They are frequently inserted by nursing staff and, although the insertion may be uncomfortable for the patient, it is considered a relatively benign procedure. We present a case series of two patients who developed potentially life threatening complications associated with nasogastric or nasojejunal tube insertion and review the published literature

on complications from the insertion of nasogastric tubes.

Case 1

A 71-year-old man was admitted to Hawke's Bay Hospital with acute pancreatitis that was confirmed on CT scan. His past medical history was extensive and includes an episode of pancreatitis, familial hypocalcaemic hypercalcaemia, open cholecystectomy, ischaemic heart disease with a previous coronary artery bypass graft, previous transient ischaemic attacks and subsequent carotid endarterectomy, abdominal aortic aneurysm repair, peripheral vascular disease with a femoral-popliteal bypass, impaired glucose tolerance and chronic obstructive airways disease. Despite this background he lived with his wife in their own home and

From Hawke's Bay Hospital, Hastings, New Zealand (Nicholas L. Smith, Michael Park, and Ross Freebairn)

Address for correspondence:

Dr. Ross Freebairn

Hawke's Bay Hospital, Private Bag 9014, Hastings 4156, New Zealand

Email: ross.freebairn@xtra.co.nz

was completely independent with activities of daily living. He could walk up to one hour with a stick. He was an ex-smoker (20 pack-year history). He had not drunk alcohol for 10 years but claims to have had a heavy intake during the 40 years prior (exact quantity unknown).

He was admitted to the intensive care unit (ICU) on day 2 of his admission with an APACHE II score of 16. On day 4 he underwent an attempted insertion of a nasojejun tube under radiological guidance (Flocare 10 Fr Bengmark Naso-intestinal tube, Chatel-St-Denis, France). Unfortunately, because of patient intolerance and vomiting this was unsuccessful. He returned to ICU agitated and developed progressive shortness of breath that was consistent with pulmonary aspiration. He had a sudden decline in respiratory function that required intubation and ventilation.

On day 9 in ICU he developed problems absorbing the enteral feeds that were being delivered via an NG tube despite the addition of prokinetic agents (metoclopramide and erythromycin). An attempt to replace the NG tube was carried out while he was still intubated. During this procedure he developed a narrow complex tachycardia with a ventricular rate of 200/min and subsequently his blood pressure dropped to 60/30 mmHg. The procedure was abandoned and he received a synchronised electrical cardioversion of 100 Joules (biphasic) which returned him to sinus rhythm.

He was extubated after 14 days and his clinical condition improved to a point where he was able to return to the surgical ward. He was deemed unsafe to commence oral feeding because of a poor swallow (possibly related to critical illness). After his NG tube became blocked on day 29 of his admission, a fine bore feeding tube with an inner guide wire was inserted (Flocare PUR 10Fr tube, Nutricia, Schiphol). The post-insertion chest x-ray showed the tube had entered the left main bronchus (**Figure 1**). The feeding tube was subsequently removed. He then became dyspnoeic and tachypnoeic with a respiratory rate of 34 per min. A repeat chest x-ray showed a large left sided pneumothorax (**Figure 2**). A 20 FG intercostal chest drain was placed under direct vision.

He made an uneventful recovery following the pneumothorax. On day 48 of his admission he had a percutaneous endoscopic gastrostomy (PEG) inserted for feeds. He later recovered a

functional swallow during the several weeks he spent in the rehabilitation ward and prior to being discharged to his own home the PEG was removed.

Case 2

An 83-year-old woman was admitted to a surgical ward for treatment of her large sacral pressure area. She had cognitive impairment that was related to a previous stroke, underlying dementia and probable neuro-syphilis. She had been bed-bound for over a year and had developed a large problematic sacral pressure sore. Her past medical history also included congestive heart failure, atrial fibrillation, and shingles.

A fine bore nasogastric tube with a metal stylet (Flocare PUR 10Fr tube, Nutricia, Schiphol) was inserted for the purpose of supplementary feeds. The tube was noted to be in the R pleural space on the post-procedure chest x-ray and a small pneumothorax was also noted (**Figure 3**). This increased following removal of the misplaced tube and she developed respiratory distress. She required the insertion of a 20Fr intercostal chest drain with an underwater seal for treatment of the pneumothorax.

Discussion

Complications from NG tube insertion have been described in the literature for over 35 years. The rate of complication has been reported to occur from 0.3-15%. (1) Complications can occur during the insertion process and range from minor events (epistaxis) to the rarer but potentially life-threatening complications including tracheobronchopleural complications, intravascular penetration, gastrointestinal complications and intracranial insertion. (2,3) Complications can also be a consequence of long term use including ulceration or bleeding from the nose, nasopharynx, or gastrointestinal tract. (2)

Insertion of a NG tube into the pulmonary tree is a well described complication. (1-13) The main risk of this malpositioned tube is if enteral feeds and medications are subsequently delivered into the lungs. It is therefore essential to confirm the correct position of the tube prior to starting feeding. Common methods used to establish the correct position include: noting a smooth entry; no cough or

respiratory distress on insertion; aspiration of gastric content with or without litmus testing and positive auscultation of injected air over the epigastrium. Unfortunately all of these are unreliable and Rassius et al (8) demonstrated that malpositioned tubes are not predictable from bedside tests. The lack of distress on insertion is especially unhelpful as often the patients who are requiring a NG tube for a poor swallow have decreased pharyngeal sensation and may not show any indication of the tube being inserted incorrectly. The gold standard test to confirm the position is a chest x-ray looking for the tube below the diaphragm. However, even this is not infallible as the end of some tubes may be difficult to identify on x-ray and a tube in the left pleural cavity could appear to be in the stomach.

Fine bore feeding tubes are often used for longer term placement in an attempt to reduce the mechanical problems of larger diameter NG tubes. A metal stylet is often required to increase rigidity for easier placement. However, this increased rigidity may augment the risk of penetrating a bronchus or piercing the pleura. A pneumothorax and subsequent respiratory distress may not occur until the tube has been removed. Patients found to have a NG tube inserted into the lungs should be monitored closely and have progress x-rays following removal of the tube. (12)

Appropriate positioning of the patient can help achieve correct insertion, either fully sitting up if conscious or supine with the neck gently flexed if unconscious. (1) The insertion of a NG tube can also be performed under direct visualisation in the unconscious patient with the aid of a laryngoscope and Magill forceps. Importantly, the presence of an inflated endotracheal or tracheostomy tube cuff does not prevent insertion into the trachea. (2)

Intravascular complications are extremely rare but reports of erosion into major vessels exist. (14,15) D uthorn et al (16) describe direct intravascular insertion. The instant aspiration of blood from the nasogastric tube was initially thought to be from a large gastrointestinal bleed, however the NG tube had penetrated the right internal jugular vein at the height of the soft palate.

Intracranial insertion of a NG tube was first reported in 1975 by Seebacher. (17) There have been several other reports of this occurring since. (18-26) It is now widely recognised that NG tube insertion should not be performed acutely in patients with facial trauma or those who have undergone midfacial surgery due to the risk of the tube passing through the cribriform plate into the cranium.

Oesophageal obstruction has been reported from a coiled NG tube. (27) Perforation and dissection of the oesophagus by NG tubes have also been reported. (28-29)

Cardiac arrhythmias with NG tube insertion are rare. Aroni et al (30) report a case of one patient who, during NG tube insertion under general anaesthesia, developed asystole requiring chest compressions, adrenaline and atropine. The same patient went into ventricular tachycardia during NG tube insertion during his rescheduled operation.

In summary, we hope these cases serve as a reminder to the rare but potentially serious complications associated with NG tube insertion. We stress the importance of avoiding NG tubes in facial trauma, correctly positioning the patient prior to insertion, using x-ray to confirm tube placement and monitoring patients closely following the removal of a misplaced tube.

Figure 1. CXR of Case 1 with nasogastric tube in left pleural space

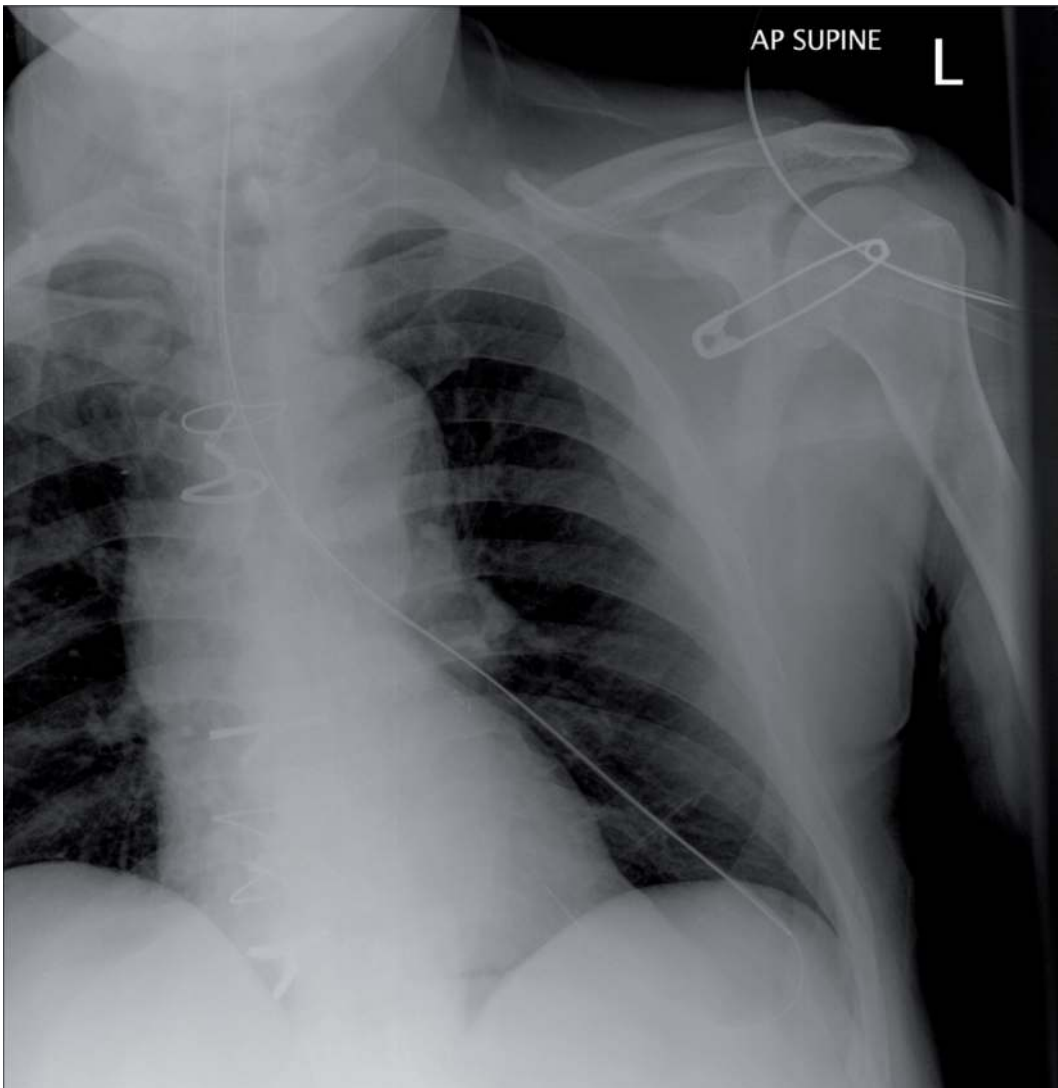


Figure 2. CXR of Case 1 with large left sided pneumothorax following removal of intrapleural nasogastric tube

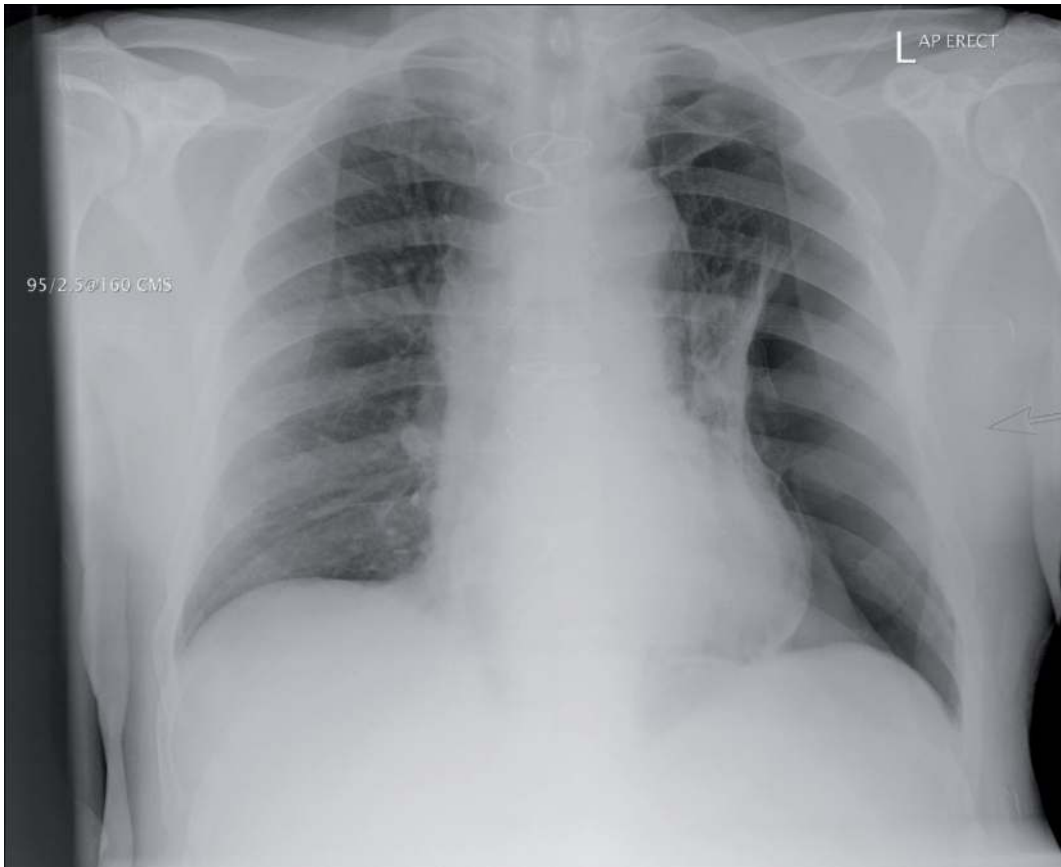
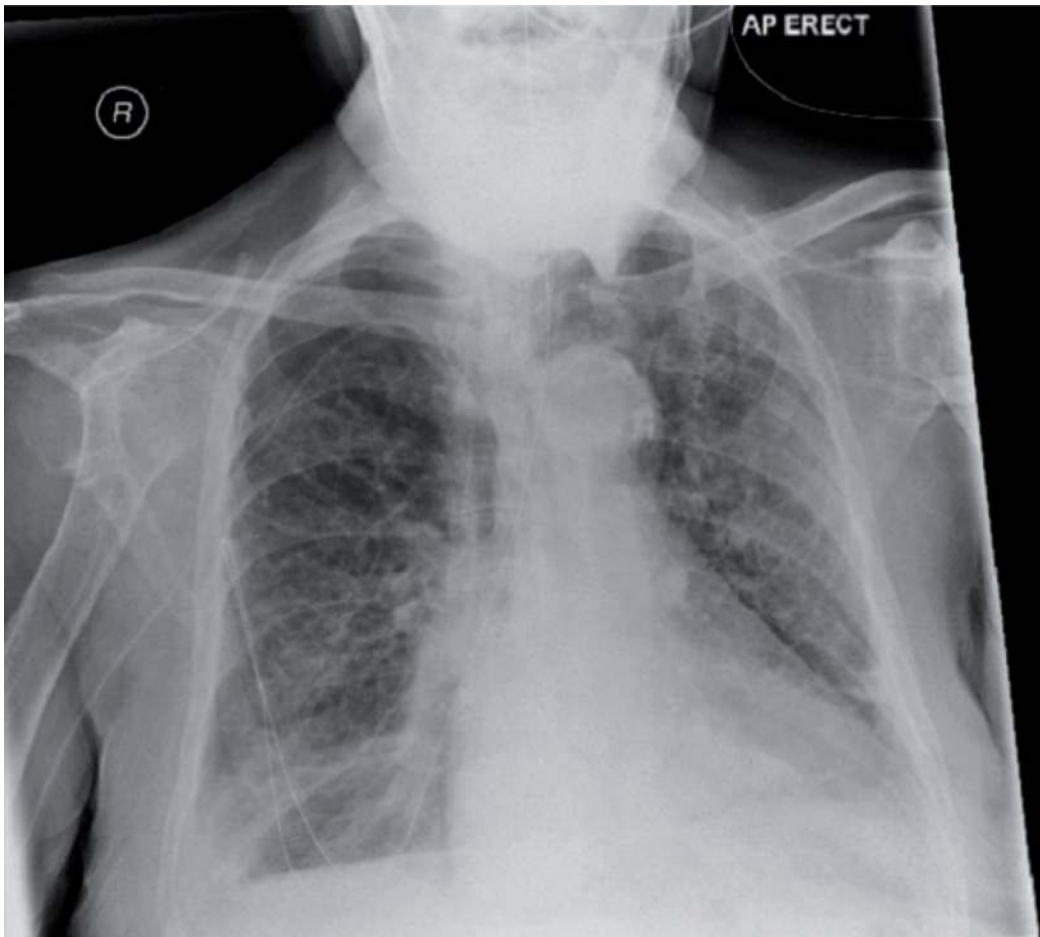


Figure 3. CXR from Case 2 with nasogastric tube in R pleural space



References

1. Weinberg L, Skewes D. Pneumothorax from intrapleural placement of a nasogastric tube. *Anaesth Intensive Care* 2006;34:276-9.
2. Wang PC, Tseng GY, Yang HB, Chou KC, Chen CH. Inadvertent tracheobronchial placement of feeding tube in a mechanically ventilated patient. *J Chin Med Assoc* 2008;71:365-7.
3. Yardley IE, Donaldson LJ. Patient safety matters: reducing the risks of nasogastric tubes. *Clin Med* 2010;10:228-30.
4. Harris MR, Huseby JS. Pulmonary complications from nasoenteral feeding tube insertion in an intensive care unit: incidence and prevention. *Crit Care Med* 1989;17:917-9.
5. Valentine RJ, Turner WW Jr. Pleural complications of nasoenteric feeding tubes. *JPEN J Parenter Enteral Nutr* 1985;9:605-7.
6. Bankier AA, Wiesmayr MN, Henk C, Turetschek K, Winkelbauer F, Mallek R, et al. Radiographic detection of intrabronchial malpositions of nasogastric tubes and subsequent complications in intensive care unit patients. *Intensive Care Med* 1997;23:406-10.
7. Thomas B, Cummin D, Falcone RE. Accidental Pneumothorax from a Nasogastric Tube. *N Engl J Med* 1996;335:1325.
8. Rassias AJ, Ball PA, Corwin HL. A prospective study of tracheopulmonary complications associated with the placement of narrow-bore enteral feeding tubes. *Crit Care* 1998;2:25-8.
9. Nakao MA, Killam D, Wilson R. Pneumothorax secondary to inadvertent nasotracheal placement of a nasoenteric tube past a cuffed endotracheal tube. *Crit Care Med* 1983;11:210-1.
10. Kannan S, Morrow B, Furness G. Tension pneumothorax and pneumomediastinum after nasogastric tube insertion. *Anaesthesia* 1999;54:1012-3.
11. Hendry PJ, Akyurekli Y, McIntyre R, Quarrington A, Keon WJ. Bronchopleural complications of nasogastric feeding tubes. *Crit Care Med* 1986;14:892-4.
12. O'Neil R, Krishnananthan R. Intrapleural nasogastric tube insertion. *Australas Radiol* 2004;48:139-41.
13. Hensel M, Marnitz R. [Pneumothorax following nasogastric feeding tube insertion : Case report and review of the literature]. *Anaesthesist* 2010;59:229-32,4.
14. Merchant FJ, Nichols RL, Bombeck CT. Unusual complication of nasogastric esophageal intubation-erosion into an aberrant right subclavian artery. *J Cardiovasc Surg (Torino)* 1977;18:147-50.
15. Ikeda T, Yokota Y, Ando F, Okamoto F, Otani S, Nakanishi K, et al. [A case of an aberrant subclavian artery-esophageal fistula due to prolonged nasogastric intubation]. *Kyobu Geka* 1991;44:1045-7.
16. DÜthorn L, Schulte Steinberg H, Häuser H, Neeser G, Pracki P. Accidental intravascular placement of a feeding tube. *Anesthesiology* 1998;89:251-3.
17. Seebacher J, Nozik D, Mathieu A. Inadvertent intracranial introduction of a nasogastric tube, a complication of severe maxillofacial trauma. *Anesthesiology* 1975;42:100-2.
18. Fletcher SA, Henderson LT, Miner ME, Jones JM. The successful surgical removal of intracranial nasogastric tubes. *J Trauma* 1987;27:948-52.
19. Fremstad JD, Martin SH. Lethal complication from insertion of nasogastric tube after severe basilar skull fracture. *J Trauma* 1978;18:820-2.
20. Arslantas A, Durmaz R, Cosan E, Tel E. Inadvertent insertion of a nasogastric tube in a patient with head trauma. *Childs Nerv Syst* 2001;17:112-4.
21. Baskaya MK. Inadvertent intracranial placement of a nasogastric tube in patients with head injuries. *Surg Neurol* 1999;52:426-7.
22. Chandra R, Kumar P. Intracranial introduction of a nasogastric tube in a patient with severe craniofacial trauma. *Neurol India* 2010;58:804-5.
23. Ferreras J, Junquera LM, Garcia-Consuegra L. Intracranial placement of a nasogastric tube after severe craniofacial trauma. *Oral Surg Oral Med Oral Pathol Oral Radiol Endod* 2000;90:564-6.
24. Genú PR, de Oliveira DM, Vasconcellos RJ, Nogueira RV, Vasconcelos BC. Inadvertent intracranial placement of a nasogastric tube in a patient with severe craniofacial trauma: a case report. *J Oral Maxillofac Surg* 2004;62:1435-8.
25. Rahimi-Movaghar V, Borojony SB, Moghtaderi A, Keshmirian B. Intracranial placement of a nasogastric tube. A lesson to be re-learned? *Acta Neurochir (Wien)* 2005;147:573-4; discussion 574.
26. Roka YB, Shrestha M, Puri PR, Aryal S. Fatal inadvertent intracranial insertion of a nasogastric tube. *Neurol India* 2010;58:802-4.
27. Tai CM, Wang HP, Lee CT, Chang CY, Wang WL, Tseng CH, et al. Esophageal obstruction by a tangled nasogastric tube. *Gastrointest Endosc* 2010;72:1057-8.
28. McWey RE, Curry NS, Schabel SI, Reines HD. Complications of nasoenteric feeding tubes. *Am J Surg* 1988;155:253-7.
29. Hutchinson R, Ahmed AR, Menzies D. A case of intramural oesophageal dissection secondary to nasogastric tube insertion. *Ann R Coll Surg Engl* 2008;90:W4-7.
30. Aroni F, Pourzitaki C, Logotheti H, Belivanakis G, Arambatzis P. Ventricular tachycardia and cardiac arrest during nasogastric tube insertion. *South Med J* 2010;103:1192-3.