

Resuscitation incoherence after cardiac arrest due to acute intraoperative pulmonary emboli related acute right heart failure: A case report

Ade Susanti, Mayang Indah Lestari, Dita Aditianingsih

Abstract

Resuscitation incoherence is a mismatch between macrocirculation, microcirculation, and cellular parameters after resuscitation. We report a 34-year-old obese male patient, suffering from end-stage renal disease or chronic kidney disease (CKD), underwent routine hemodialysis three times a week and hypercoagulability state with rivaroxaban therapy. He had a cardiac arrest during kidney transplant surgery. Acute right heart failure causing cardiac arrest was presumably caused by acute intraoperative pulmonary embolism. Hemodynamic and resuscitation incoherence occurred and proper treatment was needed. At the time of cardiac arrest, hemodynamic coherence was lost and resuscitation was performed to restore this loss by correcting the possible causes of cardiac arrest. Although the return of spontaneous circu-

lation (ROSC) was successfully achieved, a type 1 resuscitation incoherence occurred where the macrocirculation was optimal but cellular parameters were disturbed by cell hypoxia, characterized by high levels of lactate. Type 2 resuscitation incoherence was also found in this patient until the end of treatment in the intensive care unit (ICU). Cellular parameters such as lactate levels and the venoarterial carbon dioxide tension difference to arteriovenous oxygen content difference ratio ($P[v-a]CO_2/(C[a-v]O_2)$) continued to improve during ICU treatment, but cell hypoxia might occur since the central venous pressure (CVP) value as a macrocirculation parameter was likely to increase, presumed to be caused by incomplete resolved acute pulmonary embolism related chronic thromboembolic pulmonary hypertension.

Key words: Cardiac arrest, hemodynamic coherence, pulmonary emboli, resuscitation incoherence.

From Intensive Care Fellowship Program, Universitas Indonesia-Cipto Mangunkusumo General Hospital Jakarta-Indonesia, Staff Lecturer of Universitas Jambi-Raden Mattaher General Hospital Jambi-Indonesia (Ade Susanti), Intensive Care Fellowship Program, Universitas Indonesia-Cipto Mangunkusumo General Hospital Jakarta-Indonesia, Staff Lecturer of Universitas Sriwijaya-Mohammad Hoesin General Hospital Palembang-Indonesia (Mayang Indah Lestari), Staff Lecturer, Department of Anesthesiology and Intensive Care, Cipto Mangunkusumo General Hospital, Universitas Indonesia, Jakarta-Indonesia (Dita Aditianingsih).

Address for correspondence:

Dita Aditianingsih
Department of Anesthesiology and Intensive Care, Cipto Mangunkusumo General Hospital, Universitas Indonesia, Indonesia
6th Salemba Raya, DKI Jakarta 10430, Indonesia
Tel: +6281316114154
Email: ditaaditiaa@gmail.com

Introduction

Pulmonary embolism (PE) often occurs during and after surgery. Patients undergoing surgery have risk factors for PE because of acute inflammatory reaction due to tissue trauma, activation of the clotting cascade as well as immobilization and venous stasis. Hemodynamic deterioration occurs in PE due to obstruction of the pulmonary arteries causing an acute increase in right ventricular pressure and may end in cardiac arrest. (1) The mismatch between macrocirculation, microcirculation, and cellular parameters often occur in shock patients after cardiopulmonary resuscitation. The mismatch of the three parameters in resuscitation is known as resuscitation incoherence. (2) Here, we present a unique case of resuscitation incoherence in post-cardiac arrest patient with acute right heart failure presumably caused by acute intraoperative PE.

Case presentation

A 34-year-old male with a history of end-stage renal disease or chronic kidney disease (CKD) underwent routine hemodialysis 3 times a week and hypercoagulability treated with rivaroxaban 20 mg daily. The patient was scheduled for a kidney transplant. Once, he had a history of anesthesia and treated in the ward after surgery. Based on the initial examination, the patient was assessed with obesity and hypertension, treated with irbesartan 300 mg daily. Initial echocardiography results were global normokinetic, with good left and right ventricle systolic function. Computerized tomography (CT) scan with contrast demonstrated no stenosis or thrombus in the communal and external iliac arteries. There were no calcified plaques on the walls of the communal and external iliac arteries.

The patient underwent a combination of general and epidural anesthesia. He experienced hemodynamic incoherence caused by intraoperative cardiac arrest and ventricular fibrillation when the donated kidney was implanted into the recipient's body. Cardiopulmonary resuscitation (CPR) performed according to the procedure and kidney transplantation was canceled. After performing CPR for 90 minutes, the patient had a return of spontaneous circulation (ROSC) (**Figure 1**).

Resuscitation aimed to achieve normalization of all hemodynamic parameters such as cardiac output, mean arterial pressure (MAP), central venous pressure (CVP), and central venous oxygen saturation (ScVO₂). The patient was admitted to the intensive care unit (ICU). Fluid, inotropic and vasopressor agents were used to optimize macrocirculation parameters. CVP tended to increase throughout the day, but ScVO₂, MAP, and central venous-arterial oxygen difference $P(v-a)CO_2$ were quite stable to fulfill cellular metabolic demand (**Figure 2**).

Serial lactate measurements and central venous-to-arterial CO₂ difference/arterial-central venous O₂ difference ratio ($P[v-a]CO_2/C[a-v]O_2$) were used to identify cellular parameters. Macrocirculation parameters were optimized after being given inotropic and vasoactive agents, but cellular parameters such as lactate level were still high on the first day (7.2 mmol/l). This indicated the presence of resuscitation incoherence. Over the treatment day, there was an optimal improvement in the cellular parameters (**Figure 3**).

Discussion

Intraoperative cardiorespiratory arrest is a rare condition with high mortality rate. One of the main etiologies for intraoperative cardiorespiratory ar-

rest is PE. (3) PE risk factors in this patient were hypercoagulability, obesity, stage V CKD on hemodialysis and, high-risk major surgery. Hypercoagulability was aggravated due to discontinuation of anticoagulant drugs for 7 days before surgery. Low molecular weight heparin (LMWH) or low-dose unfractionated heparin (LDUH) as PE prophylaxis was not given to this patient. (1) When PE occurred, respiratory dysfunctions were not detected because the patient was under general anesthesia. Circulation dysfunctions were detected when cardiac arrest occurred. Intraoperative cardiorespiratory arrest presumed to be caused by increased pulmonary vascular resistance by PE and increased right ventricle afterload acutely. The right ventricle is more sensitive to pressure than volume, so an increase in pressure will decrease right ventricle stroke volume. Complete pathophysiology can be seen in **Figure 4**.

Successful resuscitation must achieve a harmonious relationship between macrocirculation and microcirculation as a hemodynamic coherence. (4) Loss of hemodynamic coherence can reduce oxygen extraction capacity in tissue despite normal systemic circulation, resulting in organ dysfunction and failure. (5) In this patient, hemodynamic incoherence occurred intraoperatively due to a massive PE which triggered cardiac arrest (**Figure 1**). Macrocirculation deterioration was shown with ventricular fibrillation, unmeasured blood pressure and, unpalpable carotid artery. At the same time, the microcirculation parameters were also inadequately illustrated with lactate level reaching 12.8 mmol/l as a cellular metabolic parameter. Hemodynamic incoherence type 3 occurred in this patient when both macrocirculation and microcirculation were unstable. (4) The mechanism is increased in pulmonary vein pressure resulted in tamponade in microcirculation and deterioration in cellular parameters. (5)

After ROSC, cellular parameters still showed cellular hypoxia where anaerobic metabolism processes occur. This is called resuscitation incoherence type 1. Despite macrovascular parameters being optimized, cellular parameters were still not optimize as shown by high lactate level (7.2 mmol/l) on the first day of care (**Figure 3**).

During ICU treatment we used fluid, inotropic and vasopressor agents, continuous renal replacement therapy (CRRT), and an anticoagulant to correct resuscitation incoherence, and treated ischemic-reperfusion injury to increase patient outcome and survivability.

Fluid, inotropic and vasopressor drugs were titrated to achieve optimal cardiac output and blood

pressure. Increasing cardiac output was the main target for resuscitation and to increase tissue oxygen delivery and achieve oxygen supply and demand. There is no gold standard, but pharmaceutical agents used to support circulation include epinephrine, norepinephrine, dopamine, and dobutamine. (6) In 10 days of care in ICU, macrocirculation targets were optimal, however, CVP tended to increase along with tachycardia during treatment (**Figure 2**). An increase in CVP level was associated with high cumulative fluid balance, increased pulmonary vascular resistance, and the formation of vasoactive mediators due to acute PE (**Figure 5**). This condition would cause a gradual decrease in venous return. Decreased venous return in this case was compensated by tachycardia to increase cardiac output to maintain optimal microcirculation to ensure adequate tissue perfusion.

The only microcirculation parameter able to be monitored in this patient was capillary refill time (CRT). Other parameters such as peripheral perfusion index (PI), tissue oxygen saturation, transcutaneous partial pressure of oxygen, transcutaneous oxygen challenge test, and sublingual microcirculation parameters could not be measured because limited diagnostic tools were available. This patient had normal CRT (<2 seconds) but it cannot be concluded as global normal microcirculation.

CRRT can be used to eliminate cytokine and improve reperfusion injury. In the early stages of ROSC, reperfusion injury process continues with the effect of activating a nonspecific inflammatory process that triggers the release of major systemic inflammatory cytokines such as TNF- α and interleukin-6 (IL-6). Excessive oxidative stress results in the disruption of functional cells. (7,8) High P(v-a)CO₂/C(a-v)O₂ ratio on the first day indicated bad lactate clearance after resuscitation, and this can be used as anaerobic metabolism surrogate and cellular parameter. (2,9) Continuous veno-venous

hemodiafiltration (CVVH) is the primary CRRT mode that can be used as a modality for eliminating cytokines in the systemic circulation. (7,8) In this patient, lactate levels were decreasing and P(v-a)CO₂/C(a-v)O₂ ratio ≤ 1.6 after CRRT (**Figure 3**), indicating cellular parameter improvement after CRRT and no anaerobic metabolism.

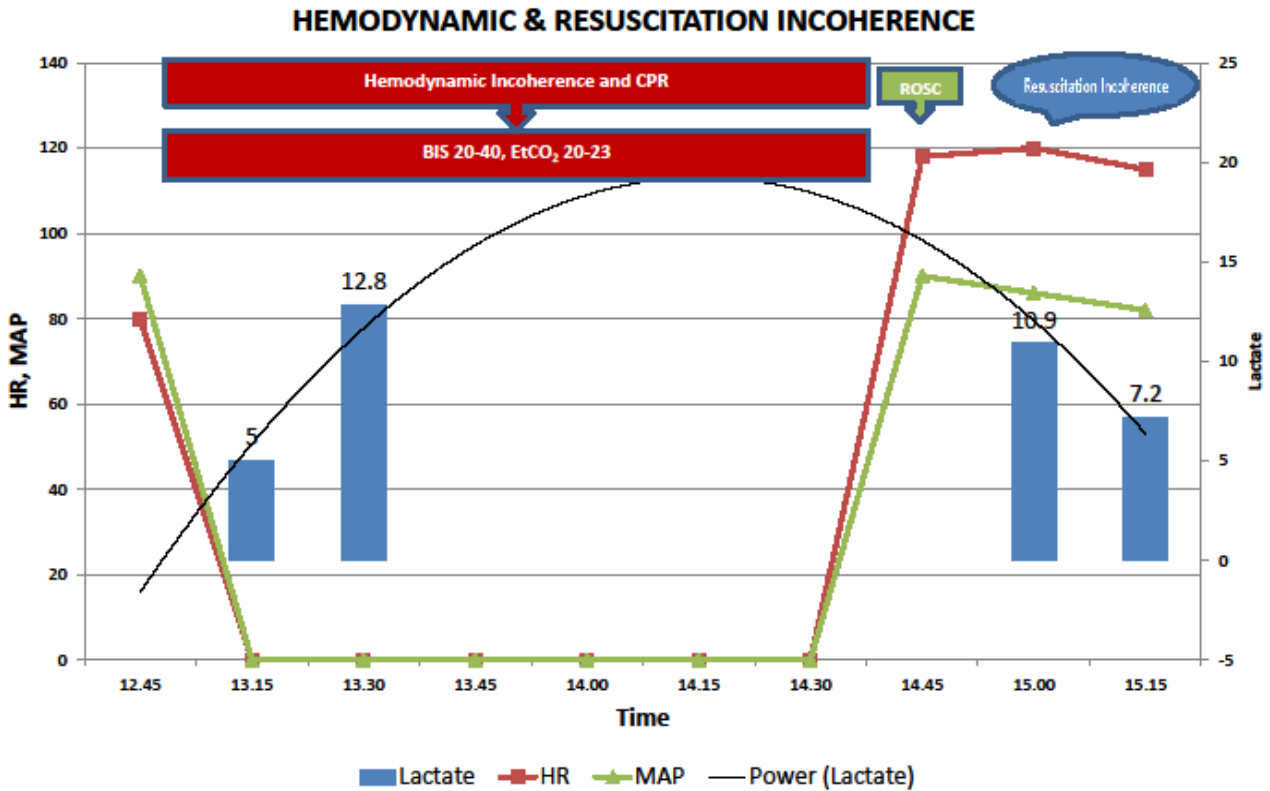
During treatment in the ICU, resuscitation incoherence type 2 still occurred, where occult cell hypoxia can still occur in this condition, even though cellular parameters have improved. In this case, cardiac output was still sufficient to meet the needs of cellular metabolism, as a result of compensatory increases in CVP.

Chronic PE can occur in patients after massive and acute PE. Post resuscitation echocardiography showed right ventricular dilatation, which confirmed the suspicion of PE. Management of chronic PE must also be considered in this patient, as patients with hypercoagulability status are very at risk of the occurrence of chronic PE. In this case, we used heparin to control the thrombosis and emboli with a PTT maintained between 1.5-2.5 times control. (10)

Conclusion

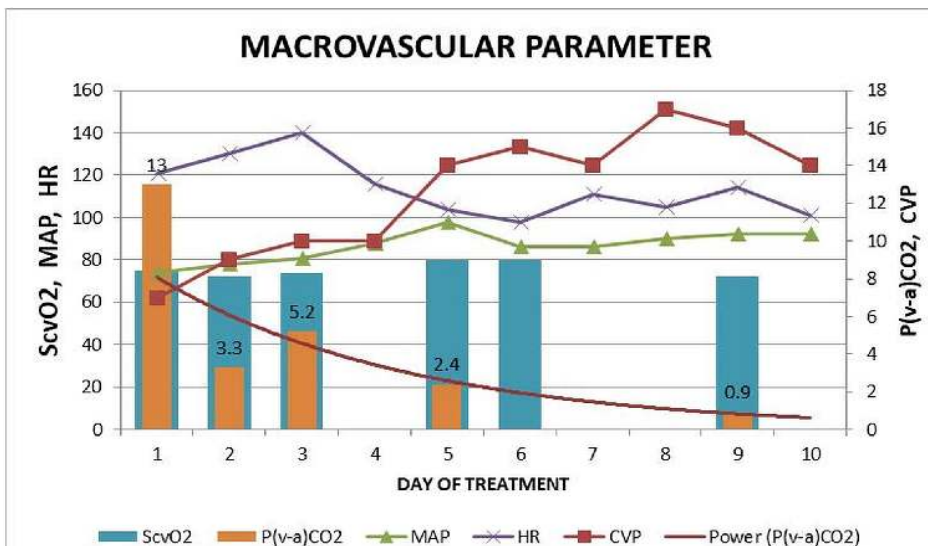
This case emphasizes the importance of monitoring macrocirculation, microcirculation, and cellular parameters after resuscitation. The mismatch between macrocirculation, microcirculation, and cellular parameters is known as hemodynamic and resuscitation incoherence. Hemodynamic and resuscitation incoherence, in this case, was triggered by intraoperative cardiac arrest caused by pulmonary embolism. The resuscitation target was to achieve hemodynamic coherence. Appropriate management and evaluation after ROSC must be carried out to ensure an optimal microcirculation and cellular parameter to achieve the resuscitation coherence, and to improve the patient outcome and survivability.

Figure 1. Hemodynamic and resuscitation incoherence



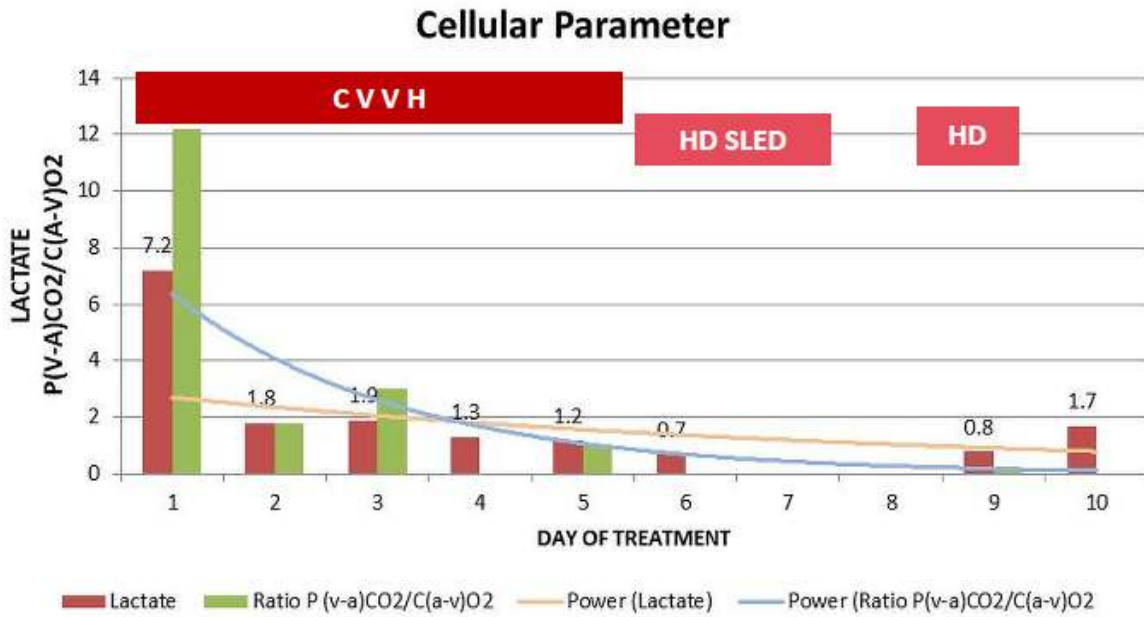
Legend: HR=heart rate; MAP=mean arterial pressure; CPR=cardio-pulmonary resuscitation; BIS= bispectral index; EtCO₂=end-tidal carbon dioxide; ROSC=restore of spontaneous circulation.

Figure 2. Macrovascular parameters



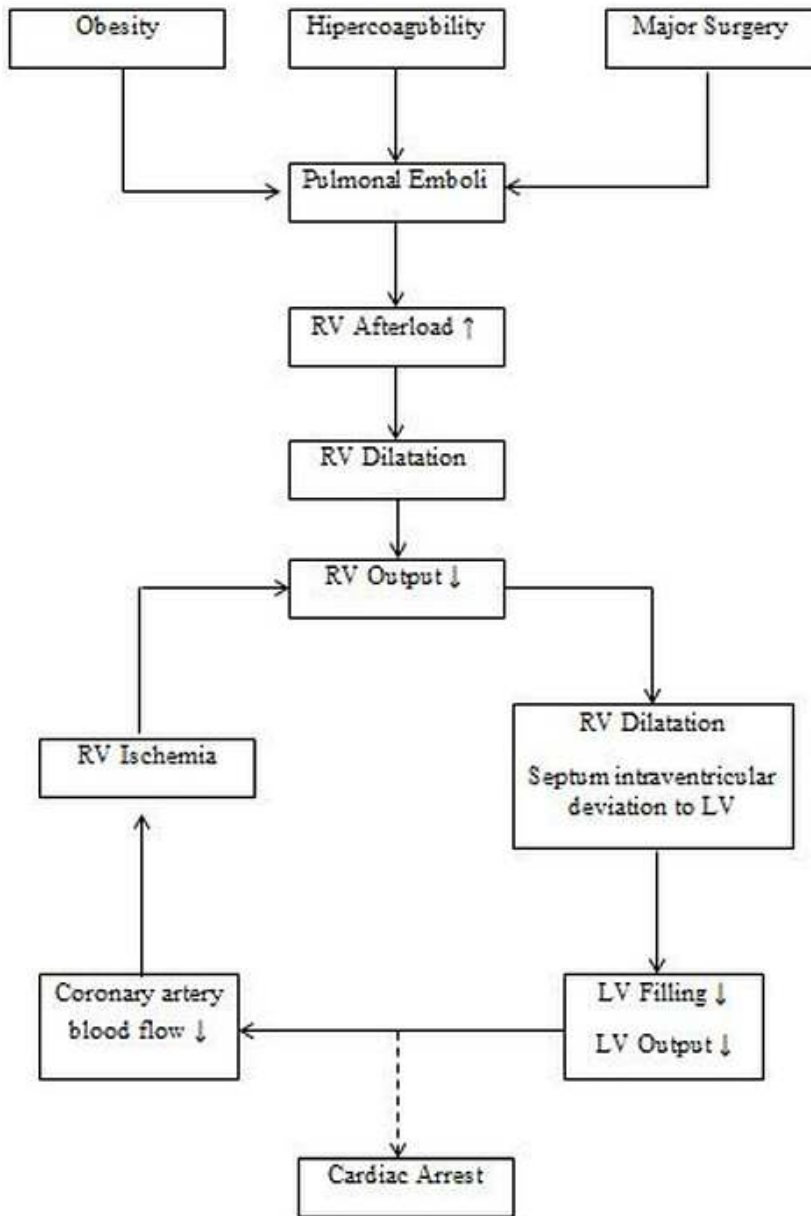
Legend: ScVO₂=central venous oxygen saturation; MAP=mean arterial pressure; HR=heart rate; P(v-a)CO₂=venoarterial carbon dioxide tension; CVP=central venous pressure.

Figure 3. Cellular parameters



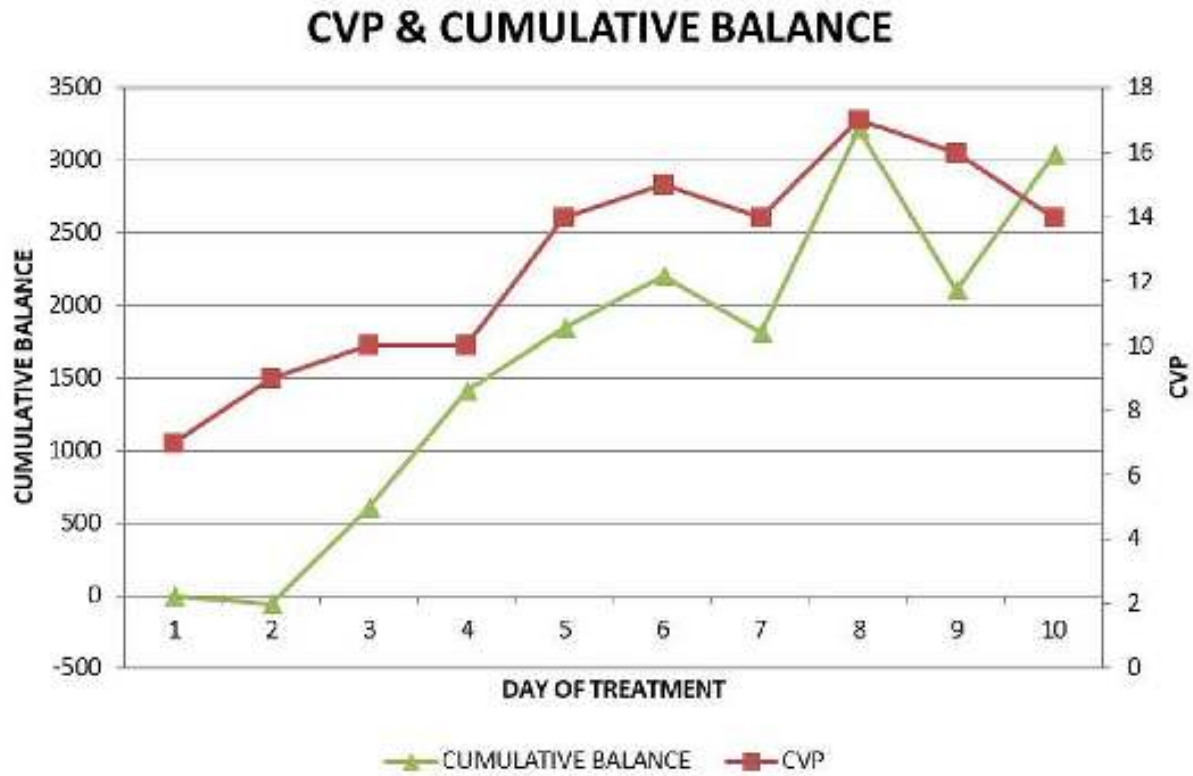
Legend: P(v-a)CO₂=venoarterial carbon dioxide tension difference; C(a-v)O₂=arteriovenous oxygen content difference; CVVH=continuous veno-venous hemodiafiltration; HD=hemodialysis; SLED=sustained low efficiency dialysis.

Figure 4. Intraoperative cardiorespiratory arrest and pulmonal emboli pathophysiology



Legend: RV=right ventricle; LV=left ventricle.

Figure 5. CVP level and fluid balance



Legend: CVP=central venous pressure.

References

1. Desciak MC, Martin DE. Perioperative pulmonary embolism : diagnosis and anesthetic management. *J Clin Anesth* 2011;23:153-65.
2. He H-W, Long Y, Liu D-W, Ince C. Resuscitation incoherence and dynamic circulation-perfusion coupling in circulatory shock. *Chin Med J (Engl)* 2019;132:1218-27.
3. Hinkelbein J, Andres J, Thies K-C, Robertis EDE. Perioperative cardiac arrest in the operating room environment : a review of the literature. *Minerva Anesthesiol* 2017;83:1190-8.
4. Arnemann P, Seidel L, Ertmer C. Haemodynamic coherence - The relevance of fluid therapy. *Best Pract Res Clin Anaesthesiol* 2016;30:419-27.
5. Ince C. Hemodynamic coherence and the rationale for monitoring the microcirculation. *Crit Care* 2015;19:S8.
6. Pothiwala S. Post-resuscitation care. *Singapore Med J* 2017;58:404-7.
7. Peng Y, Yuan Z, Li H. Removal of inflammatory cytokines and endotoxin by veno-venous continuous renal replacement therapy for burned patients with sepsis. *Burns* 2005;31:623-8.
8. Shinozaki K, Lampe JW, Kim J, Yin T, Da T, Oda S, et al. The effects of early high-volume hemofiltration on prolonged cardiac arrest in rats with reperfusion by cardiopulmonary bypass: a randomized controlled animal study. *Intensive Care Med Exp* 2016;4:25.
9. Gavelli F, Teboul J-L, Monnet X. How can CO₂ -derived indices guide resuscitation in critically ill patients? *J Thorac Dis* 2019;11:S1528-37.
10. Smythe MA, Priziola J, Dobesh PP, Wirth D, Cuker A, Wittkowsky AK. Guidance for the practical management of the heparin anticoagulants in the treatment of venous thromboembolism. *J Thromb Thrombolysis* 2016;41:165-86.