

# Ethambutol-induced nephrotoxicity: case report and review of the literature

*Stephanie Pablo, Joseph Gathe, Joseph Varon*

## Abstract

**Ethambutol is a common component in the treatment of mycobacteria infections worldwide, and is rarely associated with nephrotoxicity. We report a patient**

**presenting with acute kidney injury due to ethambutol as well as its management and a comprehensive review of the pertinent literature.**

**Key words:** Ethambutol, acute kidney injury, nephrotoxicity, AIDS, HIV, Mycobacterium avium complex.

## Introduction

Ethambutol is a commonly used agent in a variety of mycobacterial infections. (1,2) This agent is known to produce in some cases ocular toxicity, manifested as optic neuritis which can lead to irreversible loss of vision. (3) While hyperuricemia and liver injury have been reported, nephrotoxicity due to ethambutol has rarely been reported. (4,5) We recently had one such case.

## Case report

A 43-year-old gentleman with human deficiency virus (HIV) infection, complicated by disseminated Mycobacterium avium complex (MAC) infection, disseminated Cytomegalovirus (CMV) infections, chronic pancreatitis

and recurrent pneumocystitis jiroveci pneumonia (PJP) infection, presented to the emergency department (ED) of our institution with complaints of fever, chills, shortness of breath, cough, altered mental status and problems urinating. His symptoms begin a week prior to presentation and began about 72 hours after beginning ethambutol for his recently diagnosed MAC infection. The patient had a prior normal renal function, even in the face of receiving Viread® (Tenofovir disoproxil fumarate) over a period of 8 years.

On physical examination, his blood pressure was 111/75 mmHg, heart rate 116/min, respiratory rate 18/min, temperature 97.5 °F and the SpO2 98% while breathing room air. Additionally, he appeared well developed, somewhat confused, with a normal cardiopulmonary examination. Abdominal exam revealed no organomegaly. Neurological exam had a Glasgow Coma Score of 14/15, somewhat confused to person and place, motor exam was equal and symmetrical, sensory was 4/5 in upper and lower extremities, cranial nerves yielded no focal abnormalities.

Pertinent admission laboratory data revealed a serum creatinine 9.03 mg/dl, blood urea nitrogen (BUN) 75mg/dl, sedimentation rate of 135. Urine analysis had pH 5, protein +1, blood +1, white blood cell (WBC) 5-10/HPF, red blood cells (RBC) 10-20/HPF and rare hyaline casts. Bilateral kidney ultrasonography showed no evidence of hydronephrosis or obstruction. A lumbar puncture revealed no evidence of alterations in the cerebrospinal fluid analysis.

---

From Dorrington Medical Associates, PA, Universidad Autonoma de Baja California, Houston, Texas, USA (Stephanie Pablo), University General Hospital, Houston, Texas, USA (Joseph Gathe), and The University of Texas Health Science Center at Houston, The University of Texas Medical Branch at Galveston, University General Hospital, Houston, Texas, USA (Joseph Varon).

### Address for correspondence:

Joseph Varon, MD, FACP, FCCP, FCCM  
2219 Dorrington Street  
Houston, Texas, 77030, USA  
Tel: +1-713-669-1670  
Fax: +1-713-669-1671  
Email: Joseph.Varon@uth.tmc.edu

All cultures remained negative during his hospitalization and there was no evidence of new recurrent bacteria or opportunist infections.

The patient was admitted to the intensive care unit (ICU) due to concerns of evolving kidney injury and possible hemodynamic decompensation. Serum creatinine increased to 10.66 mg/dl and BUN 83 mg/dl 7 hours post admission. Emergency renal replacement therapy with hemodialysis (HD) was started and ethambutol was discontinued. Over the next 72 hours, his renal function improved with hemodialysis (**Figure 1**).

Additional laboratory work up yielded no evidence of vasculitis, acute interstitial nephritis or other causes for acute kidney injury. Over the next several days, the patient improved and was eventually discharged to a long-term care facility for rehabilitation management of his acute deconditioning.

### **Methodology of our literature review**

Our aim was to identify all relevant clinical trials, case series and case reports that showed the relation between ethambutol and acute kidney injury (AKI). Our primary end point was AKI in the context of ethambutol administration. There was no restriction as to the type of patient, clinical setting, or language in which the study or case was reported. We used a multi-method approach to identify relevant studies and cases for this review. All authors independently searched the National Library of Medicine's Medline database for relevant studies, case series and case reports published from 1966 to January 2013 using the following medical subject headings and keywords: ethambutol, acute kidney injury, renal failure, mycobacteria, side effects, adverse reactions. In addition, we searched Embase and the Cochrane Database of Systematic Reviews. Bibliographies of all selected articles and review articles that included information on ethambutol and kidney injury were also included. This search strategy was done iteratively, until no new potential citations were found.

### **Discussion**

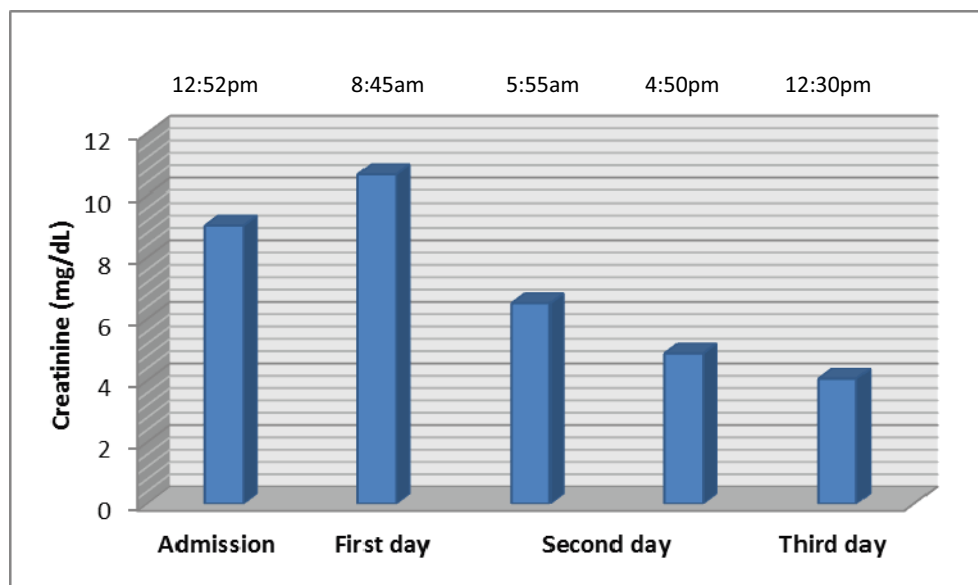
Our comprehensive review of the literature evaluating

the possibility of ethambutol inducing renal dysfunction, only revealed 5 prior instances of such occurrence. (6-9) No single clinical trial reported acute kidney injury as an adverse event of ethambutol. All patients were reported as case reports. In all instances, the primary pathogenic mechanism was acute tubulointerstitial nephritis proved by kidney biopsy. (7) In all cases, ethambutol was being utilized due to a previous infection with Mycobacterium tuberculosis. Each patient identified in our literature search had a different onset of the AKI. The first case identified, was that of 52-year-old gentleman who developed signs of kidney failure nine weeks after the initiation of ethambutol treatment. (8) Second case involved a 33-year-old male who developed AKI on the third day of initiation of ethambutol therapy and this patient was started with hemodialysis helping to improve the kidney function. (9) The third patient is a 58-year-old female after 5 weeks of administration of ethambutol developed renal insufficiency. (6) Next case a man of 56-year-old with recurrent tuberculosis treated with ethambutol approximately one month after treatment, kidney injury was noted and confirmed by kidney biopsy with the findings of tubular damage and diffuse interstitial fibrosis. (7) Last case reported in the literature is 69-year-old male. In this case it was on the fifth month when the patient was readmitted for adverse effects of the medication also the kidney biopsy showed some damage sclerosed glomeruli and tubular atrophy. (7) The common point in all cases identified in our literature review was that after ethambutol was discontinued, the renal function began to recover and no long-term renal dysfunction prevailed.

In our patient's case, while having the other potential etiologies of renal dysfunction, including but not limited to, Viread®, sepsis or HIV, none of these etiologies would explain the acute renal dysfunction or its reversal after discontinuation of ethambutol. (10,11) As the patient was clinical improving by renal replacement therapy initially and discontinuation of ethambutol, we thought it would be unsafe and unnecessary to do a renal biopsy in this clinical situation. We found no other explanation for this patient's AKI. In follow up, 2 months later, the patient is doing well with a normal renal function.

Healthcare providers need to consider ethambutol as a potential etiology in patients with unexplained nephrotoxicity, as this condition is treatable and potentially reversible when ethambutol is stopped.

**Figure 1.** The patient's creatinine levels. Hemodialysis was started on the second day



## References

1. Katoch VM. Infections due to non-tuberculous mycobacteria (NTM). *Indian J Med Res* 2004;120:290-304.
2. Henry MT, Inamdar L, O'Riordain D, Schweiger M, Watson JP. Nontuberculous mycobacteria in non-HIV patients: epidemiology, treatment and response. *Eur Respir J* 2004;23:741-6.
3. Sadun AA, Wang MY. Ethambutol optic neuropathy: How we can prevent 100,000 new cases of blindness each year. *J Neuroophthalmol* 2008;28:265-8.
4. Narang RK, Agarwal MC, Raina AK, Singh SN, Bihari K, Sharma SN. Hyperuricemia induced by ethambutol. *Br J Dis Chest* 1983;77:403-6.
5. Younossian AB, Rochat T, Ketterer JP, Wacker J, Janssens JP. High hepatotoxicity of pyrazinamide and ethambutol for treatment of latent tuberculosis. *Eur Respir J* 2005;26:462-4.
6. Garcia-Martin F, Mampaso F, de Arriba G, Moldenhauer F, Martin-Escobar E, Saiz F. Acute interstitial nephritis induced by ethambutol. *Nephron* 1991;59:679-80.
7. Collier J, Joeekes AM, Philalithis PE, Thompson FD. Two cases of ethambutol nephrotoxicity. *Br Med J* 1976;2:1105-6.
8. Stone WJ, Waldron JA, Dixon JH Jr, Primm RK, Horn RG. Acute diffuse interstitial nephritis related to chemotherapy of tuberculosis. *Antimicrob agents chemother* 1976;10:164-72.
9. Kwon SH, Kim JH, Yang JO, Lee EY, Hong SY. Ethambutol-induced acute renal failure. *Nephrol Dial Transplant* 2004;19:1335-6.
10. Hall AM, Hendry BM, Nitsch D, Connolly JO. Tenofovir-associated kidney toxicity in HIV-infected patients: a review of the evidence. *Am J Kidney Dis* 2011;57:773-80.
11. Lam M, Park MC. HIV-associated nephropathy--beneficial effect of zidovudine therapy. *N Engl J Med* 1990;323:1775-6.