

Two case reports of colchicine overdose: An uncommon and potentially difficult diagnosis

Kavi Haji, Ravindranath Tiruvoipati, John Botha, Darsim Haji

Abstract

Colchicine overdose is rare but potentially a life threatening toxicological emergency. The severity of colchicine toxicity does not necessarily correlate with the amount of colchicine ingested and may depend on co-ingested agents. Some patients require intensive care. We report two cases of colchicine overdose with unusual presentations requiring intensive care.

Case 1: A 37-year-old man took an overdose (10 mg) of colchicine and an unknown quantity of methamphetamine. He presented to the emergency department with an acute abdomen and shock. An abdominal CT after resuscitation revealed ischaemic bowel and extensive hepatic portal vein gas. An emergency laparotomy revealed an ischaemic right colon and patchy necrosis of the distal small bowel. Resection of ischemic bowel was performed with the formation of an ileostomy and a colostomy. However the patient continued to deteriorate and died shortly after admission to the ICU.

Case 2: A 32-year-old female presented with history of brodifacoum and indomethacin overdose. She developed multi-organ failure that required ICU admission for mechanical ventilation and inotropic therapy. While in ICU, she developed bone marrow aplasia. Clinical features and progression at this stage were classic of colchicine overdose. A detailed history at this stage revealed colchicine overdose. The patient survived with aggressive intensive care support and GCSF.

Comment: Case 1 suggests a possible synergism between colchicine and methamphetamine that lead to the development of ischaemic gut and portal venous gas, an uncommon presentation of colchicine overdose. Case 2 was a challenge in spite of classic presentation of colchicine toxicity, as the initial history did not include colchicine as the drug of overdose.

Key words: colchicine, overdose, hepatic portal vein gas.

Introduction

Colchicine is a highly active alkaloid derived from *Colchicum autumnale* and *Gloriosa superba*. It is used in treatment of

gouty arthritis, pseudogout, familial Mediterranean fever and Behcet's disease. Colchicine overdose is rare but is potentially life threatening.

We report 2 cases of serious colchicine overdose. Case 1 presented with multiorgan failure resulted in death within 48 hours post ingestion. Case 2 underwent typical phases of colchicine toxicity, yet the history was misleading on initial presentation.

Case 1

A 38-year-old, 90 kg Caucasian male, presented to the

From Department of Intensive Care, Department of Emergency Medicine, Frankston Hospital, Peninsula Health, Frankston, Victoria, Australia (Kavi Haji, Ravindranath Tiruvoipati, Darsim Haji, and John Botha)

Address for correspondence:

Dr Kavi Haji

Department of Intensive Care medicine

Frankston Hospital, Frankston, Victoria 3199, Australia

Tel: 0061403502645

Email: kevee@bigpond.com

emergency department (ED) 31 hours after ingesting 20 tablets of 0.5 mg of colchicine. He also admitted to injecting unknown quantity of methamphetamine (MA) concurrently. He had a past history of intravenous drug use. Five hours past ingestion, the patient developed nausea, vomiting, diarrhoea and abdominal pain.

On arrival to ED, the patient was conscious and alert. He was mottled, tachycardic and hypotensive. He had a soft abdomen and it was generally tender. Ischemic bowel was strongly suspected due to patient's profound lactic acidosis. His pH, bicarbonate and base excess were 7.07, 6 and -24.5 respectively.

The CT scan of the abdomen revealed an extensive necrosis of the right hemi-colon and several distal small bowel loops with intramural gas. There was an extensive gas throughout the portal venous system involving left lobe of liver and non-dependent portions of the right lobe of liver and extensive gas in the superior mesenteric vein (**Figures 1a** and **1b**).

Despite aggressive resuscitation, the patient rapidly progressed to multiorgan failure requiring intubation, mechanical ventilation and inotropic support. Due to profound acidosis and acute renal failure, continuous renal replacement therapy was initiated. Emergency laparotomy revealed ischaemic right colon and patchy necrosis of distal small bowel. The ischaemic bowel was resected, ileostomy and colostomy were constructed. The patient progressed to asystolic cardiac arrest 12 hours post admission and he died in the intensive care unit (ICU).

The histopathology showed loss of villous pattern, mucosal ischaemic changes and areas of congestion and haemorrhage. His post-mortem toxicology revealed a colchicine level of 0.4 mg/L (method of analysis HPLC). Antemortem serum MA level was 0.6 mg/L (method of analysis SIM/GC-B/MS). Ethanol and paracetamol levels were insignificant. The post-mortem histology of the remaining bowel revealed normal villous pattern and no inflammation. The heart and the coronary arteries were normal. There were mild ischaemic changes in the liver with no evidence of inflammation and his bone marrow was normal. The post-mortem concluded that the cause of death was multi-organ failure due to colchicine overdose.

Case 2

A 32-year-old, 70 kg female, presented to ED with nausea, vomiting, diarrhoea and severe abdominal pain of 12 hours duration. She reported ingesting 150 grams (2.5 g/kg) of brodifacoum and 36 tablets of 25 mg (13 mg/kg) of indomethacin 27 hours earlier. The patient strongly and repeatedly denied any other overdoses. Her past history included depression, self-harm and multiple suicidal attempts.

She was alert and was clinically hypovolaemic. Her abdomen was tender but soft. She had lactic metabolic acidosis with pH 7.21, bicarbonate 17, base excess -9 and lactate 3.6.

The CT scan of the abdomen revealed diffused bowel thickening suggestive of a moderate enterocolitis. There was no radiological evidence of perforation or haemorrhage. Brodifacoum induced coagulopathy was corrected with intravenous vitamin K. She was admitted to ICU for monitoring and further evaluation.

The following day, the patient became hypoxic and hypotensive requiring endotracheal intubation and noradrenaline infusion. The abdomen was tender and guarded. Emergency laparotomy revealed oedematous bowels and moderate ascites with no bleeding, perforation or ischaemia. From day 2 the patient progressively developed pancytopenia with white cell count, neutrophil, platelets reached nadir of 0.4, 0.1 and 3 respectively. Intravenous antibiotics were commenced for suspected sepsis. The patient was also placed on daily intravenous granulocyte colony stimulating factor (G-CSF) for presumptive neutropenic sepsis. Repeated cultures of the blood, the sputum and the urine revealed no growth.

Drug induced myelosuppression remained highly suspected. On further request, repeated search of the family home was conducted. An empty bottle of colchicine was discovered, which admittedly belonged to patient's husband from 3 years earlier for gout.

On day 4 post admission to ICU, the patient developed epistaxis, abdominal wound oozing and vaginal bleeding due to marked thrombocytopenia. Her coagulation profile was normal. Two weeks after admission pancytopenia recovered. Alopecia was noted at 2 weeks past presentation. Shortly

after extubation, the patient confirmed taking 50 tablets of 0.5 mg of colchicine as an impulsive attempt to self-harm. She stayed in ICU for 16 days and she was discharged from the hospital 4 days later with no significant sequelae.

Discussion

Colchicine has potent anti-mitotic activity. It binds reversibly and selectively, to tubulin, a microtubular protein and it inhibits cell division in metaphase. Colchicine disrupts the function of mitotic spindles in cells that are capable of dividing and migrating. The cells with highest turnover such as gastrointestinal epithelium, hair follicles, and bone marrow are most affected.

Colchicine is rapidly absorbed from gastrointestinal (GI) tract after ingestion, reaching peak plasma concentration within 2 hours. It's primarily deacetylated in the liver. The unchanged drug and its metabolites are excreted in bile, which undergoes enterohepatic recirculation. Recycling of colchicine probably accounts for the extensive intestinal manifestation of toxicity. Renal clearance accounts for 10%-20% of colchicine removal and in toxicity larger fractions can be excreted. However, if renal and hepatic impairment coexist, risk of toxicity is greatly increased even with therapeutic doses. (1) Colchicine toxicity is a well-described clinical entity consists of 3 stages. In the first 24 hours, GI symptoms and hypovolaemia predominate. Stage 2 usually develops 24 to 72 hours post ingestion, which involves multi-organ failure. Most deaths occur during stage 2. (2) The third stage is characterized by rebound leukocytosis, resolution of multiorgan failure, and transient alopecia. (1,2) Early fatality results from cardiovascular collapse and respiratory failure. (3)

The overdose in our patients resulted in multiorgan failure and tragic death of case 1. Both patients developed a predictable sequence of primary GI toxicity. The GI involvement in case 1 progressed to bowel ischaemia, pneumatosis intestinale and hepatic portal vein gas (HPVG). Iacobuzio-Donahue et al (4) described distinctive histopathologic features of gastrointestinal biopsies from patients with colchicine toxicity. The features include mitotic arrest in metaphase, mucosal changes, apoptosis and villous atrophy. The biopsy from case 1 showed mucosal changes, loss of surface epithelium and loss of

villous pattern suggestive of colchicine toxicity. However, the mucosal ischaemic changes, the marked congestion of submucosa and the areas of haemorrhages is possibly caused by MA. (5)

Saksena et al (6) described HPVG in a 57-year-old man post colchicine overdose. The HPVG was associated with small bowel thickening that has spontaneously resolved. These findings were attributed to colchicine induced bowel mucosal injury. Fatal colchicine related bowel ischaemia with HPVG has not been reported previously. Furthermore, HPVG has not been linked to MA, brodifacoum or non-steroidal anti-inflammatory drugs. Of note, due to potent sympathomimetic effect of MA, a synergistic interaction between colchicine and MA was entertained as a possible mechanism.

Any colchicine overdose should be considered potentially lethal. In case 1, the amount of colchicine ingested that resulted in death was 0.115 mg/kg, whereas; case 2 ingested 0.25 mg/kg, yet she survived. However, fatalities have been reported after ingestion of 7 to 12 mg. (2)

Treatment options for colchicine toxicity are limited. The mainstay therapy is early recognition and supportive treatment. Antidotal immunotherapy has a promising future in eliminating colchicine from the body, (7) but it's still in its experimental stage. In those patients that survive the initial phase of poisoning, G-CSF has been suggested. It may offer an effective treatment for pancytopenia and a prevention of overwhelming septicemia. (8,9) Nevertheless, it's unknown whether recovery is due to therapeutic response or it's a predetermined course of illness. Our patient was initially treated with G-CSF for presumptive sepsis. She was continued on G-CSF due to the remarkable response even when colchicine overdose was confirmed.

Conclusion

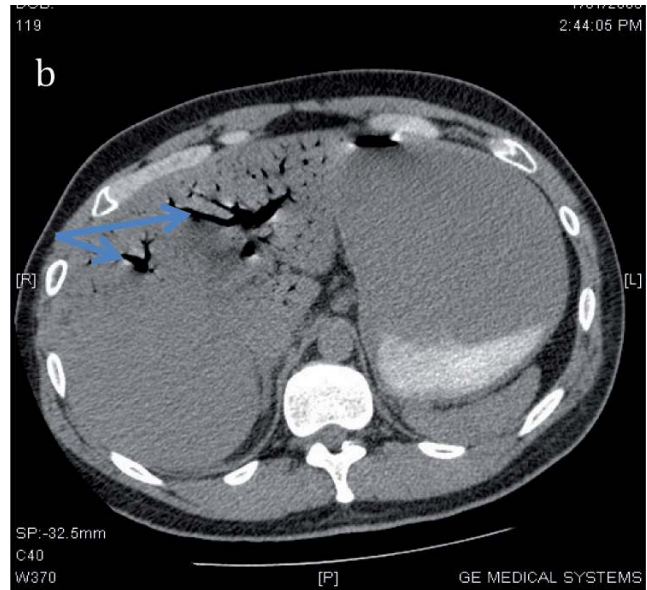
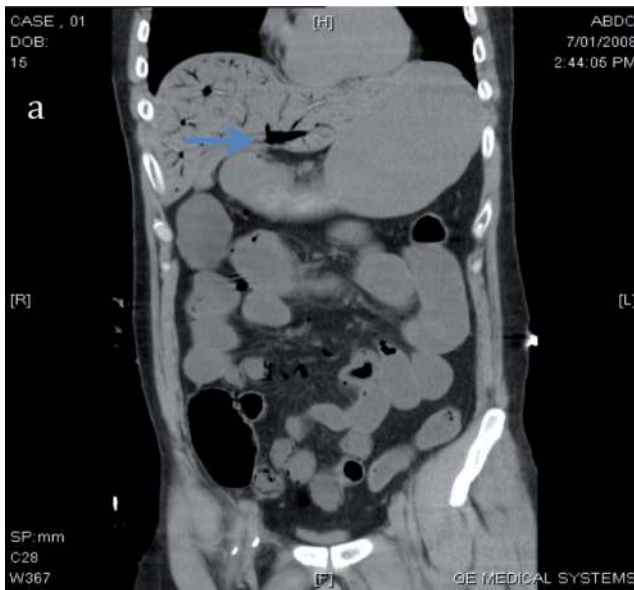Our case report supports previous published data that the severity of colchicine toxicity does not necessarily correlate with the amount taken. Although mortality from colchicine poisoning is widely known, colchicine induced fatal HPVG and bowel ischaemia has not been reported.

Case 2 denotes that high index of suspicion for other possible drugs should be exercised when clinical presentation is not explained by the reported toxins. Management of colchicine toxicity is still supportive, however G-CSF may be considered in colchicine induced myelosuppression.

Conflict of interest

None of the authors has commercial association or financial involvement that might pose a conflict of interest in connection with this article.

Figures 1a and 1b. CT scan of the abdomen, coronal view (left) and axial view (right) respectively, showing extensive gas throughout the portal venous system involving left lobe of liver and non-dependent portions of the right lobe of liver.



References

1. Maxwell MJ, Muthu P, Pritty PE. Accidental colchicine overdose. A case report and literature review. *Emerg Med J* 2002;19:265-7.
2. Stapczynski JS, Rothstein RJ, Gaye WA, Niemann JT. Colchicine overdose: report of two cases and review of the literature. *Ann Emerg Med* 1981;10:364-9.
3. Bismuth C, Gaultier M, Conso F. Medullary aplasia after acute colchicine poisoning. 20 cases. *Nouv Presse Med* 1977;6:1625-9.
4. Iacobuzio-Donahue CA, Lee EL, Abraham SC, Yardley JH, Wu TT. Colchicine toxicity: distinct morphologic findings in gastrointestinal biopsies. *Am J Surg Pathol* 2001;25:1067-73.
5. Johnson TD, Berenson MM. Methamphetamine-induced ischemic colitis. *J Clin Gastroenterol* 1991;13:687-9.
6. Saksena M, Harisinghani MG, Wittenberg J, Mueller PR. Case report. Hepatic portal venous gas: transient radiographic finding associated with colchicine toxicity. *Br J Radiol* 2003;76:835-7.
7. Baud FJ, Sabouraud A, Vicaut E, Taboulet P, Lang J, Bismuth C, et al. Brief report: treatment of severe colchicine overdose with colchicine-specific fab fragments. *N Engl J Med* 1995;332:642-5.
8. Miller MA, Hung YM, Haller C, Galbo M, Levsky ME. Colchicine-related death presenting as an unknown case of multiple organ failure. *J Emerg Med* 2005;28:445-8.
9. Critchley JA, Critchley LA, Yeung EA, Young RP, Young RJ, Chan TY, et al. Granulocyte-colony stimulating factor in the treatment of colchicine poisoning. *Hum Exp Toxicol* 1997;16:229-32.