

## Malignant pericardial effusion presenting as a wheeze- case report

Eng Kiang Lee

### Abstract

Slow growing pericardial effusion is detected less commonly than acute pericardial tamponade. However, it is equally life threatening if it is more than 250 to 300 ml and can contribute to a similar picture of a fix cardiac output ob-

structive shock. We would like to report a case of malignant pericardial effusion that was detected in the ICU when the patient presented to the hospital with shortness of breath and generalized wheezes suggestive of respiratory failure from chronic obstructive lung disease (COPD).

### Introduction

The 76-year-old patient has a background history of hypertension and chronic smoking. He had never presented with the clinical symptoms of chronic obstructive pulmonary disease before despite his long-standing history of smoking. He presented to the emergency department with shortness of breath and impaired effort tolerance for 2 weeks without any signs of fever, productive cough or haemoptysis or loss of weight.

On examination, he was haemodynamically stable with a respiratory rate of 30 per minute and oxygen saturation of 92% on room air with generalized wheezes. AP chest X-ray (CXR) (**Figure 1**) did not show any significant consolidation or pneumothorax. The cardiac shadow was moderately bigger than normal but it was attributed to his hypertension initially. His lungs appeared to be hyperinflated. The arterial blood gas sample that was done showed a picture of type 1 respiratory failure. The clinical signs of general wheezes and hypoxaemia

were attributed to acute exacerbation of bronchospasm with suspected chest infection.

He was given the usual nebulised bronchodilators like salbutamol, ipratropium and intravenous hydrocortisone. The oxygen therapy was administered via a non-invasive ventilator. He improved significantly and was sent to the general ward for further monitoring after 2 hours of therapy in the ED.

However on the same day in the general ward his condition took a turn for the worse and he was sent to the ICU with impending decision for intubation. There was significant evidence of electrical alternans and low voltage ECG waveforms when the monitors were placed. The pulseoximetry and also the arterial waveform showed significant pulsus paradoxus (**Figure 2**).

A 12-lead ECG also confirmed the above findings (**Figure 3**).

Bedside echocardiography was also done and it demonstrated a pericardial effusion that was causing significant compressive effect on the right ventricle at early diastole (**Figures 4, 5, 6**). Percutaneous pericardiocentesis was performed with immediate improvement of symptoms. Subsequently the generalized wheezes also resolved with appropriate episodic nebulization of salbutamol and ipratropium.

A 12-lead ECG also showed low voltage of QRS complexes (**Figure 3**).

A total of 200 ml of haemoserous fluid was drained out and the patient was noted to be less breathless. The clinical parameters, the waveforms and ECG also demonstrated significant improvement (**Figure 7**).

---

From Department of Intensive Care Medicine, Ng Teng Fong General Hospital, Singapore (Eng Kiang Lee).

### Address for correspondence:

Eng Kiang Lee  
Department of Intensive Care Medicine  
Ng Teng Fong General Hospital  
I, Jurong East Street, Singapore 609696  
Tel: +6591144378  
Fax: +653973567  
Email: eng\_kiang\_lee@juronghealth.com.sg

Further 300 ml of fluid was drained via the same catheter on the same day before the catheter was blocked. The fluid revealed metastatic adenocarcinoma cells.

A post procedure CXR in **Figure 8** showing a decrease in size of the cardiac shadow as compared to **Figure 1**. It also demonstrated the position of the catheter.

A CT scan of the thorax later on confirmed the finding of a left bronchial mass suggestive of lung malignancy. This also established the possibility of metastasis to the pericardium via the haematogenous route. The patient was subsequently referred to the respiratory physician, oncologist and cardiothoracic for subsequent management of his condition.

### Discussion

Pericardial effusion progressing to cardiac tamponade can occur virtually in any condition of patients. Clinical signs and symptoms of cardiac tamponade may mimic other diseases, which unfortunately may delay the diagnosis of a cardiac tamponade. The compressive effects of a tamponade occur with limitation of ventricular diastolic filling and reduction of cardiac output. In acute traumatic injuries causing major vessel rupture or myocardial rupture, sudden death can occur unless an immediate drainage or surgical intervention is established. (1,2)

Malignancy is the most common cause of pericardial effusion in the Western world. (3-5) The pericardial effusion that occurs in patients with malignancy could be secondary to malignancy itself or it could be an inflammatory process. In some studies it could be related to non malignant disease processes such as radiation pericarditis or opportunistic infection. (3)

Smoking is still the highest risk factor for lung malignancy and unfortunately for this patient it has

metastasized to the pericardium when it was diagnosed. Neoplastic pericardial effusion is a serious disorder and can contribute to an obstructive phenomenon with serious life threatening effect. This could precipitate an increase in impaired tolerance and also breathlessness as in this patient.

The clinical presentation may not be detected all the time especially the clinical signs of Becker triad were not obvious in this patient. He was having generalized wheezes and muffled heart sound was not easily detected. The patient was quite an obese patient and the raised jugular venous pressure was not easily seen. At the point when the diagnosis was made he was not significantly hypotensive.

Malignancy was not suspected when he presented to the ED as the initial symptoms and signs suggested otherwise a respiratory condition rather than a cardiac problem.

Although cardiac tamponade is a clinical diagnosis, clinical findings may sometimes have limited sensitivity and specificity.

Approximately 20% of large symptomatic effusions without an obvious etiology based on routine diagnostic examination constitute the initial presentation of a previously undiagnosed cancer. (6) This unfortunately was true for this patient as there was no obvious clinical sign prior to this event, which led to the discovery of malignancy in the lungs.

Clinicians should recognize and correlate the bedside echocardiographical signs of cardiac tamponade such as right ventricle collapse, right atrium collapse, respiratory variation of the mitral and tricuspid flow, and inferior vena cava plethora (7,8) in establishing the severity of the effusion or tamponade. The presence of bedside echo machines in the ICU and the fact that more doctors other the cardiologists are trained to read and diagnose abnormalities have significantly enhanced the diagnosis of cardiac tamponades.

Figure 1.

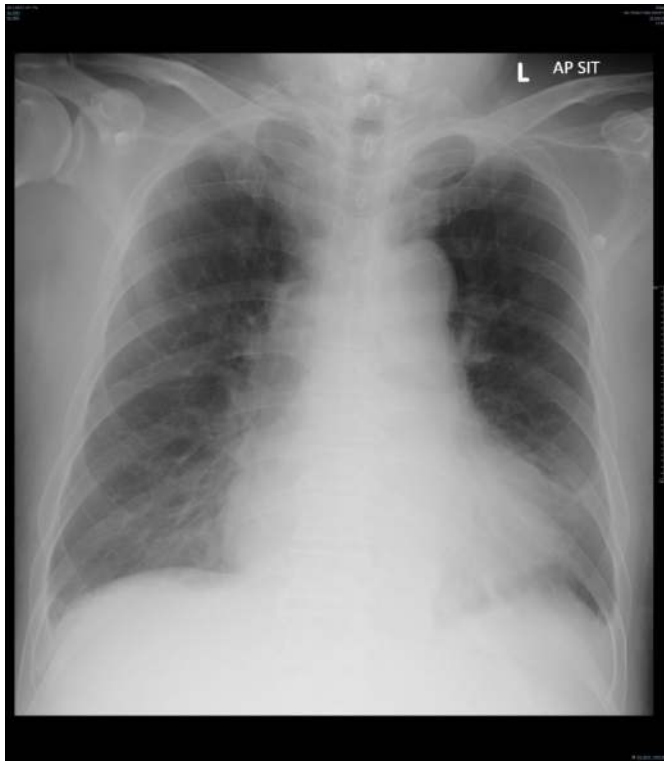

Figure 2.

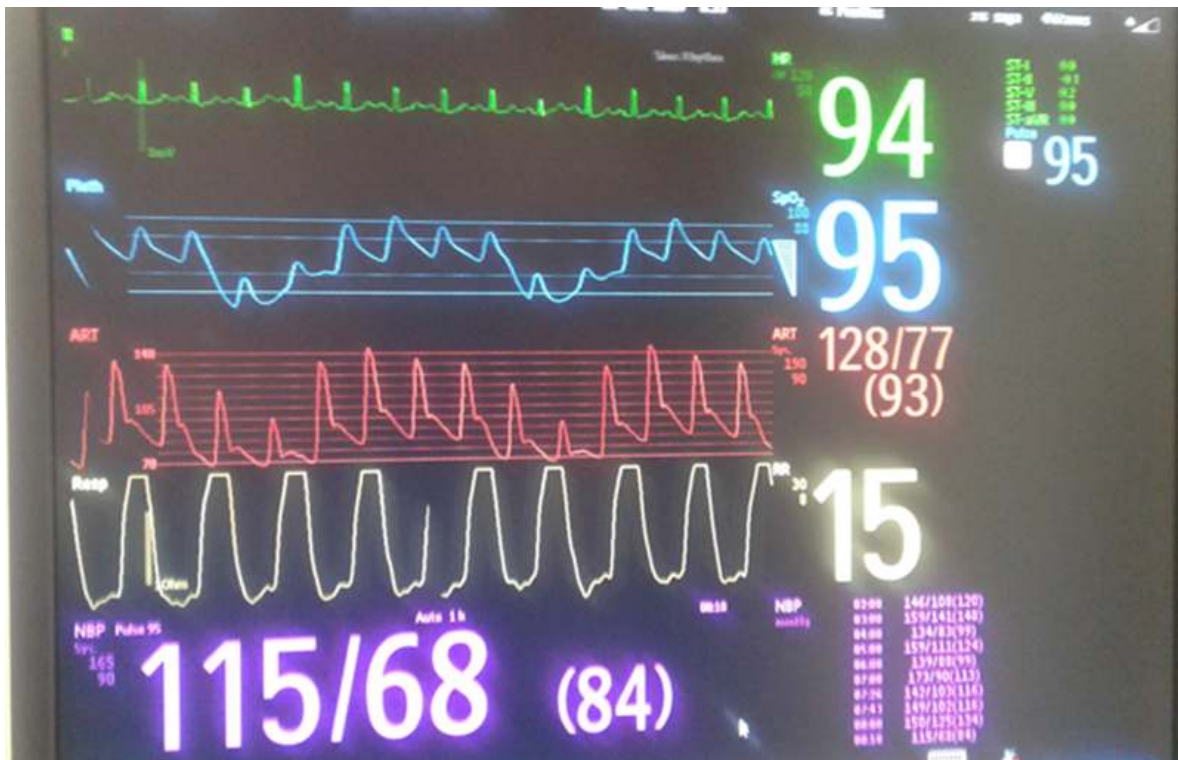

Figure 3.

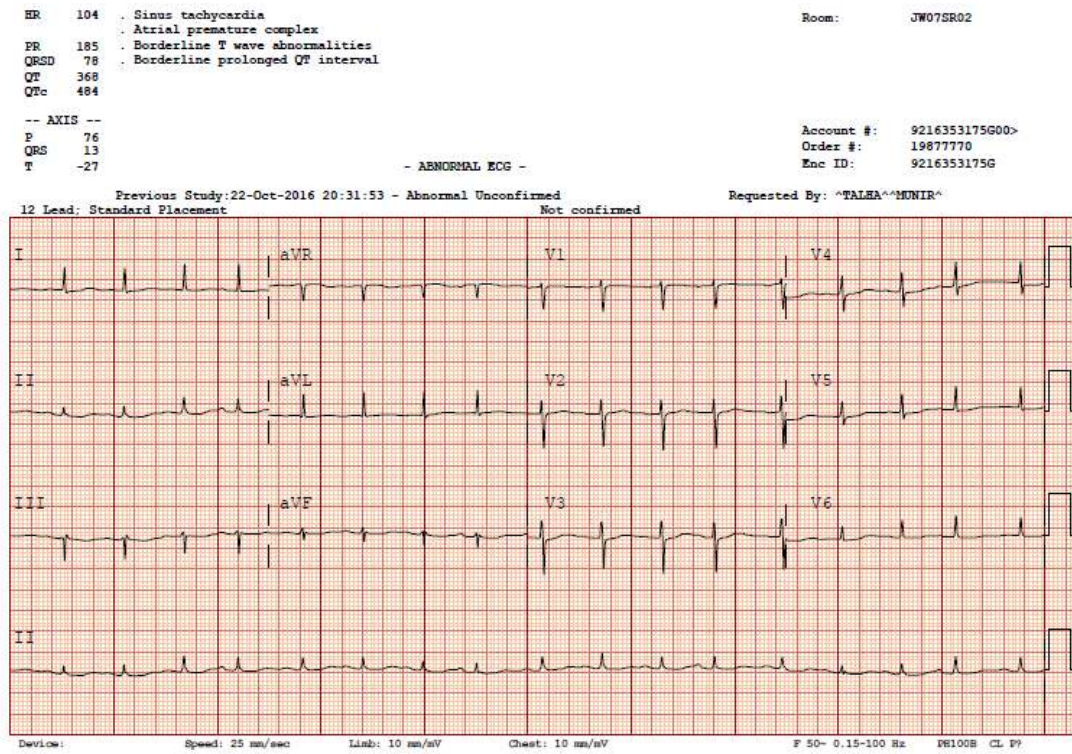


Figure 4.

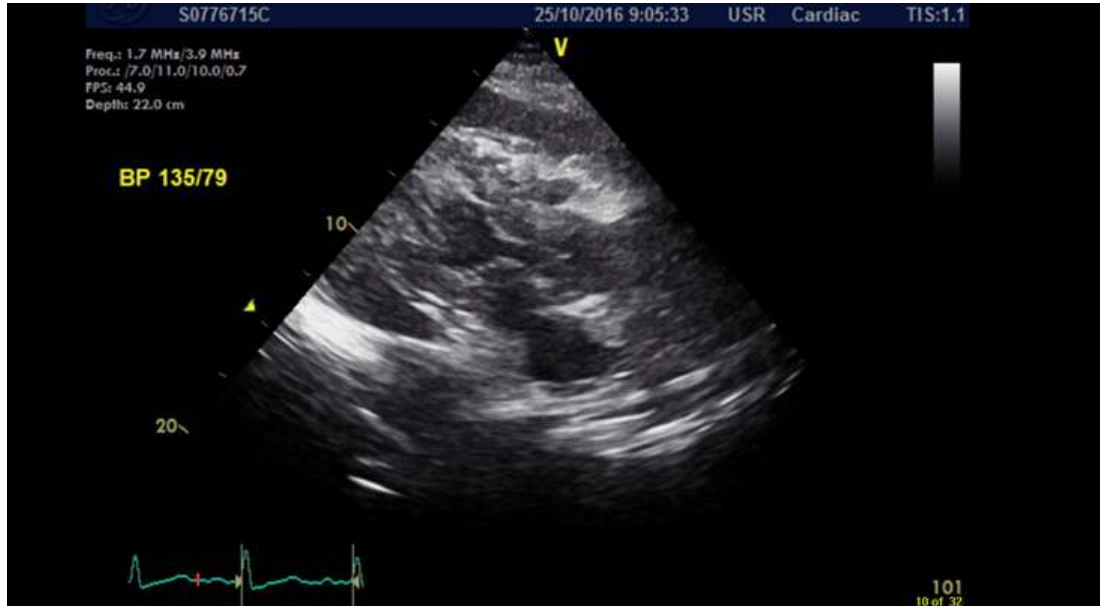


Figure 5.

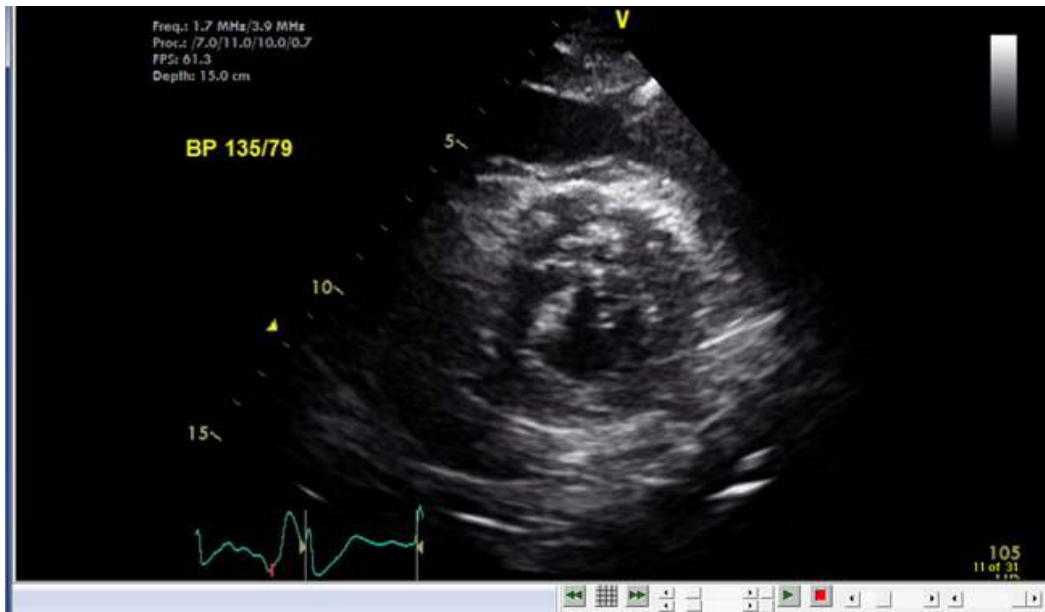


Figure 6.

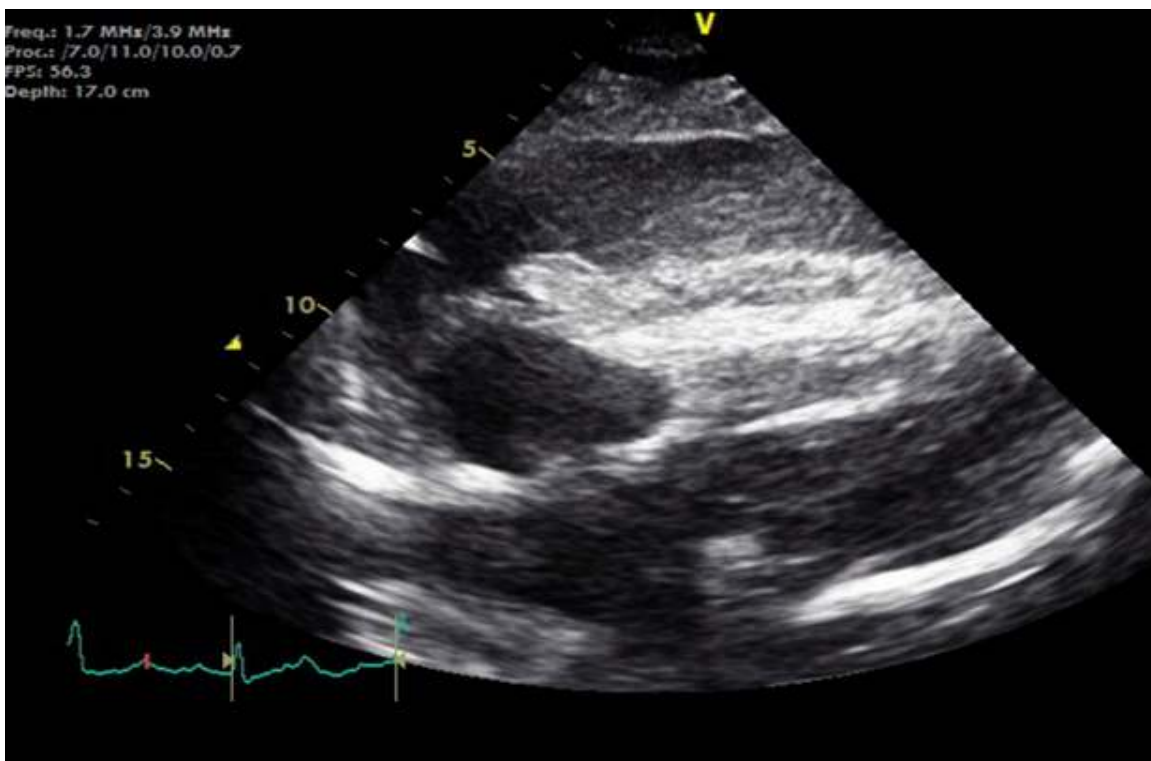


Figure 7.

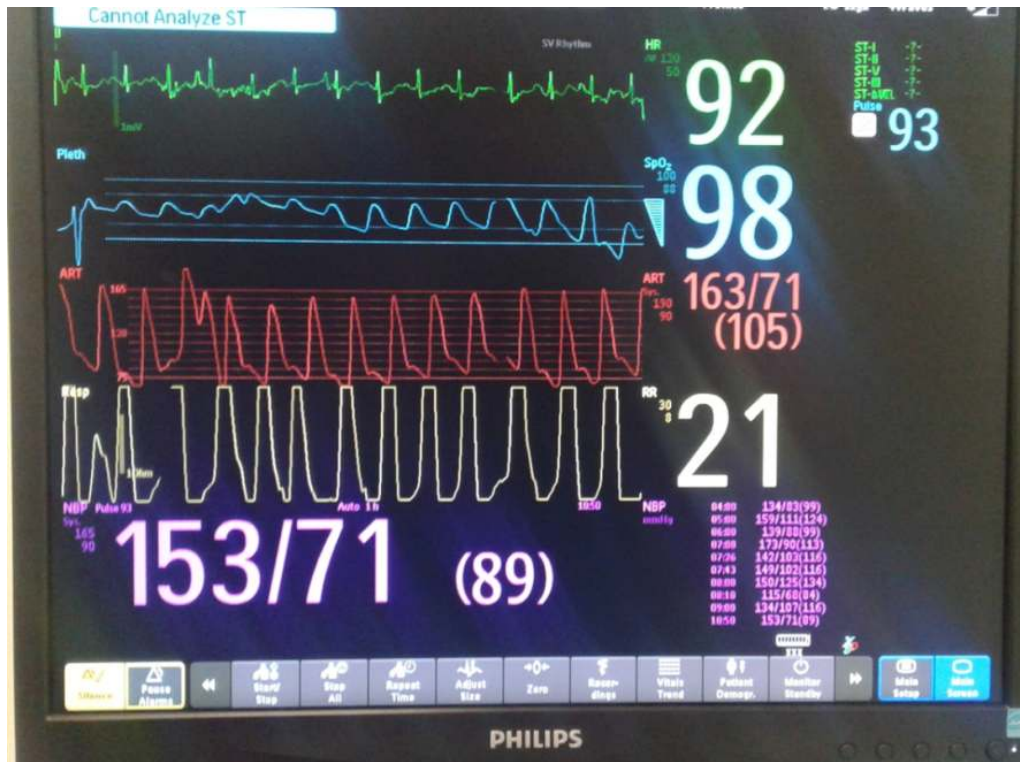
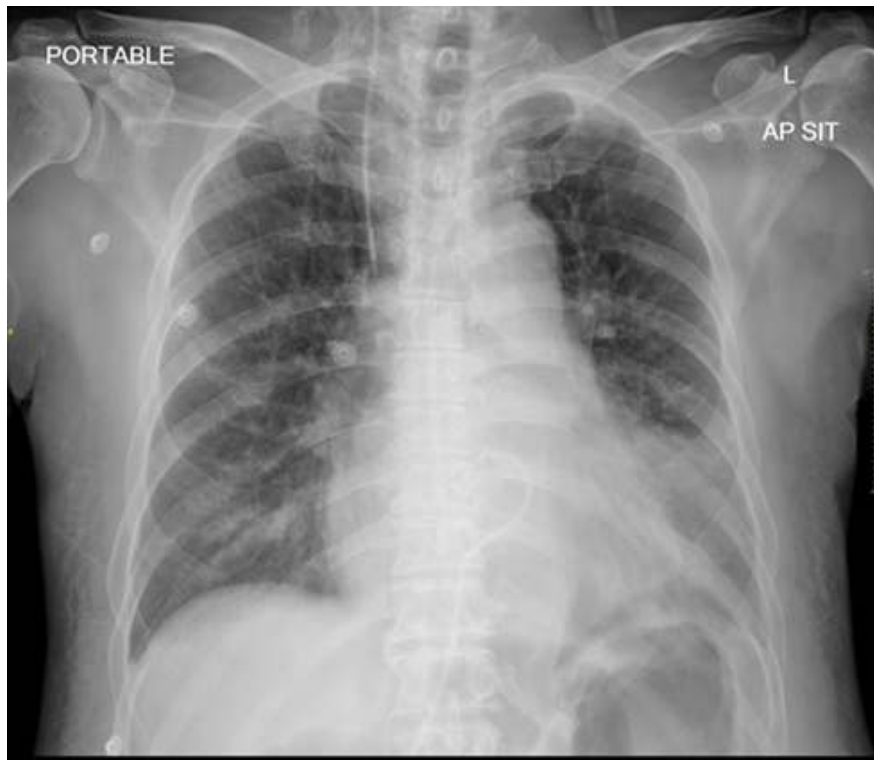


Figure 8.



## References

1. Ahmed A, Harsha TS, Hamza T, Allen A, Mohamed E. Cardiac Tamponade Masquerading as Gastritis: A Case Report. *J Med Case Rep* 2014;8:264.
2. Spodick DH. Acute cardiac tamponade. *N Engl J Med* 2003;349:684-90.
3. Refaat MM, Katz WE. Neoplastic Pericardial Effusion. *Clin Cardiol* 2011;34:593-8.
4. Gornik HL, Gerhard-Herman M, Beckman JA. Abnormal cytology predicts poor prognosis in cancer patients with pericardial effusion. *J Clin Oncol* 2005;23:5211-6.
5. Wilkes JD, Fidias P, Vaickus L. Malignancy related pericardial effusion. 127 cases from the roswell park cancer institute. *Cancer* 1995;76:1377-87.
6. LeWinter MM, Tischler MD. Pericardial Diseases. In: Bonow RO, Mann D, Zipes D, Libby P, editors. *Braunwald's Heart Disease*. 9th ed. Philadelphia (PA): Saunders; 2011. P. 1651-70.
7. Weekes AJ, Quirke DP. Emergency echocardiography. *Emerg Med Clin North Am* 2011;29:759-87.
8. Perera P, Lobo V, Williams SR, Gharahbaghian L. Cardiac echocardiography. *Crit Care Clin* 2014;30:47-92.