

The successful treatment of severe aspiration pneumonitis with the combination of hydrocortisone, ascorbic acid, and thiamine

Margot M. Gurganus, Paul E. Marik, Joseph Varon

Abstract

Aspiration pneumonitis is a neutrophil mediated inflammatory pneumonitis following the aspiration of regurgitated gastric contents. This syndrome occurs most commonly in patients with depressed levels of consciousness such as drug overdose, seizures, and during anesthesia. Aspiration pneumonitis is the most common cause of anesthesia-related deaths. Aspiration pneumonitis may be clinically silent or present

as severe acute lung injury (ARDS) progressing to death. The treatment of acid aspiration pneumonitis is largely supportive. We present two cases of severe life threatening ARDS due to acid aspiration who were treated with the combination of hydrocortisone, ascorbic acid, and thiamine (HAT) and made a dramatic recovery. This treatment strategy should be considered in the management of patients with aspiration pneumonitis.

Key words: Aspiration pneumonitis, gastric aspiration, ARDS, hydrocortisone, vitamin C, ascorbic acid, thiamine.

Aspiration pneumonitis is best defined as acute lung injury following the aspiration of regurgitated gastric contents. (1) This syndrome occurs in patients with a marked disturbance of consciousness such as drug overdose, seizures, coma due to acute neurological insults, massive cerebrovascular accident, following head trauma, and during anesthesia. Historically the syndrome most commonly associated with aspiration pneumonitis is Mendelson's syndrome, reported in 1946 in obstetric patients who aspirated while receiving general anesthesia. (2) The risk of aspiration with modern anes-

thesia is about 1 in 3000 anesthetics with a mortality of approximately 1:125,000 and accounting for between 10 to 30% of all anesthetic deaths. (3,4) The management of aspiration pneumonitis is essentially supportive. We present two cases of severe aspiration pneumonitis who were treated with the combination of hydrocortisone, ascorbic acid, and thiamine and demonstrated an apparent dramatic recovery.

Case 1

A 32-year-old female with a history of temporal lobe epilepsy presented to the Emergency Department (ED) of our hospital in a post-ictal state after experiencing a witnessed three-minute tonic-clonic seizure. The family reported that she likely aspirated on blood-tinged vomitus while seizing. In the ED the patient was noted to be somnolent but arousable; her oxygen saturation on supplemental oxygen was recorded as 80%. She was admitted to the Intensive Care Unit (ICU) where she required endotracheal intubation and mechanical ventilation using pressure-controlled ventilation (lung protective strategy) with a FiO₂ of 80% and a PEEP of 10 cmH₂O. Chest X-ray on admission to the ICU demonstrated diffuse bilateral patchy opacities (**Figure 1**). Chest CT scan showed diffuse patchy airspace disease involving all lobes. An echocardi-

From Department of Internal Medicine, Eastern Virginia Medical School, Norfolk, Virginia, USA (Margot M. Gurganus), Division of Pulmonary and Critical Care Medicine, Eastern Virginia Medical School, Norfolk, Virginia, USA (Paul E. Marik), Department of Critical Care, United General Hospital, Houston, Texas, USA (Joseph Varon).

Address for correspondence:

Paul E. Marik, MD
Chief, Division of Pulmonary and Critical Care Medicine
Eastern Virginia Medical School
825 Fairfax Ave, Suite 410, Norfolk VA, 23517, USA
Email: marikpe@evms.edu

ogram demonstrated normal systolic function, with an ejection fraction of 65% and no valvular abnormalities. The patient was diagnosed with aspiration pneumonitis. A transpulmonary thermodilution catheter was placed (PiCCO, Maquet, Rastatt, Germany), which demonstrated an initial extravascular lung water index (EVLWI) of 27 ml/kg (normal <10 ml/kg); a value that is associated with a mortality in excess of 65%. (5) Her blood and sputum cultures showed no growth at 48 hours. In addition to supportive care which included mechanical ventilation, antiepileptic medications and a 24-hour empiric course of ampicillin/sulbactam the patient was treated with the hydrocortisone, ascorbic acid, and thiamine (HAT) protocol. The HAT protocol consists of an intravenous infusion of ascorbic acid 1.5 g every 6 hours, intravenous hydrocortisone 50 mg every 6 hours, and intravenous thiamine 200 mg every 12 hours.

ICU course

Within 24 hours of ICU admission, the FiO₂ was reduced from 80% to 40% and the PEEP reduced to 8 cmH₂O; the EVLWI had fallen to 16 ml/kg. On hospital day 3, her FiO₂ setting was further decreased to 30% and she was subsequently extubated. At time of extubation, her CXR demonstrated almost complete disappearance of the pulmonary infiltrates (**Figure 1**) and the EVLWI has fallen to 10 ml/kg. She was transferred to the medical floor on hospital day 4 (at which time the HAT protocol was stopped) and she was discharged to home two days later.

Case 2

A 55-year-old male with a history of chronic atrial fibrillation, testicular cancer, gastroesophageal reflux, and morbid obesity (BMI=38.5 kg/m²) who had undergone a Roux-en-Y gastric bypass procedure in 2001, presented to the ED complaining of abdominal pain, nausea, and emesis. He had previously been admitted for bowel obstruction requiring lysis of adhesion. He was admitted by the General Surgery service after a CT scan showed adhesive small bowel obstruction with distension of the remnant stomach. The patient underwent a laparoscopic converted to open lysis of adhesions. His immediate post-operative course was complicated by rapid atrial fibrillation and poorly controlled pain. On post-operative day 12 he again developed abdominal pain with nausea/vomiting, with a CT scan again demonstrating significant distention of remnant stomach with associated bowel obstruction. A decompressive gastrotomy was performed under general anesthesia. Upon induction of anes-

thesia he vomited with aspiration of gastric pouch contents. Soon after the procedure he became profoundly hypoxic requiring intubation and mechanical ventilation. He was transferred to the ICU where he was paralyzed and sedated, required pressure-controlled ventilation with a FiO₂ of 75% and a PEEP of 16 cmH₂O and vasopressor support with norepinephrine. Chest X-ray on admission to the ICU demonstrated a left lung infiltrate compatible with aspiration pneumonitis (**Figure 2**). Broad spectrum antibiotics were initiated, and the patient was started on the HAT protocol. Bedside bronchoscopy was performed with the aspiration of particulate gastric contents. An echocardiogram showed normal left ventricular systolic function, with an ejection fraction of 60%.

ICU course

Within 24 hours of admission to the ICU the FiO₂ had been reduced to 60% and the paralytic agent was stopped. A PiCCO catheter was placed at this time, which demonstrated an EVLWI of 13 ml/kg. By ICU day 3, the FiO₂ had been further reduced to 40%, with a PEEP of 12 cmH₂O and an EVLWI of 8 cmH₂O with clearing of the pulmonary infiltrate on chest radiograph (**Figure 2**). The vasopressor agents were weaned off at this time. He was extubated on ICU day 4 and was transferred out of the ICU in stable condition shortly thereafter and discharged to a Skilled Nursing Facility.

Discussion

It is important to distinguish between “aspiration pneumonia,” which is a bacterial pneumonia caused by the aspiration of colonized oropharyngeal secretions most commonly seen in elderly patients and those with neurologic disorders, and “aspiration pneumonitis,” caused by the aspiration of regurgitated gastric contents causing a chemical pneumonitis. (1) The administration of antibiotics is central to the management of aspiration pneumonia while the treatment of aspiration pneumonitis is largely supportive. (1) Aspiration of gastric contents can present dramatically with features that include shortness of breath, cough, wheezing, and hypoxemia and which may progress rapidly to severe acute respiratory distress syndrome (ARDS) and death. However, in some patients aspiration may be clinically silent or present with a mild cough or wheeze. (6)

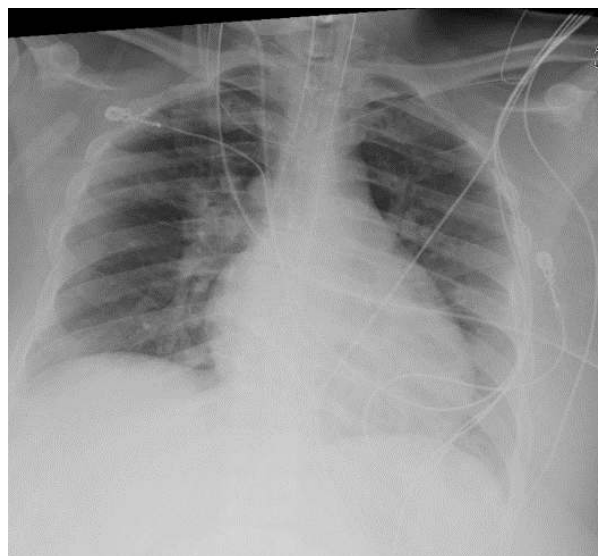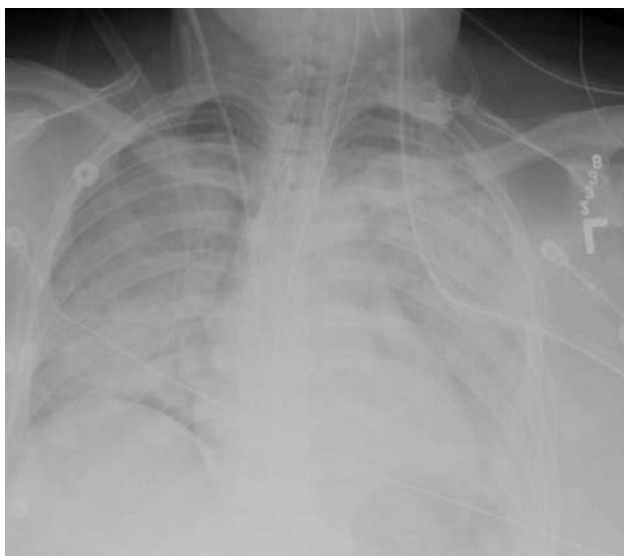As highlighted by Mendelson, aspiration pneumonitis is a chemical pneumonitis caused by the aspiration of acid gastric contents. (2) Experimental studies have demonstrated that the severity of lung injury increases significantly with the volume of the

aspirate and indirectly with its pH. (7) Aspiration of gastric contents results in a chemical burn of the tracheobronchial tree and pulmonary parenchyma with an intense parenchymal inflammatory reaction. In experimental models, when acid is instilled into the lungs a two-phase injury results. The initial injury phase (within 1 h of acid exposure) is primarily due to the acid's direct caustic effects on pulmonary tissue, whereas the second injury phase (beginning at 3 to 4 h and peaking at 4-6 h postexposure) results from recruited neutrophils. (8,9) The intensity of the alveolar neutrophil infiltration is related to the severity of the acute lung injury. Once localized to the lung, neutrophils play a key role in the development of lung injury through the release of reactive oxygen species (ROS) and proteases that are injurious to the lung. Nicotinamide adenine dinucleotide phosphate hydrogen (NADPH) oxidase is the major source of ROS in activated polymorphonuclear leukocytes (PMNs); other sources of ROS following gastric aspiration include superoxide anion generated by xanthine oxidase. (10) ROS exacerbate acute lung injury through several mechanisms, including direct cellular injury, nuclear factor- κ B (NF- κ B) activation and activation of other pro-inflammatory mediators such as tumor-necrosis factor- α (TNF- α) and interleukin-8 (IL-8). The activation of NADPH oxidase in neutrophils is linked to the generation of neutrophil extracellular traps (NETs). NETs are extracellular strands of decondensed (unwound) deoxyribonucleic acid (DNA) in complex with histones and neutrophil granule proteins. NETs contain serine proteases and other antimicrobial products that damage the lung. Juss et al demonstrated that neutrophils from patients with ARDS are hypersegmented, with delayed apoptosis but enhanced oxi-

native burst, phagocytosis, and NET responses. (11) Gastric acid prevents the growth of bacteria and therefore the contents of the stomach is normally sterile. Bacterial infection, therefore, does not play a significant role in the early stages of acute lung injury following aspiration of gastric contents.

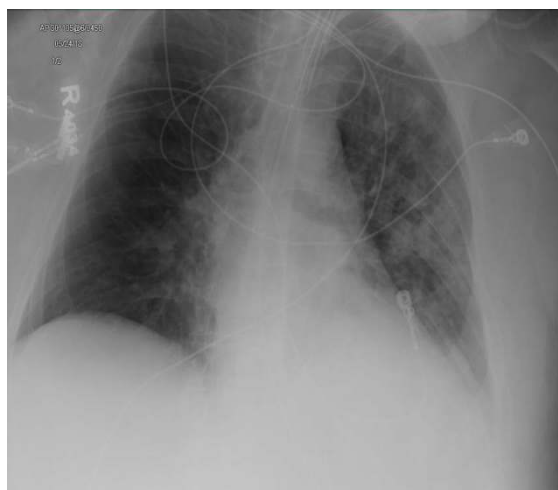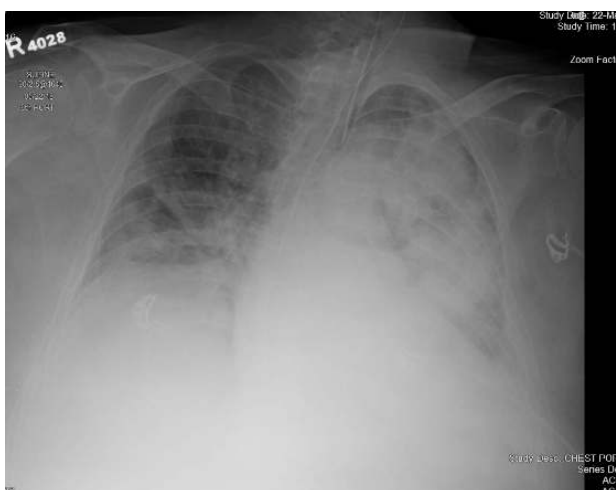
Corticosteroids are potent anti-inflammatory which act largely by repression of the transcriptional activity of NF- κ B. Glucocorticoids have been used in the management of aspiration pneumonitis since 1955, (12-14) however, their role as mono-therapy appears limited possibly due to their limited effect on neutrophils and ROS. Vitamin C, acting synergistically with low-dose corticosteroids and thiamine, has emerged as an important strategy in treating various conditions characterized by widespread and profound inflammation. (15) Vitamin C is a potent antioxidant and inhibitor of NADPH oxidase and would likely reduce the severity of acute lung injury after acid aspiration. (16) In addition, vitamin C inhibits NETosis. (17) In a murine model, Fisher et al demonstrated that vitamin C attenuated lipopolysaccharide-induced acute lung injury. (18) We present two patients with very severe ARDS who were treated with a protocol of hydrocortisone, ascorbic acid, and thiamine who appeared to respond dramatically to this intervention. While prospective randomized control trials are currently underway to explore the potential benefits of this treatment strategy in the management of sepsis and ARDS, we suggest that this simple, readily available, and cheap intervention be considered in patients with acid aspiration-induced acute lung injury. It should be noted that this intervention is extremely safe and devoid of any known complications or side effects. (15,19)

Figure 1. Case 1. Portable postero-anterior (PA) chest radiograph on admission to the ICU and 48 hours later.



Legend: ICU=intensive care unit.

Figure 2. Case 2. PA chest radiograph on admission to the ICU and 48 hours later.



Legend: PA=postero-anterior; ICU=intensive care unit.

References

1. Marik PE. Aspiration Pneumonitis and Aspiration Pneumonia. *N Engl J Med* 2001; 344:665-71.
2. Mendelson CL. The aspiration of stomach contents into the lungs during obstetric anesthesia. *Am J Obstet Gynecol* 1946;52:191-205.
3. Cook TM, Woodall N, Frerk C; Fourth National Audit Project. Major complications of airway management in the UK: results of the Fourth National Audit Project of the Royal College of Anaesthetists and the Difficult Airway Society. Part 1: anaesthesia. *Br J Anaesth* 2011;106:617-31.
4. Beck-Schimmer B, Bonvini JM. Bronchoaspiration: incidence, consequences and management. *Eur J Anaesthesiol* 2011;28:78-84.
5. Zhang Z, Ni H. Effectiveness of treatment based on transpulmonary thermodilution in critically ill patients: response to comments by Sanchez et al. *Intensive Care Med* 2015;41: 1156.
6. Warner MA, Warner ME, Weber JG. Clinical significance of pulmonary aspiration during the perioperative period. *Anesthesiol* 1993;78: 56-62.
7. Knight PR, Davidson BA, Nader ND, Helinski JD, Marschke CJ, Russo TA, et al. Progressive, severe lung injury secondary to the interaction of insults in gastric aspiration. *Exp Lung Res* 2004;30:535-57.
8. Knight PR, Druskovich G, Tait AR, Johnson KJ. The role of neutrophils, oxidants, and proteases in the pathogenesis of acid pulmonary injury. *Anesthesiology* 1992;77: 772-8.
9. Kennedy TP, Johnson KJ, Kunkel RG, Ward PA, Knight PR, Finch JS. Acute acid aspiration lung injury in the rat: biphasic pathogenesis. *Anesth Analg* 1989;69:87-92.
10. Lee WL, Downey GP. Neutrophil activation and acute lung injury. *Curr Opin Crit Care* 2001;7:1-7.
11. Juss JK, House D, Amour A, Begg M, Herre J, Storisteanu DM, et al. Acute Respiratory Distress Syndrome Neutrophils Have a Distinct Phenotype and Are Resistant to Phosphoinositide 3-Kinase Inhibition. *Am J Respir Crit Care Med* 2016;194:961-73.
12. Haussmann W, Lunt RL. The problem of the treatment of peptic aspiration pneumonia following obstetric anesthesia (Mendelson's syndrome). *J Obstet Gynaecol Br Emp* 1955;62:509-12.
13. Wolfe JE, Bone RC, Ruth WE. Effects of corticosteroids in the treatment of patients with gastric aspiration. *Am J Med* 1977;63:719-22.
14. Sukumaran M, Granada MJ, Berger HW, Lee M, Reilly TA. Evaluation of corticosteroid treatment in aspiration of gastric contents: A controlled clinical trial. *Mt Sinai J Med* 1980;47:335-40.
15. Marik PE, Khangoora V, Rivera R, Hooper MH, Catravas J. Hydrocortisone, Vitamin C and Thiamine for the treatment of severe sepsis and septic shock: A retrospective before-after study. *Chest* 2017;151:1229-38.
16. May JM, Harrison FE. Role of vitamin C in the function of the vascular endothelium. *Antioxid Redox Signal* 2013;19:2068-83.
17. Mohammed BM, Fisher BJ, Kraskauskas D, Farkas D, Brophy DF, Fowler AA 3rd, et al. Vitamin C: a novel regulator of neutrophil extracellular trap formation. *Nutrients* 2013;5:3131-51.
18. Fisher BJ, Seropian IM, Kraskauskas D, Thakkar JN, Voelkel NF, Fowler AA 3rd, et al. Ascorbic acid attenuates lipopolysaccharide-induced acute lung injury. *Crit Care Med* 2011;39:1454-60.
19. Marik PE. Vitamin C for the treatment of sepsis: The scientific rationale. *Pharmacol Ther* 2018;189:63-70.