

Post-surgical right coronary artery injury secondary to tricuspid valve repair

Andrés Parisi, Ying Tung Sia

Abstract

Injury to the right coronary artery (RCA) is a rare complication of tricuspid annuloplasty. We report a 64-year-old woman with history of valvular heart disease that was admitted for decompensated right heart failure. The patient underwent aortic valve replacement and tricuspid annuloplasty. Shortly after tricuspid annuloplasty the patient developed right ventricular

(RV) infarction with hemodynamic compromise. The coronary angiogram shows subtotal occlusion at the mid segment of right coronary artery probably due to stitch of the tricuspid ring. The RCA has successfully been revascularized by percutaneous coronary angioplasty with bare metal stent, however the patient got into multi-organs failure syndrome and died at day 15 postoperatively.

Key words: Iatrogenic right coronary injury, right ventricular infarction, tricuspid valve repair, cardiogenic shock.

Introduction

The number of tricuspid interventions has greatly increased during the last several years, usually being performed in the context of other cardiac operations. (1) Surgical technique has greatly evolved, with great acceptance of valve repair, which nowadays is the technique of choice. (2,3) The two most widely used repair techniques are the DeVega purse-string repair (suture technique) and ring or band annuloplasty. (4) Few complications have been reported related to these techniques, especially for tricuspid ring annuloplasty. (5)

The right coronary artery (RCA) courses in the atrioventricular groove toward the crux of the heart

and is closest in continuity with the tricuspid valve (TV) along the posterior tricuspid annulus. (6) Injury to the artery can occur in this segment either directly from suturing around the artery or indirectly from tension placed on the adjacent atrial tissue. (7)

Both cardiogenic shock and electrical instability may complicate the course of patients undergoing reparative surgery of the TV. Direct injury to the RCA is a rare complication, probably underdiagnosed, which often entails dramatic clinical consequences. (4)

We present a case of biventricular failure after tricuspid annuloplasty due to ligation of the RCA.

Case

A 64-year-old woman with a history of severe chronic obstructive pulmonary disease (COPD) was admitted for decompensated right heart failure. An echocardiogram showed dilated right ventricle with mild dysfunction, severe aortic valve stenosis, and severe tricuspid regurgitation with a dilated annulus. The left ventricular function was normal and moderated pulmonary hypertension was found. At admission she was in atrial fibrillation and in New York Heart Association (NYHA) class III. A preoperative coronary angiography revealed RCA dominance without coronary artery disease. The patient was then scheduled for aortic

From Department of Cardiac Surgery, Montreal Heart Institute, Université de Montréal, Montreal, Quebec, Canada (Andrés Parisi) and Department of Medicine, Service of Cardiology, CIUSSS-MCQ, Université de Montréal, Trois-Rivières, Québec, Canada (Ying Tung Sia).

Address for correspondence:

Ying Tung Sia, MD, MSc
1991, boulevard du Carmel, Trois-Rivières, QC, Canada G8Z 3R9
Tel: 819-697-3333 #63385
Email: yts25@hotmail.com

valve replacement and a tricuspid valve repair with annuloplasty ring.

A bioprosthetic aortic valve replacement with a sutureless bioprosthesis, Perceval medium (LivaNova Group, Milan, Italy) and a Physio annuloplasty tricuspid ring of 28 mm (Edwards Lifesciences, Irvine, CA) were implanted. The patient was easily weaned from cardiopulmonary bypass. Intraoperative echocardiography showed a well-functioning aortic prosthesis and a competent tricuspid valve. Systolic function seemed to be preserved in both ventricles. The patient was transferred to the acute postoperative care unit with low vasoactive drug support.

The first post-operative electrocardiography (ECG) showed no ST segment abnormalities. Several hours later, the course has been complicated by several episodes of sustained ventricular tachycardia requiring cardiac defibrillation. Repeat ECG indicated significant changes that were compatible with ST elevation myocardial infarction (STEMI) in inferior leads. An urgent echocardiogram revealed normal function of valvular prosthesis but severe biventricular dysfunction. An urgent coronary angiography was performed and showed critical stenosis in the mid portion of RCA (**Figure 1, Video 1**), which was successfully revascularized with the implantation of a bare metal stent. Despite the RCA revascularization, the patient remained in shock. The course was complicated by septic shock, acute renal failure and bowel ischemia. The patient finally died on day 15 after surgery.

Discussion

Iatrogenic injury to the RCA is a rare complication of tricuspid valve surgery and should be considered in the case of hemodynamic instability, ven-

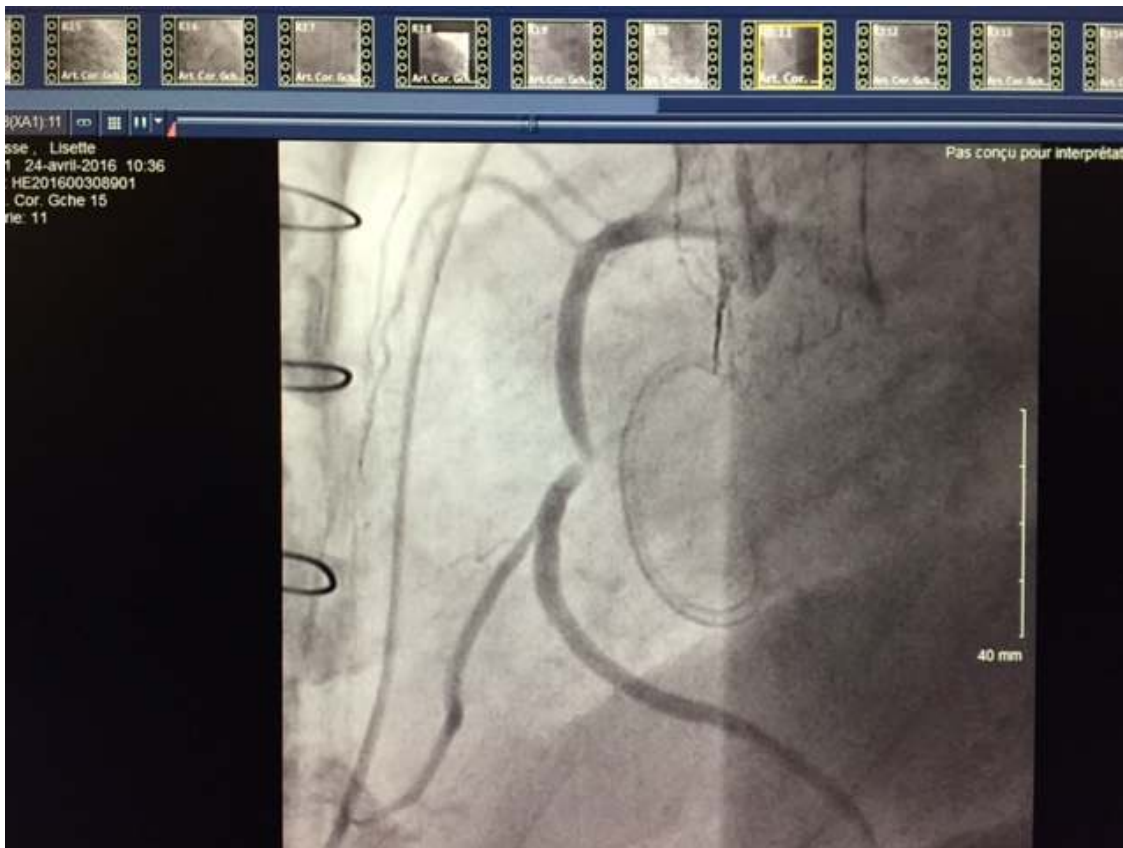
tricular tachycardia or unexplained de novo cardiac dysfunction after surgery. (7) Profound cardiogenic shock, ventricular tachycardia, inferior ischemia and acute postoperative right ventricular dysfunction are frequent clinical manifestations in the course of this event. (4)

At the best of knowledge, there are only 10 cases reported in the literature. Most of them involved DeVega purse-string tricuspid valve repair. (4-8) Direct arterial injury with the sutures applied for tricuspid ring fixation or RCA kinking caused by annulus plication are the two main mechanisms that can lead to this event. (5) This complication is especially possible in the presence of anatomic variations of RCA distribution or whenever relationship between the RCA and the tricuspid annulus is altered due to right ventricle remodeling or severe tricuspid annulus dilatation. (8) The distance between the RCA and the endocardium is particularly small in the segment delimited by the right marginal artery and the crux, especially in the cavotricuspid isthmus in the lower right atrium, with a distance of less than 5 mm in over 80% of patients. (9)

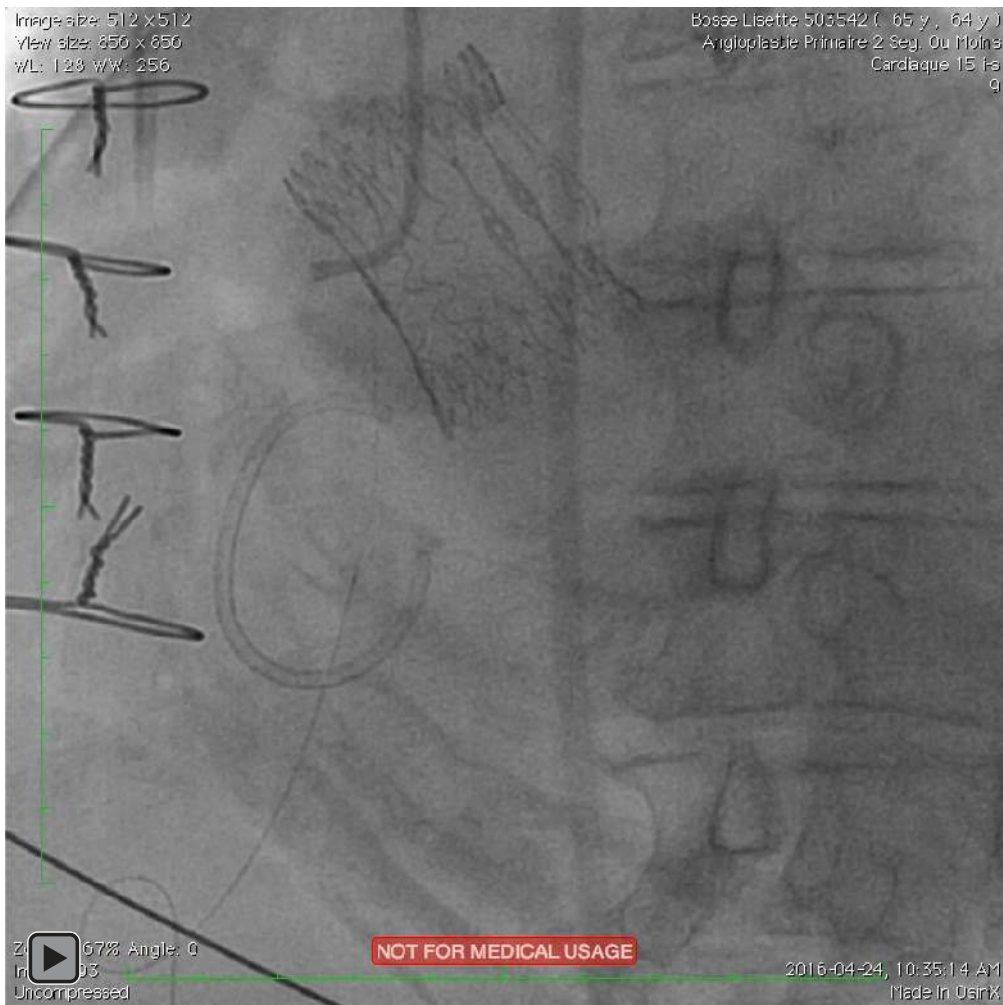
Risk of RCA occlusion may be minimized by using semirigid rings, applying fewer sutures along the posterior annulus, and limiting the depth of suture travel to avoid traction on the atrial tissue. (4,8,10)

Prompt recognition has crucial importance and an emergent management is mandatory to assure patient survival. (4) Revascularization of the RCA can be accomplished through either release of the suture, bypass grafting of the artery or percutaneous coronary intervention (PCI). (11,12) In urgent situation, PCI is considered the best option for revascularization.

Figure 1. Still frame of sutured right coronary post tricuspid annuloplasty ring



Video 1. Cine of coronary angiogram showing RCA suture at the mid portion after tricuspid annuloplasty ring



References

1. Vassileva CM, Shabosky J, Boley T, Markwell S, Hazelrigg S. Tricuspid valve surgery: the past 10 years from the Nationwide Inpatient Sample (NIS) database. *J Thorac Cardiovasc Surg* 2012;143:1043-9.
2. Vahanian A, Alfieri O, Andreotti F, Antunes MJ, Barón-Esquivias G, Baumgartner H, et al. Guidelines on the management of valvular heart disease (version 2012): the Joint Task Force on the Management of Valvular Heart Disease of the European Society of Cardiology (ESC) and the European Association for Cardio-Thoracic Surgery (EACTS). *Eur J Cardiothorac Surg* 2012;42:S1-44.
3. Irwin RB, Luckie M, Khattar RS. Tricuspid regurgitation: contemporary management of a neglected valvular lesion. *Postgrad Med J* 2010;86:648-55.
4. Diez-Villanueva P, Gutiérrez-Ibañes E, Cuerpo-Caballero GP, Sanz-Ruiz R, Abeytua M, Soriano J, et al. Direct injury to right coronary artery in patients undergoing tricuspid annuloplasty. *Ann Thorac Surg* 2014;97:1300-5.
5. Gonzalez-Santos JM, Arnáiz-García ME, Sastre-Rincón JA, Bueno-Codoñer ME, Dalmau-Sorlí MJ, Arévalo-Abascal A, et al. Acute Right Coronary Artery Occlusion After Tricuspid Valve Ring Annuloplasty. *Ann Thorac Surg* 2015;99:2213-6.
6. Calafiore AM, Iacò AL, Bartoloni G, Di Mauro M. Right coronary occlusion during tricuspid band annuloplasty. *J Thorac Cardiovasc Surg* 2009;138:1443-4.
7. Morrissy SJ, Atkins BZ, Rogers JH. Iatrogenic right coronary artery stenosis resulting from surgical tricuspid valve replacement: case report and review of the literature. *Catheter Cardiovasc Interv* 2014;84:1110-4.
8. Varghese R, Akujuo A, Adams DH. Right coronary artery injury after tricuspid valve repair. *Semin Thorac Cardiovasc Surg* 2010;22:189-90.
9. Al Aloul B, Sigurdsson G, Can I, Li JM, Dykoski R, Tholakanahalli VN. Proximity of right coronary artery to cavotricuspid isthmus as determined by computed tomography. *Pacing Clin Electrophysiol* 2010;33:1319-23.
10. Miura Y, Takeuchi R, Terai Y, Nakai M, Yamazaki F, Onodera T, et al. Right ventricular infarction caused by tricuspid ring annuloplasty. *Gen Thorac Cardiovasc Surg* 2017;65:463-5.
11. Santavy P, Simek M, Troubil M, Lonsky V. Right coronary artery obstruction by tricuspid annuloplasty ring. *Eur J Cardiothorac Surg* 2011;39:416.
12. Patel N, Cuculi F, Banning AP. Two rings too tight: sequential emergency PCI for hemodynamic and arrhythmic complications of mitral and tricuspid valve repair. *Catheter Cardiovasc Interv* 2014;83:E73-6.